BMC Oral Health

RESEARCH

Open Access

Accuracy of laser fluorescence in assessment of various caries removal techniques: an in vitro validation

Özlem Kanar[1*], Dilek Tağtekin[1], Bora Korkut[1], Funda Yanıkoğlu[2] and Betül Kargül[3,4]

Abstract

Background This study aimed to evaluate the accuracy of laser fluorescence (LF) readings in detection of caries removal by various techniques (CRTs).

Methods A hundred and eighty extracted human molar teeth included in the study which were scored 3, 4, and 5 according to ICDAS. Each score group was randomly assigned to 4 subgroups according to CRT including ceramic bur (Group A), carbide bur (Group B), carbide bur with alumina abrasion (Group C), and carbide bur with bioactive glass (BAG) abrasion (Group D) ($n=15$ for each group). A LF device (DIAGNOdent Pen, Kavo) was used to determine remaining caries. Histological sections of the teeth were examined under a dental operating microscope for validation. The data were analyzed using Fisher Freeman Halton, Fisher's Exact, Pearson Chi-Square, Bonferroni Adjusted Z tests, ROC analysis, Kappa statistic and Binary Logistic Regression($p<0.05$).

Results Histological examination revealed no significant differences among the CRTs and ICDAS scores ($p>0.05$ for each). However, a significant difference was found between histological assessment and LF in ICDAS 5 score, specifically between Group B and Group D ($p=0.022$), regarding caries presence. LF readings demonstrated over 0.9 area under curve (AUC) value regardless of CRT, except for ICDAS-4 score, and Group D in ICDAS-5 score. Overall, the AUC of LF was found to be 0.880 for the 38 cut-off point ($p<0.001$), indicating a high level of accuracy. The univariate and multiple models showed the tested CRTs had no effect on the caries presence ($p>0.050$).

Conclusions The CRTs examined in this study demonstrated similar efficacy in terms of caries removal. However, the application of bioactive glass on caries-affected dentin may lead to overestimations in the LF readings. Additionally, LF on the cavity floor may not be clinically suitable for teeth with ICDAS 4 scores.

Clinical relevance The clinical determination of caries removal endpoint is based on a multifactorial decision. However, when selective removal of soft dentin is performed, especially with bioactive glass abrasion in deep caries lesions, higher cut-off points might be determined in laser fluorescence readings to decide further operative intervention.

Keywords Air abrasion, Aluminum oxide, Bioactive glass, Caries-affected dentin, Caries removal, Ceramic bur, ICDAS, Laser fluorescence, Tungsten carbide

*Correspondence:
Özlem Kanar
ozlem.kanar@marmara.edu.tr

Full list of author information is available at the end of the article

© The Author(s) 2024. **Open Access** This article is licensed under a Creative Commons Attribution-NonCommercial-NoDerivatives 4.0 International License, which permits any non-commercial use, sharing, distribution and reproduction in any medium or format, as long as you give appropriate credit to the original author(s) and the source, provide a link to the Creative Commons licence, and indicate if you modified the licensed material. You do not have permission under this licence to share adapted material derived from this article or parts of it. The images or other third party material in this article are included in the article's Creative Commons licence, unless indicated otherwise in a credit line to the material. If material is not included in the article's Creative Commons licence and your intended use is not permitted by statutory regulation or exceeds the permitted use, you will need to obtain permission directly from the copyright holder. To view a copy of this licence, visit http://creativecommons.org/licenses/by-nc-nd/4.0/.

Introduction

The current approach in managing caries includes non-invasive methods and prioritizes preserving as much tooth structure as possible. Distinguishing between the extensively infected outer carious dentin and the demineralized affected inner dentin minimizes the risk of pulp exposure and enhances the tooth's ability to repair itself. Various layers of carious dentin lesions have been categorized using both clinical [1, 2] and laboratory techniques [3], though recommendations are diverse, some compatible and some contradictory.

The question of the endpoint of caries removal has been the goal of much research and focus of clinical routine. To this end, minimally invasive caries removal techniques have been developed. These methods aim to remove the infected dentin tissue and preserve the underneath, remineralizable caries-affected dentin. However, in clinical practice, it may not always be possible to distinguish between tissues that should be "preserved" or "removed".

Some authors have suggested the use of laser fluorescence readings in combination with caries detection dyes to assess residual dentin [4]. DIAGNOdent Pen (Kavo, Germany) with 655 nm red laser light was introduced for caries diagnosis. The system provides a real-time assessment of the fluorescence level based on bacterial porphyrins. As a result of diagnostic accuracy studies, cut-off points (COP) have been defined to indicate the level of caries lesion in LF readings [5]. Some studies have suggested that LF readings of 30 should be considered the limit for operative intervention in dentinal caries [6–8]. The accuracy of LF in assessing the remaining dentin is around 0.80 [9]. However, some authors have stated that LF readings are related to the color parameters of the remaining dentin and should not be a guide to the endpoint of caries removal [10]. Additionally, since LF readings are related to the cavity depth, a higher cut-off value should be determined for deep carious lesions [11].

Alternative bur systems with relatively lower cutting efficacy have been developed to provide less invasive caries removal. Dammaschke et al. [12]. determined that the efficacy of ceramic burs in caries removal is comparable to that of tungsten carbide burs. Self-limiting polymer burs are also available for the selective removal of caries. Shivasharan et al. [13]. reported similar caries removal efficiency for chemomechanical caries removal agent (Carie-carie) and self-limiting polymer bur in primary dentition. However, despite their minimally invasive potential, the abrasion of these burs when encountering intact dentin makes them disposable. The length of the operation time is another disadvantage of using these burs compared to conventional stainless steel burs [14].

Aluminum oxide particles were the main particles proposed for caries removal by air abrasion [15]. The irregularly shaped aluminum oxide particles can also improve bond strength by forming irregular surfaces on the remaining dentin [16]. Bioactive glass (BAG) has been proposed for use in remineralization as it has the unique ability to release essential ions such as calcium, phosphate, and fluoride [17]. Delivery of BAG (in combination with polyacrylic acid) via air abrasion promoted dentin remineralization and improved the bond strength of resin-modified glass ionomers to dentin [18]. Bioactive glass comes in various compositions, with the prominent variant being 45S5 Bioglass, comprised of silicon dioxide (SiO_2): 45%, sodium oxide (Na_2O): 24.5%, calcium oxide (CaO): 24.5%, and phosphorus pentoxide (P_2O_5): 6% [19]. However, there are limited studies in the literature on the effects of BAG abrasion applied to demineralized teeth [20, 21]. Some authors claim a therapeutic effect for BAG-containing adhesives for caries-affected dentin, and reduced nanoleakage [22]. The authors are unaware of any studies assessing the effectiveness of BAG particles in caries removal. Moreover, it is not known whether BAG applied to the dentin surface has an effect on LF readings from the cavity floor. Exposure to hypochlorite [23], and tetracycline antibiotics [24, 25] with strong calcium binding abilities (such as demeclocycline hydrochloride) have been reported to cause false positive LF readings in sound dentin surfaces. Bioactive glasses are known for their occluding effect on dentinal tubules [21]. Accordingly, there may be a concern that the changes in bioactive glasses application to caries-affected dentin will affect LF readings.

This study aimed to investigate the efficacy of different caries removal techniques in different levels of caries lesions. Another purpose was the evaluation of the residual dentin after caries removal by various techniques using LF by DIAGNOdent Pen.

The null hypotheses were: (1) Tested caries removal methods have similar efficacy (2) LF readings and histologic evaluation provide similar results for the diagnosis of residual dentin after various caries removal techniques.

Materials and methods

This research was conducted by following STARCARDDS criteria [26]. Study protocol approved by the local ethics committee on the date 08.12.2023 (Protocol number: 09.2023.1699).

Human permanent molars extracted for various reasons in the last six months (decay, periodontal disease, etc.) were cleaned with an ultrasonic cleaner and pumice stone. All the surfaces of the crown were examined visually and tactilely by a blunt explorer under 5500 K illumination. They were then classified according to the International Caries Detection and Assessment System (ICDAS II). Study workflow summerized in Fig. 1.

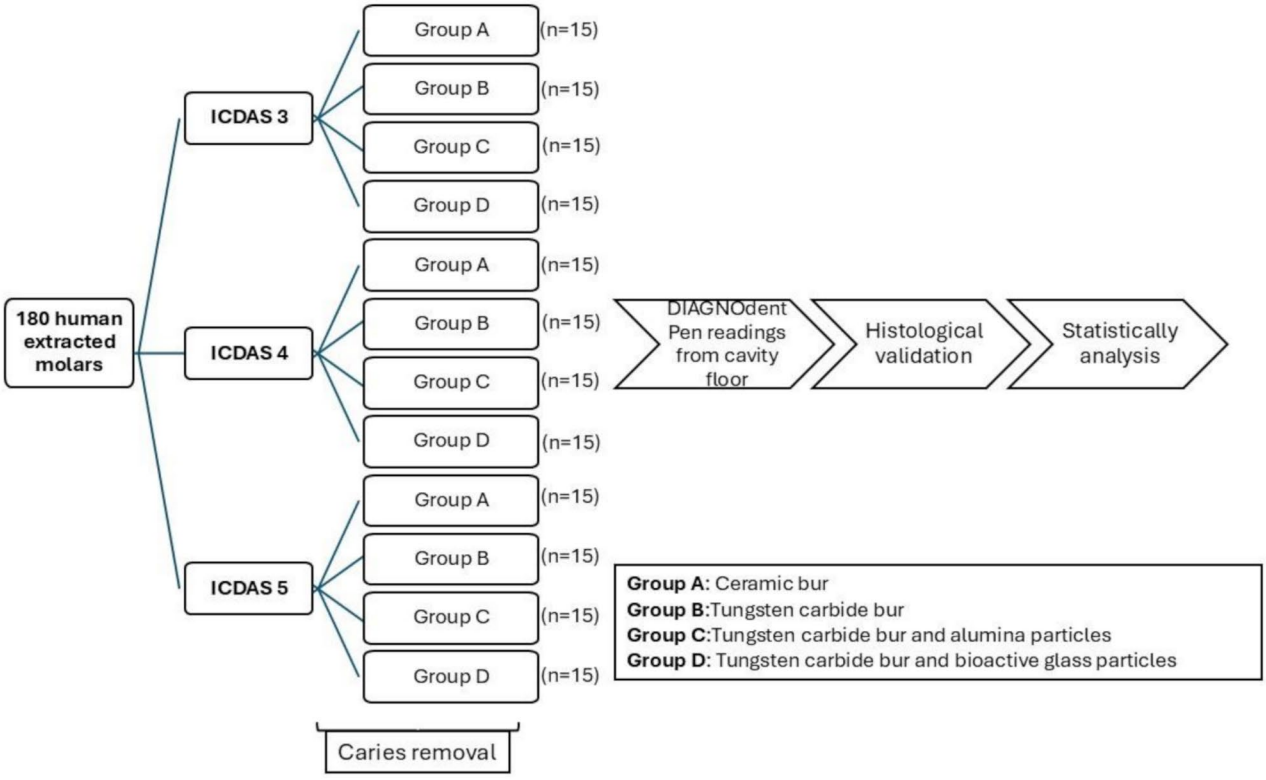

Fig. 1 Flowchart of the study

Inclusion criteria

- Upper or lower permanent molars.
- Occlusal caries lesions requiring operative intervention (validated by LF readings) with ICDAS scores of 3, 4, and 5 were included in the study ($N = 180$).

Exclusion criteria

The exclusion criteria were:

- Sound, cracked, and worn teeth.
- Teeth with restorations.
- Pulp involvement and periapical pathology.
- Development anomalies and disturbances.
- Flat surface caries.
- Presence of tubercule loss.
- Scored as 1, 2, or 6 according to the ICDAS.

Each ICDAS score group was divided into subgroups according to caries removal technique ($n=15$). Four groups were randomly assigned by using the www.randomizer.org. A co-researcher managed the allocation and reported the selected CRT to the operator.

- Group A: Ceramic bur (Komet-Brasseler, Lemgo, Germany).
- Group B: Tungsten carbide bur (Frank Dental Gmbh, Germany).
- Group C: Tungsten carbide bur and air abrasion (29 µm Aluminium oxide particles, Velopex, UK).
- Group D: Tungsten carbide bur and air abrasion (Bioactive glass particles, Sylc, Velopex, UK).

Calibration

The operator was trained by a senior co-researcher (who has 34 years of experience in operative dentistry) before all procedures. Operator was calibrated on 30 teeth before starting the study. Intraexaminer reliability for the operator was calculated ($\kappa=0.88$ for the assessment of remaining dentin, $\kappa=0.92$ for histological examination). The operator and co-researcher showed a high inter-examiner agreement ($\kappa=0.96$ for remaining dentin, $\kappa=0.98$ for histological evaluation) as a result of this training.

All experiments of this in vitro study were conducted by the main researcher (Ö.K). The operator made all the ICDAS scoring, caries removal procedure, LF readings, and histological examination. The examiner has eight years of professional experience in restorative dental treatment. The researchers who designed this study had previously conducted projects and doctoral theses on caries diagnosis and removal techniques.

Caries removal procedure

In all groups, enamel caries were removed with a coarse-grit diamond bur (Frank Dental, Tegernse, Germany) to reach the dentinal caries lesion.

- In Group A, a ceramic bur was selected, ranging from the size of #16 to #21, depending on the width of the dentinal caries. Carious dentin was removed from the periphery to the center by ceramic bur using a slow-speed micromotor. The end point of caries removal was the removal of infected dentin up to the cutting ability of the bur ($N=45$).
- In Group B, tungsten carbide bur was used from the size of #16 to #21 depending on the width of the dentinal caries. Carious tissue was removed from the periphery to the center by tungsten carbide bur at a slow- speed. Caries removal endpoint was the hard sensing with a ball-ended probe at the cavity floor ($N=45$).
- In Group C, the soft dentin was partially removed from the periphery to the center by a tungsten carbide bur (#16 to #21). Then, under a pressure of 0.4 MPa, 29 µm Aluminum oxide particles were delivered at a distance of 1 mm at a 45–90 degree angle to the dentin surface. Caries removal endpoint was the selective removal to soft dentine with tungsten carbide bur, and selective removal of underneath dentin via abrasion (alumina particles), until a smooth surface by ball-ended probe ($N=45$).
- In Group D, the soft dentin was partially removed from the periphery to the center by a tungsten carbide bur (#16 to #21). Then, under a pressure of 0.4 MPa, BAG particles (Sylcc, Aquacare, Velopex UK) were delivered at a distance of 1 mm at a 45–90 degree angle to the dentin surface ($N=45$). Caries removal endpoint was the selective removal to soft dentine with tungsten carbide bur, and selective removal of underneath dentin via abrasion (BAG particles), until a smooth surface by ball-ended probe ($N=45$).

To ensure standardization, the bur was replaced with a new one in every five teeth [27]. During caries removal, a minimally invasive approach was adopted regardless of the caries removal technique. In determining the end point of caries removal, the recommendation of Schwendike et al. in permanent teeth was taken into consideration: selective removal to soft dentin in deep lesions, and selective removal to firm dentin in shallow/moderate lesions [28]. Another common point of all methods was that the caries were removed according to the peripheral seal zone concept [4], and in deep lesions, inner carious dentin was not removed considering the amount of intact dentin around them. End of this procedure, the remaining dentin was assessed visually and tactilely (rough/soft or smooth/hard) by a ball-ended probe [29].

Blinding

Another co-researcher managed the blinding. To avoid any bias, the operator was unaware of the group the sample belonged to during LF readings and histological examination.

Laser fluorescence (LF) readings (index test)

Before and after caries removal, the teeth were stored in 0.1% thymol solution.

All LF readings were performed under the same lightening conditions. LF readings were performed by the DIAGNOdent Pen (KaVo 2190, 655 nm wavelength) according to the manufacturer's instructions, which recommend first isolating the surface with a cotton pellet and then drying it for 5 s. The device was calibrated before each examination using a black reference in the device's accessory set according to the manufacturer's instructions. The tip of the instrument was placed to the deepest point of the cavity floor. The cut-off value was considered ≥ 30 for the presence of residual caries [30].

Histological examination (reference standard)

A vertical section was taken from the area where the LF readings were obtained. Sections were examined under a dental microscope (OMS 2000, Zumax Company, China). Since a histologic examination procedure was performed after caries removal, and the aim was not to score the level of caries, therefore Downer criteria [31] were not applicable. Histological sections were used to evaluate caries removal efficacy. The success criteria were the quality of underneath, remaining dentin, and the presence of caries-free area around the central lesion (Fig. 2).

The present study was completed by evaluating the cavity floor of 180 extracted teeth after caries removal. Concerning the previous research [32], post- hoc power analysis was performed using G*Power (V3.1.9.7., Heinrich-Heine-University, Düsseldorf, Germany) software. With an effect size of w=0.447 at the 95% confidence interval (1-α) the power of the test (1-β) was obtained as 99.97%.

Statistical analysis

Data were analyzed by IBM SPSS V23. Fisher Freeman Halton test, Yates correction, Fisher's Exact test, and Pearson Chi-Square test were used to compare categorical data. Multiple comparisons were analyzed with the Bonferroni Adjusted Z test. Agreement between measurements was analyzed by Kappa statistic. ROC analysis was used to differentiate the diagnostic value of the histology finding. Sensitivity, Specificity, Accuracy, PPV, NPV values of LF readings in CRTs were calculated.

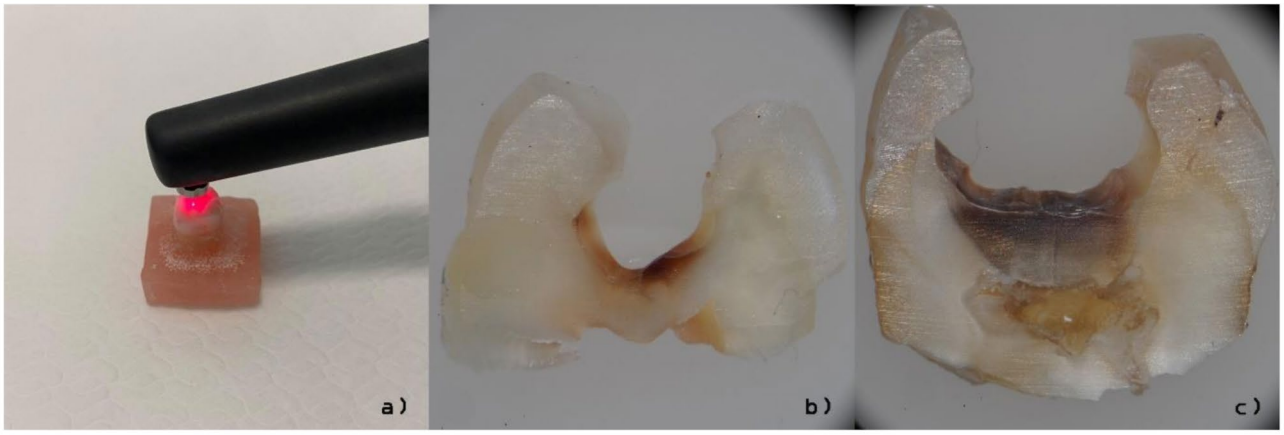

Fig. 2 (**a**) LF readings from cavity floor (**b**) dental microscobe image of a sample which considered effective caries removal (**c**) dental microscobe image of a sample which considered insufficient caries removal

Table 1 Comparison of categorical parameters according to caries removal techniques

	Caries removal techniques				Test statistic	*p*
	Group A	Group B	Group C	Group D		
ICDAS 3 (Histological examination)						
No caries	13 (86.7)	14 (93.3)	13 (86.7)	13 (86.7)	0.485	1.000**
Presence of caries	2 (13.3)	1 (6.7)	2 (13.3)	2 (13.3)		
ICDAS 4 (Histological examination)						
No caries	12 (80)	13 (86.7)	10 (66.7)	10 (66.7)	2.402	0.554**
Presence of caries	3 (20)	2 (13.3)	5 (33.3)	5 (33.3)		
ICDAS 5 (Histological examination)						
No caries	7 (46.7)	10 (66.7)	8 (53.3)	5 (33.3)	3.467	0.325*
Presence of caries	8 (53.3)	5 (33.3)	7 (46.7)	10 (66.7)		
ICDAS3 (LF readings)						
No caries	11 (73.3)	14 (93.3)	12 (80)	11 (73.3)	2.648	0.489**
Presence of caries	4 (26.7)	1 (6.7)	3 (20)	4 (26.7)		
ICDAS 4 (LF readings)						
No caries	11 (73.3)	10 (66.7)	6 (40)	6 (40)	5.589	0.133*
Presence of caries	4 (26.7)	5 (33.3)	9 (60)	9 (60)		
ICDAS5 (LF readings)						
No caries	4 (26.7)	9 (60)	5 (33.3)	1 (6.7)	9.944	**0.022****
Presence of caries	11 (73.3)^{ab}	6 (40)^{b}	10 (66.7)^{ab}	14 (93.3)^{a}		

*Pearson chi-square test; **Fisher Freeman Halton test; a-b: No difference between groups with the same letter

Binary logistic regression analysis was used to assess the relation of caries removal techniques and ICDAS scores with the presence of caries. Analysis results were presented as frequency (percentage). The significance level was taken as $p<0.050$.

Results

When the caries removal efficacy was compared according to ICDAS groups and caries removal techniques, there was no significant difference between the number of specimens detected as caries after histologic examination for all scores ($p>0.05$ for all). However, when LF readings were analyzed, the difference between Group B and Group D was statistically significant for the presence of caries in the ICDAS 5 score ($p=0.022$) (Table 1).

For the ICDAS 3 score, moderate agreement was observed between histological examination and LF readings in Group A and Group D ($\kappa=0.595$; $p=0.012$ for both). In Group B, a significant very high level of agreement was observed between histological examination and LF readings ($\kappa=1.000$; $p<0.001$). Likewise, In Group C, a statistically significant high level of agreement was obtained between histological examination and LF readings ($\kappa=0.762$; $p=0.002$) (Table 2).

For the ICDAS 4 score, in Group A, the agreement between histological examination and LF readings was insignificant ($p=0.080$). In Group B, a significant,

Table 2 The agreement between histological examination and LFreadings (DIAGNOdent Pen) regarding the caries presence according to caries removal techniques in ICDAS 3, 4, and 5 scores

	Caries removal technique		Histological examiation		Kappa	*p*
			No caries	Presence of caries		
ICDAS 3	Group A	ICDAS3 (LF readings)				
		No caries	11 (84.6)	0 (0)	0.595	**0.012**
		Presence of caries	2 (15.4)	2 (100)		
	Group B	ICDAS3 (LF readings)				
		No caries	14 (100)	0 (0)	1.000	**<0.001**
		Presence of caries	0 (0)	1 (100)		
	Group C	ICDAS3 (LF readings)				
		No caries	12 (92.3)	0 (0)	0.762	**0.002**
		Presence of caries	1 (7.7)	2 (100)		
	Group D	ICDAS3 (LF readings)				
		No caries	11 (84.6)	0 (0)	0.595	**0.012**
		Presence of caries	2 (15.4)	2 (100)		
ICDAS 4	Group A	ICDAS 4 (LF readings)				
		No caries	10 (83.3)	1 (33.3)	0.444	0.080
		Presence of caries	2 (16.7)	2 (66.7)		
	Group B	ICDAS 4 (LF readings)				
		No caries	10 (76.9)	0 (0)	0.471	**0.032**
		Presence of caries	3 (23.1)	2 (100)		
	Group C	ICDAS 4 (LF readings)				
		No caries	6 (60)	0 (0)	0.500	**0.025**
		Presence of caries	4 (40)	5 (100)		
	Group D	ICDAS 4 (LF readings)				
		No caries	6 (60)	0 (0)	0.500	**0.025**
		Presence of caries	4 (40)	5 (100)		
ICDAS 5	Group A	ICDAS5 (LF readings)				
		No caries	4 (57.1)	0 (0)	0.587	**0.013**
		Presence of caries	3 (42.9)	8 (100)		
	Group B	ICDAS5 (LF readings)				
		No caries	9 (90)	0 (0)	0.857	**0.001**
		Presence of caries	1 (10)	5 (100)		
	Group C	ICDAS5 (LF readings)				
		No caries	5 (62.5)	0 (0)	0.609	**0.010**
		Presence of caries	3 (37.5)	7 (100)		
	Group D	ICDAS5 (LF readings)			0.250	0.143
		No caries	1 (20)	0 (0)		
		Presence of caries	4 (80)	10 (100)		
	Total	Total (LF readings)				
		No caries	99 (77.3)	1 (1.9)	0.650	**<0.001**
		Presence of caries	29 (22.7)	51 (98.1)		

moderate agreement was observed between histological examination and LF readings (κ=0.471; p=0.032). Similarly, a significant, moderate agreement was observed between histological examination and LF readings in Groups C and D (κ=0.500; p=0.025 for both) (Table 2).

For the ICDAS 5 score, in Group A, a significant moderate agreement was observed between histological examination and LF readings (κ=0.587; p=0.013). In Group B and Group C, histological examination and LF readings presented a significant, high level of agreement (κ=0.857; p=0.001 for Group B, κ=0.609; p=0.010 for Group C). In Group D, there was no significant agreement between histological examination and LF readings (κ=0.250 ; p=0.143). Regardless of the ICDAS scores or caries removal technique, a significant, high level of aggrement was found between LF readings and histological examination (κ=0.650, p<0.001) (Table 2).

Matching, overestimation, and underestimation rates for LF readings at histological examination reference are shown in Table 3. For ICDAS 3, 4, and 5 score groups, the number of overestimation for LF was 5, 14, and 8, respectively, regardless of the caries removal technique.

Table 3 DIAGNOdent Pen's matching, underestimation, and overestimation rates according to caries removal techniques and ICDAS scores

	Caries removal technique				Test statistic	*p*
	Group A	Group B	Group C	Group D		
ICDAS3 (LF readings)						
Matching	13 (86.7)	15 (100)	14 (93.3)	13 (86.7)	2.459	0.740*
Overestimation	2 (13.3)	0 (0)	1 (6.7)	2 (13.3)		
ICDAS4 (LF readings)						
Matching	12 (80)	12 (80)	11 (73.3)	11 (73.3)	3.858	0.900*
Underestimation	1 (6.7)	0 (0)	0 (0)	0 (0)		
Overestimation	2 (13.3)	3 (20)	4 (26.7)	4 (26.7)		
ICDAS5 (LF readings)						
Matching	12 (80)	14 (93.3)	12 (80)	11 (73.3)	2.231	0.643*
Overestimation	3 (20)	1 (6.7)	3 (20)	4 (26.7)		

*Fisher Freeman Halton test

Table 4 ROC analysis results for discriminating histological findings of LF readings in ICDAS 3 and 5 scores, regarding and regardless of the caries removal technique

		AUC (%95 CI)	*p*	Cut off	Sensitivity	Specificity	PPV	NPV	Accuracy
ICDAS 3	Caries removal technique								
	Group A	1 (1–1)	**0.027**	≤ 35	100%	100%	100%	100%	100%
	Group B	1 (1–1)	0.105	---	---	---	---	---	---
	Group C	0.981 (0.912–1)	**0.034**	≤ 33	100%	92.31%	66.67%	100%	93.84%
	Group D	0.846 (0.65–1)	0.126	---	---	---	---	---	---
	Total	0.949 (0.893–1)	**< 0.001**	≤ 30	100%	90.57%	58.33%	100%	84.11%
ICDAS 5	Group A	0.911 (0.748–1)	**0.008**	≤ 39	87.50%	85.71%	87.50%	85.71%	87.01%
	Group B	0.95 (0.84–1)	**0.006**	≤ 34	100%	90%	83.33%	100%	94%
	Group C	1 (1–1)	**0.001**	≤ 38	100%	100%	100%	100%	100%
	Group D	0.74 (0.472–1)	0.142	---	---	---	---	---	---
	Total	0.889 (0.803–0.976)	**< 0.001**	≤ 38	96.67%	76.67%	80.56%	95.83%	89.46%

However, the overestimation and matching rates did not differ significantly regarding the ICDAS scores and caries removal techniques. Also in the ICDAS 4 score, LF underestimated the caries presence of one specimen.

Table 4 shows the ROC analysis results of LF reading in the ICDAS 3 and 5 score. In ICDAS 3 score, LF readings presented maximum area under curve (AUC) value in Group A and Group B ($\kappa=1$; $p=0.027$ for Group A, $\kappa=1$; $p=0.105$ for Group B). Regardless of the caries removal technique, the AUC value of the LF readings was 0.949 in the ICDAS 3 score. In ICDAS 5 score, Group C revealed the highest AUC value C (AUC:1, $p=0.001$) for 38 cut-off point (COP). Group A (AUC: 0.911, $p=0.008$) and Group B (AUC: 0.95, $p=0.006$) also presented a significant AUC value for LF readings. In Group D (tungsten carbide bur and BAG), AUC was not considered significant for LF readings.

In the ICDAS 4 score, the ROC analysis did not demonstrate any significance regarding the AUC value of LF readings, for any caries removal technique ($p>0.05$ for all). ROC curves are presented in Figs. 3 and 4.

Figure 3 shows the ROC curve of LF in ICDAS 3 and 5 scores, regardless of CRT. Figure 4 shows ROC curves regarding the caries removal techniques in ICDAS 5 score.

The effect of independent variables on the presence of caries was examined by binary logistic regression analysis as univariate and multiple model (Table 5). Regarding the histological evaluation, there was no effect of caries removal techniques on caries presence in univariate or multiple models ($p>0.050$). In the univariate model, the risk of caries presence in ICDAS 5 score was 7.571 times higher than ICDAS 3 score ($p<0.001$). In the multiple model, the risk of caries presence was 8.059 times higher than ICDAS 3 score ($p<0.001$).

Regarding the LF readings, the univariate and multiple models showed that the caries removal techniques had no effect on the caries presence ($p>0.050$). The univariate model showed that the presence of caries risk in the ICDAS 4 score was 3.273 times higher than the ICDAS 3 score ($p=0.004$). Also, the risk of caries presence was 8.632 times higher at ICDAS 5 score than ICDAS 3 ($p<0.001$). In the multiple model, the risk of caries presence was 3.569 times higher in ICDAS 4 than ICDAS 3 ($p=0.003$). Also, the risk of caries presence was 10.294 times higher in ICDAS 5 than ICDAS 3 ($p<0.001$).

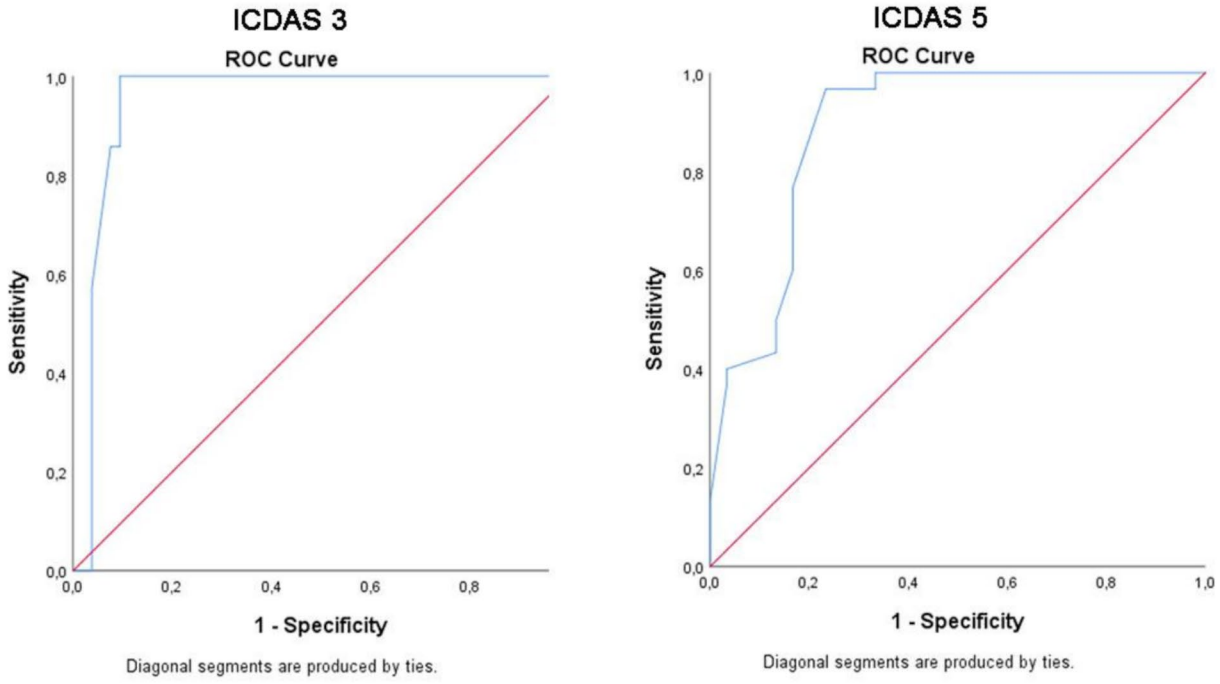

Fig. 3 ROC curve of LF readings in ICDAS 3 and 5 scores regardless of caries removal technique

Discussion

Various caries classification systems have been introduced to develop a universal language for the presentation of clinical conditions. This is because factors such as the depth, location, and activity of the caries lesion are critical to the treatment approach [2]. Accordingly, clinicians may select an alternative caries removal technique, restorative material, adhesive system, or base material [33]. Although it is related to the clinical experience, it is crucial to provide a standard for the clinician to predict the remaining dentinal structure. Therefore, ICDAS, an up-to-date and validated visual scoring system that also allows risk activity assessment, was used to standardize cavity depth in the present study [34]. Although the ICDAS is also a tool for determining caries activity, due to in vitro conditions, the assessment of caries activity has not been performed.

In the ICDAS 5 score and Group D, the number of caries findings was higher overall than in all other groups. However, across all ICDAS score groups and removal methods, the difference in the presence of caries among specimens was not significant. Therefore, the first hypothesis can't be rejected. In the present study, the efficacy of caries removal was assessed regarding the presence of remaining dentinal caries in histological examination. Past to present, caries removal efficacy has been determined in previous studies according to factors such as treatment time, presence of remaining dentinal caries, need for anesthesia, and amount of bacterial colonization [2, 35]. Different results were obtained in the literature when the effectiveness of caries removal was evaluated according to the remaining bacterial growth. Anegundi et al. [36] compared the efficacy of mechanical rotary instruments and chemomechanical caries removal on 30 participants. There was no difference between microbial growth, while cavity size was significantly higher in the mechanical rotary instrument group. Similarly, Divya et al. [14] reported no significant difference between stainless steel bur and chemomechanical removal by Papacarie, regarding the bacterial growth in vitro conditions. Conversely, Ismail et al. [37] reported a reduction in bacterial growth with chemomechanical caries removal by Papacarie compared to the use of ceramic burs in their split-mouth clinical study. Since the caries risk factor and bacterial population will cause variation in bacterial growth in clinical studies, standardizing conditions with split-mouth study designs may provide more reliable results. However, it is not possible to standardize the bacterial population under in vitro conditions due to the storage conditions of the teeth and the possible caries risk factors of the patients. Therefore, the authors believe that the presence of bacteria under more standardized conditions and in patients with similar caries risk classification may provide accurate results, and the present in vitro study did not include a bacterial assessment. Similarly, a dye-based evaluation that shows

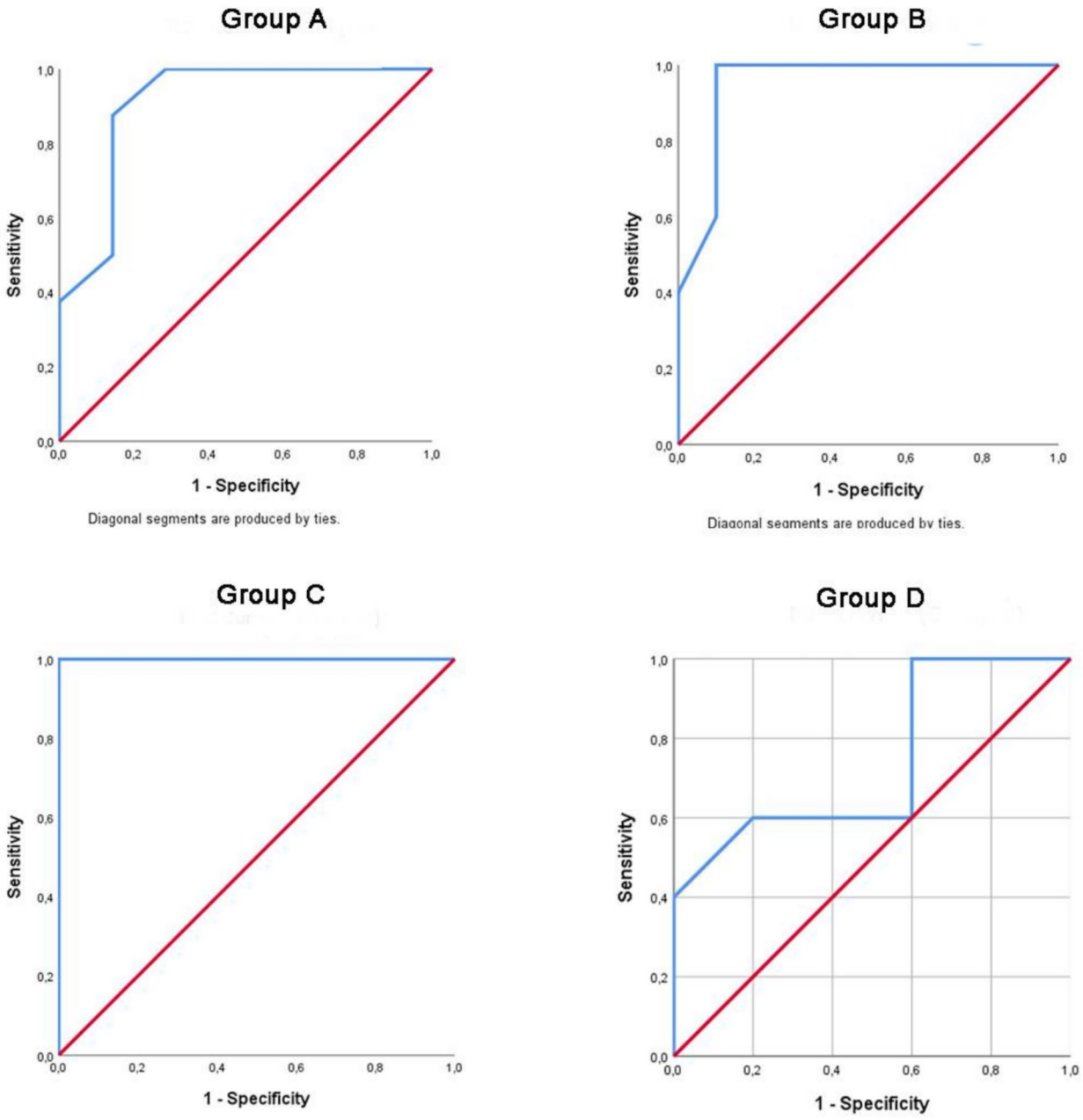

Fig. 4 ROC curves of LF regarding the caries removal technique (ICDAS 5) ; Group **A**: ceramic bur removal ; Group **B**: tungsten carbide bur removal ; Group **C**: tungsten carbide bur& air abrasion (aluminum oxide) removal ; Group **D**: tungsten carbide bur& air abrasion (bioactive glass particles)

the presence of bacterial invasion may not represent the presence of caries that needs to be "removed".

Studies evaluating residual dentin thickness under macrophotography were available in the literature [38, 39]. Therefore, the present study was designed to evaluate remaining dentin by digital photography under magnification with a dental microscope.

The optimal caries removal procedure should leave the mineralized tissue and preserve the underneath, remaining reversible collagen. However, distinguishing the sound and infected dentin may be not possible in every condition. Especially if the lesion progressed over a long time, several dentinal layers including various types of discoloration and hardness might appear. In this situation, the thickness of the leathery dentin may increase and cause a dilemma regarding the caries removal endpoint. The multiplicity of dentinal layers of different depths and hardness can pose a challenge to the clinician's decision-making.

Table 5 Assessment of the effect of ICDAS score and caries removal techniques on caries presence by binary logistic regression analysis

		Univariate		Multiple	
		OR (%95 CI)	***p***	**OR (%95 CI)**	***p***
Histological examination	Caries removal technique (Reference: Group A)				
	Group B	0.532 (0.196–1.446)	0.216	0.492 (0.17–1.42)	0.190
	Group C	1.112 (0.451–2.74)	0.818	1.13 (0.429–2.977)	0.805
	Group D	1.495 (0.618–3.612)	0.372	1.595 (0.615–4.133)	0.337
	ICDAS scores (Reference: ICDAS 3)				
	ICDAS 4	2.524 (0.946–6.733)	0.064	2.576 (0.955–6.943)	0.061
	ICDAS 5	7.571 (2.967–19.318)	**<0.001**	8.059 (3.107–20.908)	**<0.001**
LF readings	Caries removal technique (Reference: Group A)				
	Group B	0.498 (0.205–1.208)	0.123	0.437 (0.166–1.151)	0.094
	Group C	1.309 (0.57–3.007)	0.526	1.389 (0.554–3.482)	0.484
	Group D	2.053 (0.886–4.755)	0.093	2.41 (0.947–6.134)	0.065
	ICDAS scores (Reference: ICDAS 3)				
	ICDAS 4	3.273 (1.453–7.369)	**0.004**	3.569 (1.535–8.302)	**0.003**
	ICDAS 5	8.632 (3.748–19.88)	**<0.001**	10.294 (4.256–24.896)	**<0.001**

LF readings have been proposed to evaluate the remaining dentin during this process. To clarify this, the present study examined the difference between histologic examination and LF readings according to ICDAS scores and CRTs. To elucidate and deepen this issue, the current study focused on diversifying CRTs and caries depth. There was a significant difference in LF and histological examination in terms of caries presence between Groups B and D in the ICDAS 5 score. Therefore, the second hypothesis was partially rejected. Besides, some researchers claimed that laser fluorescence readings related to bacterial metabolites rather than demineralization [40].

In the present study, differences were observed between histology and LF in the ICDAS 4 score. Meanwhile, AUC was found to be significant due to LF and histology mismatch in the ICDAS 4 score group. Previously, some researchers claimed that the use of LF is not reliable in the caries removal endpoint, since the lightness value of the remaining dentin affects the LF readings [10]. The authors believe that this result may be due to the different color, thickness, and hardness patterns of the remaining dentin in the ICDAS 4 score. Sadasiva et al. [41] compared the effectiveness of visual-tactile, visual-tactile&caries detection dye (CDD), visual-tactile&CDD&LF readings in terms of caries removal efficiency in clinical conditions. ICDAS 4 caries scored teeth of patients with moderate caries risk included. In culture samples taken from the cavity floor, the visual tactile&CDD&LF readings combination showed a significantly greater decrease than the other groups in terms of bacterial presence.

The literature review revealed many studies which have large variations of cut-off points for LF readings. Akbari et al. [42] conducted an in vivo study which involved 100 patients. Following caries removal, they performed LF readings before CDD application. Consequently, they reported higher caries presence with CDD rather than LF readings, for both ≥13 and ≥25 COP. Furthermore, while there was no significant difference between tactile examination and LF readings when the COP was set at ≥25, there was a significant difference when it was set at ≥13. Goel et al. [43] considered the ≥35 COP for advanced dentinal caries and 21–35 for initial dentinal caries and assessed the sensitivity, specificity, and accuracy of DIAGNOdent Pen in vitro conditions. They observed that the specificity of LF improved when they determined a higher COP in dentinal caries than the manufacturer's instructions. When evaluated according to the manufacturer's recommended COP for dentin caries, the lowest specificity for LF readings was 70.21%, while when the higher COP formulated for the study was used as mentioned above, they reported that the accuracy of DIAGNOdent Pen was higher (75.90%) than bitewing radiography (60.24%). Unlu et al. [9] evaluated the accuracy of CDD, electronic caries monitor (ECM), and LF readings by DIAGNOdent Pen, following caries removal. They validated the caries presence by histological examination. Accuracy for CDD, ECM, and LF readings was obtained as 0.53, 0.51, and 0.81, respectively, for the ≥30 COP for caries presence. In the present study, the same COP was applied, and while accuracy in the ICDAS 3 score was 84.11%, the AUC of LF for the ICDAS 3 score group was 0.949, and 0.889 for the ICDAS 5 score group, regardless of the caries removal technique. In the ICDAS 5 score group, the accuracy of LF was 89.97% for ≥38 COP, regardless of the caries removal technique. The accuracy values of obtained LF are similar to those obtained by Unlu et al. Considering the results of the present study and previous literature, the operator may need to consider multiple factors in the evaluation of the

remaining dentin, such as the location of the lesion and the hardness of the surrounding tissues, in which case a higher COP for LF readings may be determined.

From the past to the present, the cutting efficiency of burs and abrasive particles has also been under evaluation. Toledano et al. [38] compared the cutting efficiency of a self-limiting polymer bur with carbide burs. They visually assessed the remaining dentin by taking sections after caries removal. Polymer burs with limited cutting ability showed a greater tendency to protect carious dentin and their minimally invasive potential was greater than that of carbide burs. Similarly, Divya et al. [14] reported significantly less dentinal tubule destruction by polymer bur than by stainless steel bur, meanwhile, the bacterial deposits were greater. Melisa et al. [44] compared the dentin-cutting efficiency of BAG particles ranging between 38 and 80 µm, and 29 µm alumina particles. The authors stated that the cutting efficiency of BAG was higher than that of aluminum oxide at the end of 10 s. In addition, the authors showed with scanning electron microscope images that the abrasive particles were embedded in the dentin and could not be completely removed by air-water spray and mentioned this as a limitation of the study. In the present study, although there was no statistically significant difference when the rate of identification of remaining dentin as intact was considered, it was noticeable that there was a higher number of remaining dentin identified as intact when aluminum oxide particles were used. And there was no time limit for caries removal with air abrasion in the present study. However, in terms of caries removal time, air abrasion with BAG took more time than alumina. Regarding particle size, the manufacturer has stated that the particles used in the present study consist of a mixture of 30-60-90 µm of BAG. In this manner, the cutting efficiency of 29 µm alumina particles seems to be higher than that of BAG in the present study in contrast with Melisa et al. [44].

This study has also some limitations. Air abrasion application pressure and distance are constant, but the duration was variable, therefore, all endpoints were set as described, regardless of duration to minimize the bias. Although statistical results for the duration of air abrasion are not presented, a limited discussion of the cutting efficiency of the particles can be done based on the available data and the operator's experience. Further studies are needed to evaluate the cutting efficacy of particles in clinical conditions such as the longevity of the restoration after different caries removal techniques and postoperative sensitivity. Future research might be focus on refining the LF applications and exploring their limitations to enhance the clinical utility. Another limitation of the study was that a quantitative analysis of the histologic evaluation method was not possible. A histological scoring system to evaluate the dentin remaining after caries removal has not been described in the literature. Therefore, the authors determined the presence of caries by evaluating the underlying dentin and surrounding tissue in the sections. Sample size calculation was not performed at baseline, but test power was calculated. A single researcher performed the analysis. Limitations also include the lack of assessment of how much the colony forming unit decreased after CRT.

Conclusions

Within the limitations of this study, the following conclusions might be derived:

1. When selective removal is performed on soft dentin in moderately deep caries (ICDAS 4 score), inconsistency between LF and histology readings may occur. Therefore, LF may be unreliable at the endpoint of caries removal when the remaining dentin topography and affected dentin vary. However, since ICDAS 3-scored caries often expose intact and superficial dentin, LF can be used to determine the end point of caries removal in such cases.
2. Ceramic burs have a selective cutting action and can remove infected caries lesions in a controlled manner.
3. The ability of bioactive glass particles delivered via air abrasion to remove outer caries dentin in a deep carious lesion is poor.
4. The application of BAG among the caries-affected dentin may cause overestimations in LF readings. Clinicians take higher cut-off points for caries removal endpoint in such cases.

Abbreviations

AUC	Area under curve
BAG	Bioactive glass
CDD	Caries detection dye
COP	Cut-off point
CRT	Caries removal technique
ECM	Electronic caries monitor
ICDAS	International Caries Detection and Assessment System
LF	Laser fluorescence

Acknowledgements

Not applicable.

Author contributions

Contributions to this article are as follows: Conceptualization, Ö.K., D.T.; methodology, Ö.K., D.T., B.K., F.Y.; formal analysis, Ö.K., D.T.; investigation, Ö.K., D.T.; data curation, Ö.K., D.T.; writing—original draft preparation, Ö.K., writing—review and editing, D.T., B.K., F.Y., B.K., supervision, D.T., B.K., F.Y., B.K. All authors have read and agreed to the published version of the manuscript.

Funding

This study funded by Support Program for Research Universities (Project code: ADT-2024-11128).

Data availability
The datasets used and/or analyzed during the current study are available from the corresponding author on reasonable request.

Declarations

Ethics approval and consent to participate
This in vitro study was peer-reviewed and approved by the Ethics Committee of Marmara University Faculty of Medicine (reference number: 09.2023.1699). All procedures within this study were performed in accordance with the relevant guidelines and regulations of the Declaration of Helsinki. Informed consent was obtained from each patient for using extracted teeth during the study.

Consent for publication
Not applicable.

Competing interests
The authors declare no competing interests.

Clinical trial number
Not applicable.

Author details
[1]Department of Restorative Dentistry, Faculty of Dentistry, Marmara University Recep Tayyip Erdoğan Complex Health Campus, Başıbüyük Yolu 9/3 34854 Başıbüyük, Maltepe, İstanbul, Türkiye
[2]Department of Restorative Dentistry, Faculty of Dentistry, Istanbul Kent University, Istanbul, Türkiye
[3]Department of Pediatric Dentistry, Faculty of Dentistry, Marmara University, Istanbul, Türkiye
[4]Queen Mary, University of London, London, UK

Received: 5 August 2024 / Accepted: 10 December 2024
Published online: 21 December 2024

References

1. Schwendicke F, Innes N. Removal strategies for caries tissues in deep lesions. In: Schwendicke F, editor. Management of deep carious lesions. Springer; 2018. pp. 20–4.
2. Schwendicke F, Paris S, Tu Y-K. Effects of using different criteria for caries removal: a systematic review and network meta-analysis. J Dent. 2015;43(1):1–15.
3. Kidd E, Fejerskov O. What constitutes dental caries? Histopathology of carious enamel and dentin related to the action of cariogenic biofilms. J Dent Res. 2004;83(1):35–8.
4. Alleman DS, Magen P. A systematic approach to deep caries removal end points: the peripheral seal concept in adhesive dentistry. Quintessence Int. 2012;43(3).
5. Lussi A, Hellwig E. Performance of a new laser fluorescence device for the detection of occlusal caries in vitro. J Dent. 2006;34(7):467–71.
6. Hosoya Y, Kawashita Y, Marshall G Jr, Goto G. Influence of Carisolv™ for resin adhesion to sound human primary dentin and young permanent dentin. J Dent. 2001;29(3):163–71.
7. Lussi A, Hibst R, Paulus R. DIAGNOdent: an optical method for caries detection. J Dent Res. 2004;83(1):80–3.
8. Anttonen V, Seppä L, Hausen H. Clinical study of the use of the laser fluorescence device DIAGNOdent for detection of occlusal caries in children. Caries Res. 2003;37(1):17–23.
9. Unlu N, Ermis RB, Sener S, Kucukyilmaz E, Cetin AR. An in vitro comparison of different diagnostic methods in detection of residual dentinal caries. Int J Dent. 2010;2010:864935.
10. Neves AA, Coutinho E, De Munck J, Lambrechts P, Van Meerbeek B. Does DIAGNOdent provide a reliable caries-removal endpoint? J Dent. 2011;39(5):351–60.
11. Diniz MB, Rodrigues JA, ABd P, Cordeiro RdCL. In vivo evaluation of laser fluorescence performance using different cut-off limits for occlusal caries detection. Lasers Med Sci. 2009;24:295–300.
12. Dammaschke T, Vesnić A, Schäfer E. In vitro comparison of ceramic burs and conventional tungsten carbide bud burs in dentin caries excavation. Quintessence Int. 2008;39(6):495–9.
13. Shivasharan PR, Farhin AK, Wakpanjar MM, Shetty A. Clinical evaluation of caries removal in primary teeth using carie-care and SmartPrep burs: An in vivo study. Indian J Oral Health Res. 2016;2(1):27–31.
14. Divya G, Prasad MG, Vasa AAK, Vasanthi D, Ramanarayana B, Mynampati P. Evaluation of the efficacy of caries removal using polymer bur, stainless steel bur, Carisolv, Papacarie–An in vitro comparative study. J Clin Diagn Res. 2015;9(7):42–6.
15. Paolinelis G, Watson T, Banerjee A. Microhardness as a predictor of sound and carious dentine removal using alumina air abrasion. Caries Res. 2006;40(4):292–5.
16. Sinjari B, Santilli M, D'Addazio G, Rexhepi I, Gigante A, Caputi S, et al. Influence of dentine pre-treatment by sandblasting with aluminum oxide in adhesive restorations. An in vitro study. Materials. 2020;13(13):3026.
17. Narayana SS, Deepa VK, Ahamed S, Sathish ES, Meyappan R, Kumar SK. Remineralization efficiency of bioactive glass on artificially induced carious lesion an in-vitro study. J Indian Soc Pedod Prev Dent. 2014;32(1):19–25.
18. Sauro S, Watson TF, Thompson I, Toledano M, Nucci C, Banerjee A. Influence of air-abrasion executed with polyacrylic acid-Bioglass 45S5 on the bonding performance of a resin-modified glass ionomer cement. Eur J Oral Sci. 2012;120(2):168–77.
19. Loh ZW, Zaid MHM, Kechik MMA, Fen YW, Amin KM, Cheong WM. New formulation calcium-based 45S5 bioactive glass: In vitro assessment in PBS solution for potential dental applications. J Mater Res Technol. 2023;24:3815–25.
20. Banerjee A, Pabari H, Paolinelis G, Thompson ID, Watson TF. An in vitro evaluation of selective demineralised enamel removal using bio-active glass air abrasion. Clin Oral Investig. 2011;15(6):895–900.
21. da Cruz LPD, Hill RG, Chen X, Gillam DG. Dentine tubule occlusion by novel bioactive glass-based toothpastes. Int J Dent. 2018;2018(1):5701638.
22. Cavaleiro-de-Macedo RF, da Silva JA, Siqueira FSF, Campos-Ferreira PV, Cardenas AFM, Carvalho EM, et al. Microtensile bond strength and nanoleakage of self-etching adhesives containing different concentrations of 45S5 bioactive glass in caries-affected dentin. Int J Adhes Adhes. 2024;132:103737.
23. Tsai AC, George R, Teoh Y-Y, Walsh LJ. Laser-fluorescence assessment of sodium hypochlorite quenching reversal agents on human dentine. Photodiagnosis Photodyn Ther. 2022;38:102791.
24. Ho QV, George R, Sainsbury AL, Kahler WA, Walsh LJ. Laser fluorescence assessment of the root canal using plain and conical optical fibers. J Endod. 2010;36(1):119–22.
25. Tsai AC, George R, Walsh LJ. Evaluation of the effect of various endodontic irrigants and medicaments on dentine fluorescence. Photodiagnosis Photodyn Ther. 2022;37:102651.
26. Neuhaus KW, Eggmann F, Kühnisch J, Kapor S, Janjic Rankovic M, Schüler I et al. Standard reporting of caries detection and diagnostic studies (STARCARDDS). Clin Oral Investig. 2022;26:1947–1955.
27. Martins WF, Coelho CSS, do Amaral FLB, França FMG, Turssi CP, Cavalli V, et al. Fracture load and failure mode of semi-direct resin composite occlusal veneers: influence of design and mechanical cycling. J Mech Behav Biomed Mater. 2023;144:105961.
28. Schwendicke F, Frencken JE, Bjørndal L, Maltz M, Manton DJ, Ricketts D, et al. Managing carious lesions: consensus recommendations on carious tissue removal. Adv Dent Res. 2016;28(2):58–67.
29. Braga MM, Mendes FM, Ekstrand KR. Detection activity assessment and diagnosis of dental caries lesions. Dent Clin. 2010;54(3):479–93.
30. Lussi A, Megert B, Longbottom C, Reich E, Francescut P. Clinical performance of a laser fluorescence device for detection of occlusal caries lesions. Eur J Oral Sci. 2001;109(1):14–9.
31. Downer MC. Concurrent validity of an epidemiological diagnostic system for caries with the histological appearance of extracted teeth as validating criterion. Caries Res. 1975;9(3):231–46.
32. Kanar Ö, Tağtekin D, Korkut B. Accuracy of an intraoral scanner with near-infrared imaging feature in detection of interproximal caries of permanent teeth: an in vivo validation. J Esthet Restor Dent. 2024;36(6):845–57.
33. Gözetici-Çil B, Erdem-Hepşenoğlu Y, Tekin A, Özcan M. Selective removal to soft dentine or selective removal to firm dentine for deep caries lesions ın permanent posterior teeth: a randomized controlled clinical trial up to 2 years. Clin Oral Investig. 2023;27(5):2125–37.
34. Ekstrand KR, Gimenez T, Ferreira FR, Mendes FM, Braga MM. The International Caries Detection and Assessment System–ICDAS: a systematic review. Caries Res. 2018;52(5):406–19.

35. Cardoso M, Coelho A, Lima R, Amaro I, Paula A, Marto CM, et al. Efficacy and Patient's acceptance of alternative methods for caries removal—a systematic review. J Clin Med. 2020;9(11):3407.
36. Anegundi RT, Patil SB, Tegginmani V, Shetty SD. A comparative microbiological study to assess caries excavation by conventional rotary method and a chemo-mechanical method. Contemp Clin Dent. 2012;3(4):388–92.
37. Ismail MMM, Al Haidar AHM. Evaluation of the efficacy of caries removal using papain gel (Brix 3000) and smart preparation bur (in vivo comparative study). J Pharm Sci Res. 2019;11(2):444–9.
38. Toledano M, Ghinea R, Cardona JC, Cabello I, Yamauti M, Pérez MM, et al. Digital image analysis method to assess the performance of conventional and self-limiting concepts in dentine caries removal. J Dent. 2013;41:31–8.
39. Berbari R, Khairallah A, Kazan HF, Ezzedine M, Bandon D, Sfeir E. Measurement reliability of the remaining dentin thickness below deep carious lesions in primary molars. Int J Clin Pediatr Dent. 2018;11(1):23.
40. Ástvaldsdóttir Á, Tranæus S, Karlsson L, Peter Holbrook W. DIAGNOdent measurements of cultures of selected oral bacteria and demineralized enamel. Acta Odontol Scand. 2010;68(3):148–53.
41. Sadasiva K, Kumar KS, Rayar S, Shamini S, Unnikrishnan M, Kandaswamy D. Evaluation of the efficacy of visual, tactile method, caries detector dye, and laser fluorescence in removal of dental caries and confirmation by culture and polymerase chain reaction: an: in vivo: study. J Pharm Bioallied Sc. 2019;11(2):146–50.
42. Akbari M, Ahrari F, Jafari M. A comparative evaluation of DIAGNOdent and caries detector dye in detection of residual caries in prepared cavities. J Contemp Dent Pract. 2012;13(4):515–20.
43. Goel A, Chawla H, Gauba K, Goyal A. Comparison of validity of DIAGNOdent with conventional methods for detection of occlusal caries in primary molars using the histological gold standard: an: in vivo: study. J Indian Soc Pedod Prev Dent. 2009;27(4):227–34.
44. Tan MH, Hill RG, Anderson P. Comparing the air abrasion cutting efficacy of dentine using a fluoride-containing bioactive glass versus an alumina abrasive: an in vitro study. Int J Dent. 2015;2015(1):521901.

Publisher's note

Springer Nature remains neutral with regard to jurisdictional claims in published maps and institutional affiliations.