A guidewire introducer as a ureteral foreign body: A case report

Tarik Emre Sener, MD; Jonathan Cloutier, MD; Marie Audouin, MD; Luca Villa, MD; Olivier Traxer, MD

Urology Department, Tenon University Hospital, Pierre et Marie Curie University, Paris, France

Cite as: *Can Urol Assoc J* 2015;9(5-6):E384-6. http://dx.doi.org/10.5489/cuaj.2626
Published online June 18, 2015.

Abstract

A 63-year-old male, previously treated for a ureteral tumour by a right-sided segmental ureterectomy and end-to-end anastomosis of ureteral segments, was referred to our clinic for endoscopic follow-up. During his follow-up, he was diagnosed with partial right-sided ureteral stricture which eventually progressed to complete obstruction. During the ureteroscopy, as the stenotic segment did not allow passage of an hydrophilic guidewire, an antegrade-retrograde approach was decided. On the antegrade endoscopic view, a near-complete stenosis was diagnosed and a nephrostomy catheter (12 Fr) was placed. A second intervention was planned and from the nephrostomy tract, the ureteroscope was placed into the right pyelocaliceal system. The diagnostic ureteroscopy revealed a foreign object proximal to the stenotic area. Right-sided segmental ureterectomy of the stenotic segment with ureteroneocystostomy and removal of the foreign object was performed. This is the only case in literature to reveal a guidewire introducer as a ureteral foreign body. This case also highlights the importance of the fragility of the ureter, the importance of the equipment, of always being watchful during a surgery, and the importance of checking the integrity of the equipment at the end of each procedure.

Introduction

Foreign bodies in the urinary tract are very rare and mostly follow bodies.[1-7] The main problems with ureteral foreign bodies are infections and obstructions due to calcifications. We report an unusual case of ureteral foreign body along with ureteral stenosis.

Case report

A 63-year-old male was referred to our clinic for a 18-mm upper urinary tract tumour. In the past, he had a segmental right ureterectomy due to a right ureteral mass and right-sided end-to-end anastomosis of ureteral segments. During his routinely endoscopic follow-up in December 2011, right distal ureteral stenosis was discovered after the failure to insert a ureteral access sheath and a double J ureteral stent was placed in the right ureter.

In February 2012, an access sheath could not be introduced due to his right partial ureteral stenosis; therefore a double J ureteral stent was placed and left for 10 days. In June 2012, the right ureter could neither be catheterized with a stiff hydrophilic guidewire nor explored with flexible ureteroscope due to nearly-complete ureteral stenosis. The patient was then rescheduled 2 weeks later for a combined antegrade and retrograde approach. A stiff hydrophilic guidewire could not be introduced into the right ureteral orifice. Therefore, under ultrasonographic guidance, we punctured the right middle calyx and introduced a hydrophilic guidewire into the renal pelvis and then into the right ureter. The stenotic segment did not allow us to pass the guidewire into the bladder. The renal access tract was dilated up to 12 Fr with a Coloplast Retrace (Coloplast Inc.) ureteral access sheath 10/12 and flexible ureteroscope was introduced into the renal pelvis and ureter. The stenotic segment in the ureter did not allow passage of the ureteroscope, so a nephrostomy catheter (12 Fr) was placed.

In August 2012, the patient was re-hospitalized for the endoscopic re-evaluation and probable open segmental ureterectomy due to the intractable near-complete ureteral stenosis. A hydrophilic guidewire was placed from the nephrostomy tract into the right pyelocaliceal system and the tract was dilated up to 14 Fr via the Retrace ureteral access sheath 12/14. The URF-V Olympus flexible ureteroscope (Olympus Inc.) was introduced into the urinary tract, and the diagnostic ureteroscopy revealed a foreign object proximal to the stenotic area which was thought to be the introducer of the guidewire (Fig. 1). We decided to perform a right-sided segmental ureterectomy of the stenotic segment and to remove the foreign object. Through a right iliac incision, the right ureter was dissected and the stenotic ureteral segment and foreign object was excised. A ureteroneocystostomy was performed with a Lich-Gregoire anastomosis. A double J

© 2015 Canadian Urological Association



Fig. 1. The endoscopic view of the guidewire introducer.



Fig. 2. The guidewire introducer.

ureteral stent was placed in the right ureter and was removed 6 weeks later without complications.

Discussion

Ureteral foreign bodies are very rare cases and are usually due to suture materials inserted into the ureter mistakenly during other intraabdominal procedures. The symptoms are generally secondary to infections or obstruction due to calcification of the foreign material. The consequences may extend to renal infection with resulting pyonephrosis and sepsis.[1,2] Treatment consists of determining and removing the underlying cause and subsequent findings. The excision of the foreign body is necessary to establish a definive treatment. In our case, the foreign body was a guidewire introducer (Fig. 2), which was introduced inadvertently into the ureter during the first combined approach with the nephrostomy placement.

Guidewires are commonly used in various endoscopic interventions, and it is very rare to perform pathology treatment of the upper urinary tract without a guidewire (Fig. 3, Fig. 4). The importance depends on the easy manipulativity and fragility of the urinary tract. The precision and caution are key points in using this useful surgical equipment. As with inattentiveness, the redundancy of equipment interferes with good surgical outcomes. The guidewire introducer is an infrequently used element of the guidewire equipment and since this event, we have disregarded this unnecessary piece.

Ureteral integrity is one of the most important points in maintaining the blood flow of the ureter. When disrupted, due to ureteral ischemia, ureteral strictures may develop. Although rarely encountered, infectious pathologies, iatrogenic causes, ureteral stones, and their subsequent treatment via ureteroscopy and ureteral access sheaths are blamed for ureteral injury and subsequent ureteral strictures.[8-14] In this



Fig. 3. The guidewire sheath with and without the introducer.

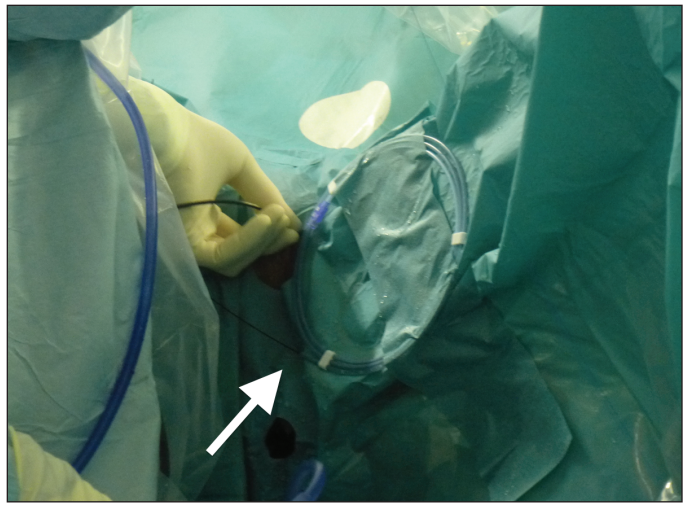

Fig. 4. The stabilization of the guidewire sheath to the drapes during ureteroscopy.

case, the ureteral strictrure was caused by segmental right ureterectomy and right-sided end-to-end anastomosis of ureteral segments. This procedure, although not the cause for the inadvertently foreign object insertion, was the starting point and also the consequent ureteral stricture was one of the main focuses of the surgical team.

With endourological advances, endoscopic management has become one of the most important treatment options for ureteral strictures. Corcoran and colleagues have demonstrated the success of endoscopic treatment via balloon dilatation and/or laser endoureterotomy in their series of 75 patients.[15-16] Also Emiliani and colleagues found that laser endoureterotomy was successful with minimal perioperative morbidity.[16] Despite the reported success rates and low morbidities, endoscopic procedures require attention and a high level of expertise. As suggested by Traxer and colleagues, the ureteral integrity should be assessed at the end of each ureteroscopic procedure.[17] Also, such as in open surgeries, at the end of the procedure, the integrity of all the equipment must be checked for any missing parts after endoscopic procedures.

Conclusion

This is the only case in literature to reveal a guidewire introducer as a ureteral foreign body. This case also highlights the importance of the fragility of the ureter, the importance of the equipment, of always being watchful during a surgery, and the importance of checking the integrity of the equipment at the end of each procedure.

Competing interests: The authors declare no competing financial or personal interests.

This paper has been peer-reviewed.

References

1. Franco Garrrobo N, Alvarez Fernandez M, Collado Montes E. Perirenal abscess and ureteral foreign body. *Med Intensiva* 2013;37:502. Epub 2012 Sep 23.
2. Kojima Y, Asaka H, Ando Y, et al. Perinephric abscess associated with ureteral foreign body. *J Urol* 1998;159:1294. http://dx.doi.org/10.1016/S0022-5347(01)63585-7
3. Restrepo NC, Belis JA. Ureteral foreign body after lases lithotripsy. *J Endourol* 1994;8:29-31. http://dx.doi.org/10.1089/end.1994.8.29
4. Yuzawa M, Hara Y, Kobayashi Y, et al. Foreign body stone of the ureter as a complication of acupuncture: report of a case. *Hinyokika Kiyo* 1991;37:1323-7.
5. Naka Y, Doi H, Harada T, et al. A case of uretero-vaginal fistula with ureteral foreign body stone originated from the suture thread. 1991;37:755-8.
6. Blaut S, Zecha H, Schneider M, et al. Foreign body in proximal ureter after selective embolisation of a renal artery. *Urologe A* 2008;47:1607-10. http://dx.doi.org/10.1007/s00120-008-1886-z
7. Chen WJ, Wang SC, Chen SL, et al. Foreign body in the ureter: A particle of glue after transarterial embolization of a renal pseudoaneurysm during percutaneous nephrostomy. *J Chin Med Assoc* 2012;75:183-6. http://dx.doi.org/10.1016/j.jcma.2012.02.011
8. Handmer MM, Winter M, Lee WG, et al. Unexpected tuberculosis causing ureteral stricture. *ANZ J Surg* 2014; http://dx.doi.org/10.111/ans.12938. Epub 2014 Nov 21. (Epub ahead of print).
9. Selli C, Turri FM, Gabellieri C, et al. Delayed-onset ureteral lesions due to thermal energy: An emerging condition. *Arch Ital Urol Androl* 2014;86:152-3. http://dx.doi.org/10.4081/aiua.2014.2.152
10. Durrani SN, UR Rehman A, Khan S, et al. Ureteral trauma during open surgery: Aetiology, presentation and management. *J Ayub Med Coll Abbottabad* 2013;25:86-9.
11. Oranusi CK, Nwofor A, Onyiaorah IV, et al. Schistosomal stricture of the ureter-diagnostic dilemma. *Niger J Clin Pract* 2011;14:95-8.
12. Liu L, Ma LL, Zhao L, et al. Ureteral stricture following renal transplantation: Risk factors and surgical management. *Beijing Da Xue Xue Bao* 2014;46:548-51.
13. Umul M, Altok M, GüneşM, et al. Distal ureteral stricture: An unexpected complication of further adjuvant intravesical mitomycin C thermotherapy. *Can Urol Assoc J* 2014;8:E453-4. http://dx.doi.org/10.5489/cuaj.1991
14. TaşS, Tuşu V, Mutlu B, et al. Incidence of ureteral stricture after ureterorenoscopic pneumatic lithotripsy for distal ureteral calculi. *Arch Ital Urol Androl* 2011;83:141-6.
15. Corcoran AT, Smaldone MC, Ricchiuti DD, et al. Management of benign ureteral strictures in the endoscopic era. *J Endourol* 2009;23:1909-12. http://dx.doi.org/10.1089/end.2008.0453
16. Emiliani E, Breda A. Laser endoureterotomy and endopyelotomy: An update. *World J Urol* 2015;33:583-7. http://dx.doi.org/10.1007/s00345-014-1405-3. Epub 2014 Sep 23.
17. Traxer O, Thomas A. Prospective evaluation and classification of ureteral wall injuries resulting from insertion of a ureteral access sheath during retrograde intrarenal surgery. *J Urol* 2013;189:580-4. http://dx.doi.org/10.1016/j.juro.2012.08.197

Correspondence: Dr. Olivier Traxer, Tenon University Hospital, Pierre et Marie Curie University, Paris, France; olivier.traxer@tnn.aphp.fr