Turk Neurosurg 36(3):450-456, 2026
DOI: 10.5137/1019-5149.JTN.49617-25.5

Original Investigation

Pediatrics

Received: 27.08.2025
Accepted: 06.01.2026

Published Online: 22.05.2026

Brain Metastases in Pediatric Extracranial Solid Tumors: A 20-Year Experience in Challenging a Rare Diagnosis

Dilek GUL[1], Burcu TUFAN TAS[2], Adnan DAGCINAR[3], Zerrin OZGEN[4], Beste M. ATASOY[4]

[1]MH-Marmara University Hospital, Radiation Oncology Clinic, Istanbul, Türkiye
[2]MH-Marmara University Hospital, Pediatric Hematology Oncology Clinic, Istanbul, Türkiye
[3]Marmara University School of Medicine, Department of Neurosurgery, Istanbul, Türkiye
[4]Marmara University School of Medicine, Department of Radiation Oncology, Istanbul, Türkiye

Corresponding author: Beste ATASOY ✉ bmatasoy@yahoo.com

ABSTRACT

AIM: To investigate the clinical features, treatments, and outcomes of pediatric patients with brain metastasis from extracranial solid tumors, which has been known as a rare condition.

MATERIAL and METHODS: Over a 20-year period, 520 children treated for extracranial solid tumors in our radiotherapy clinic were reviewed, and 12 cases (2.2%) of brain metastases were identified. The primary tumors included neuroblastoma (n=5), osteosarcoma (n=3), Ewing sarcoma (n=2), rhabdoid tumor of the kidney (n=1), and Wilms tumor (n=1). Retrospective analysis was performed to evaluate tumor and treatment features. Overall survival was measured from the initial diagnosis. Overall survival after brain metastasis, local control, and brain metastasis progression-free survival were calculated from the time of brain metastasis diagnosis to death.

RESULTS: Median follow-up was 31 months (range, 13–72 months). Brain metastasis developed at a median of 13 months after primary diagnosis (range, 3–69 months). Most brain metastases were supratentorial and solitary, with nine of 12 patients (75%) having solitary lesions and eight of 12 (67%) having supratentorial lesions. Surgical excision was performed in 9 patients (75%). Radiotherapy was administered locally (20–30 Gy, n=7) or to the craniospinal axis (21.6 or 23.4 Gy, n=2). Ten patients died during follow-up, 70% of whom did not experience cranial progression. Local control rate for irradiated lesions was 81.5% (median duration: 22 months). The brain metastasis-free survival was 71.4% (95% confidence interval [CI]: 2.59%–55.41%) with a median of 10 (range, 1–41) months. The 2-year survival rate was 58.3% (95% CI: 6.15%–71.84%). The 2-year overall survival rate after brain metastasis was 16.7% (95% CI: 7.13%–21.53%).

CONCLUSION: Brain metastasis remains rare in pediatric solid tumors. Most patients died from extracranial disease progression rather than cranial relapse. Radiotherapy can effectively relieve symptoms and may delay the progression of brain metastasis. Guidelines may help optimize the treatment of patients with brain metastasis.

KEYWORDS: Brain metastasis, Imaging, Pediatric tumors, Radiotherapy

ABBREVIATIONS: BMPFS: Brain metastasis progression-free survival, **BM:** Brain metastasis, **CNS:** Central nervous system, **MRI:** Magnetic resonance imaging, **RT:** Radiotherapy, **CT:** Chemotherapy, **GTR:** Gross total resection, **STR:** Subtotal resection, **CSI:** Craniospinal irradiation, **CSF:** Cerebrospinal fluid

Dilek GUL : 0000-0003-0382-8842
Burcu TUFAN TAS : 0000-0003-4614-124X
Adnan DAGCINAR : 0000-0001-9532-7820
Zerrin OZGEN : 0000-0002-0307-6890
Beste M. ATASOY : 0000-0003-1320-9105

INTRODUCTION

Brain metastasis (BM) is the most common tumor of the central nervous system (CNS) in adults, accounting for approximately 30% of all intracranial neoplasms. It most commonly arises from primary cancers of the lungs, breast, gastrointestinal tract, kidneys, and melanoma (1,12). In contrast, in the pediatric population, most CNS tumors are primary, and metastatic lesions are rarely identified (10,12,22). Consequently, evidence-based treatment options and prognostic data remain limited (12-14). The reported frequency of BM in pediatric patients ranges from 1.5% to 4.9% in the literature, while autopsy studies report an incidence of 6%–13% (12-14,24). The most common cancers metastasizing to the brain in pediatric patients are soft tissue and osteogenic sarcomas, neuroplastic tumors, and nephroblastoma (15,16,18-21,24,25).

The protective function of the blood-brain barrier may explain why BM is uncommon in children. The blood-brain barrier is a physical barrier that prevents hematogenous spread of tumor cells to the brain. Therefore, it is thought to reduce the risk of BM in pediatric patients, even in the presence of systemic disease (2,26,27). The brain microenvironment is relatively resistant to metastatic growth due to its unique metabolic constraints and limited lymphocyte infiltration, which hinder the survival and colonization of circulating tumor cells. Furthermore, the absence of specific molecular signals or pre-conditioning factors that promote BM in adults might be less significant in pediatric cancers (9).

Since BM is uncommon in pediatric patients, routine cranial imaging is rarely performed, and BM is usually detected only after CNS imaging prompted by symptoms. BM is typically diagnosed between the ages of 11 and 13 years. It generally occurs 8 to 16 months after the primary tumor is diagnosed (19,23). Common symptoms of BM include signs of increased intracranial pressure, motor weakness or sensory deficits, seizures, changes in mental status, headache, nausea and vomiting, nystagmus, ptosis, and visual field defects, all of which indicate focal neurological deficits (16, 25).

Because of the rarity of the condition and variability in clinical protocols, this study examines the frequency and treatment outcomes of CNS metastases in pediatric patients with extracranial solid tumors treated at our radiotherapy clinic over the past 20 years.

MATERIAL and METHODS

Study Design

This retrospective study was approved by the Marmara University Ethics Committee for Non-Interventional Studies (date: October 2024, approval number: 09.2024.1003) and conformed to the ethical principles of the Declaration of Helsinki (2024). A total of 530 patients underwent radiotherapy (RT) for extracranial pediatric tumors between 2000 and 2020. Ten patients were lost to follow-up, and the analyses were based on 520 patients who continued follow-up at our center. In our analysis, 12 (2.2%) patients with BM were included. The characteristics of the study population are summarized in Table I.

Table I: Clinical and Demographic Characteristics of Pediatric Patients with Brain Metastases from Extracranial Solid Tumors (n=12)

Characteristic	Value
Age (Median-ROI) (years)	5.5 (1-18)
Gender (Girl: Boy) (n)	5:7
Brain metastasis in all related tumors*, (%)	
Neuroblastoma	21.7
Osteosarcoma	18.7
Ewing sarcoma	3.6
Wilms' tumor	3.1
Kidney rhabdoid tumor	25.0
Diagnosis in the study cohort (n=12), n (%)	
Neuroblastoma	5 (41.7)
Osteosarcoma	3 (25.0)
Ewing sarcoma	2 (16.7)
Wilms tumor	1 (8.3)
Kidney rhabdoid tumor	1 (8.3)
Complaints, n (%)	
Nausea-vomiting	5 (41.6)
Seizure	4 (33.0)
Ataxia	3 (25.0)
Hemiparesis	2 (16.6)
Abducens palsy	2 (16.6)
Tumor location, n (%)	
Supratentorial	8 (66.7)
Infratentorial	3 (25.0)
Infra- and supratentorial	1 (8.3)
Extracranial metastatic tumor site, n (%)	
None	5 (41.6)
Multiple	3 (25.0)
Lung	1 (8.3)
Bone	1 (8.3)
Radiotherapy details (n=9), n (%)	
30 Gy/10 fractions to the tumor bed	4 (44.4)
21.6 Gy/12 or 23.4 Gy/13 fractions to CSI**	2 (22.2)
20 Gy in 5 fractions to the tumor bed	2 (22.2)
25 Gy/5 fractions to the tumor bed	1 (11.1)

Total number of patients who were referred to the radiotherapy department due to the risk groups, clinical situations, or protocols; ****CSI: Craniospinal irradiation*

Patients who were referred to the radiotherapy clinic either presented with BMs at diagnosis or developed them after treatment for the primary tumor. All BMs were diagnosed using magnetic resonance imaging (MRI) during staging or following the onset of any neurological symptom indicating an intracranial event. In asymptomatic patients, MRI was performed during primary disease progression following systemic treatment.

Statistical Analysis

Overall survival (OS) was calculated from the date of pathological diagnosis to the date of death or last follow-up. BM progression-free survival (BMPFS) was defined as the time from the detection of BM to CNS progression, including the progression of the irradiated lesion or the appearance of a new lesion. Local control was defined as the time from the start of RT to the clinical and radiological progression of the irradiated lesions. Kaplan–Meier analysis was used to assess survival outcomes.

RESULTS

Nine of 12 patients (75%) had solitary lesions, and eight of 12 (67%) were supratentorial. Six of nine patients with solitary lesions (67%) had supratentorial metastases. The remaining three solitary lesions were infratentorial. Among patients with multiple lesions (n=3), two had supratentorial lesions, and one had an infratentorial lesion.

One-third of patients (n=4) were asymptomatic at the time of BM diagnosis. Brain progression was detected in these patients during extracranial disease progression in Wilms tumor (n=1), osteosarcoma (n=1), neuroblastoma (n=1), and Ewing's sarcoma (n=1). One of these patients was diagnosed with extrarenal (intradural extramedullary) Wilms tumor, and an MRI was performed to assess systemic disease spread, given the unusual localization. The patient diagnosed with osteosarcoma did not receive systemic treatment because the parents declined therapy. The patient diagnosed with neuroblastoma was 18 months old, and an MRI was performed following an unusual and unexpected multiple systemic disease progression. The patient with Ewing's sarcoma received multiple chemotherapy (CT) and RT according to the protocols, and an MRI was performed before the last CT treatment.

The frequent initial symptoms were nausea and vomiting; other symptoms included ataxia and abducens palsy. All patients received antiseizure medications following BM diagnosis, per our neurosurgery protocol, until death. Surgical excision was performed in 75% (n=9) of patients. Ten patients died during follow-up, and 70% had no evidence of cranial progression at death.

At the time of BM diagnosis, most patients (66%) also had extracranial metastasis. Regarding BM treatment, seven patients (58%) received a combined regimen including surgery, RT, and CT. Parents of one patient declined all treatments, and the patient died 3 months after the BM diagnosis. Two patients did not undergo RT for BM. Both were <2 years old at the time of diagnosis, with one having a gross total resection (GTR) and the other a subtotal resection (STR). RT was not considered due to the patients' young age or the possibility of postoperative septic shock.

Patients undergoing surgery had the following profiles: GTR in 7, STR in 1, and biopsy in 1. The purpose of surgery in these patients was to provide both symptomatic relief and oncological treatment, including cytoreduction. RT was primarily delivered to one of two patients for whom surgery was not feasible due to tumor location. One of them indicated CT due to lung metastases but died of respiratory distress before starting treatment. The other patient completed both RT and CT.

Nine patients received RT, either locally (20 to 30 Gy, n = 7) or through the craniospinal route (21.6 to 23.4 Gy, n = 2). Craniospinal irradiation (CSI) was administered due to positive cerebrospinal fluid (CSF) cytology, despite the absence of spinal MRI findings. Both patients had previously undergone GTR for cranial BM. In one patient, a second metastatic brain lesion was detected 18 months after completing initial GTR and RT. During follow-up, MRI-confirmed spinal seeding was identified, and the patient later received CSI. However, 6 months after finishing CSI, this patient died from disease progression.

The median follow-up time from the initial diagnosis was 31 months (range, 13–72). The 2-year survival rate was 58.3% (95% confidence interval [CI]: 6.15%–71.84%) (Figure 1). BM developed a median of 13 months (range, 3–69) during treatment and follow-up. The local control rate for irradiated metastatic brain lesions was 75.8%, with a median duration of 22 months (Figure 2). BMPFS was 71.4% (95% CI: 2.59%–55.41%) at a median of 10 (range, 1–41) months (Figure 3).

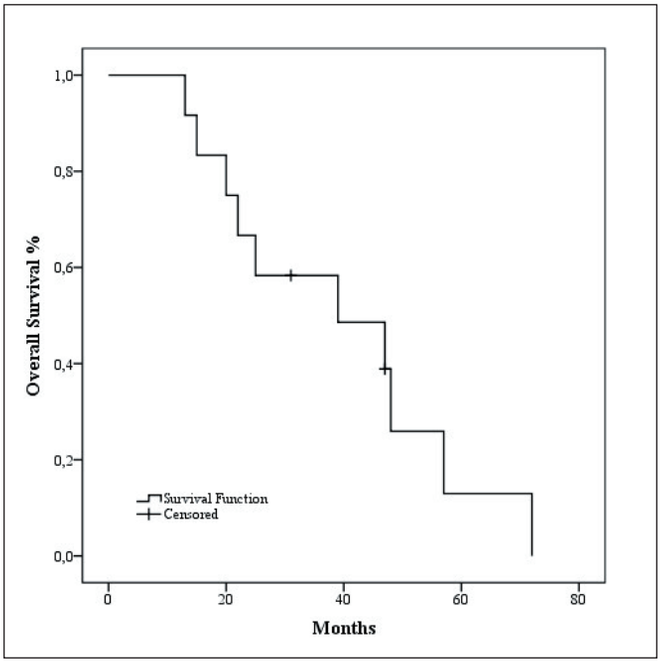

Figure 1: The Kaplan–Meier curve shows the overall survival of pediatric patients with brain metastases from extracranial solid tumors. Censored cases are indicated by tick marks on the survival curve. Months indicate time from primary diagnosis to death or last follow-up.

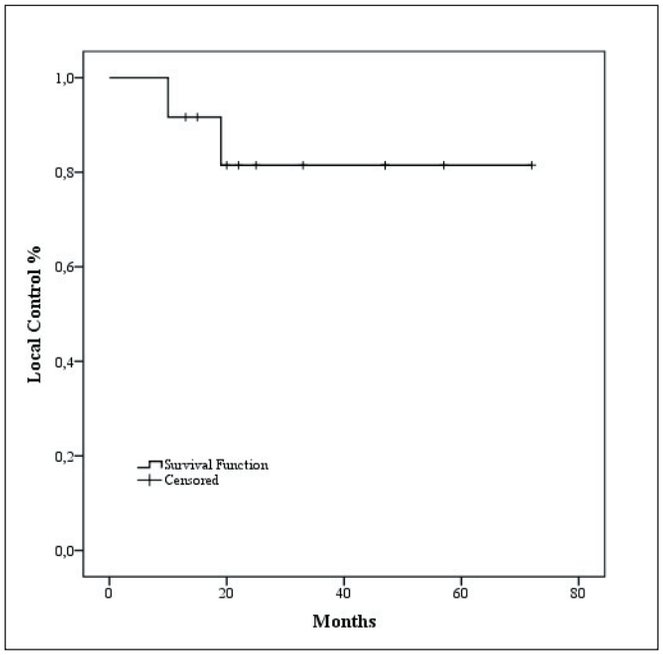

Figure 2: The Kaplan–Meier curve demonstrates local control rates of irradiated brain metastases in pediatric patients with extracranial solid tumors. Tick marks indicate censored observations. Months represent the duration from the start of radiotherapy to clinical or radiological progression of the irradiated lesions.

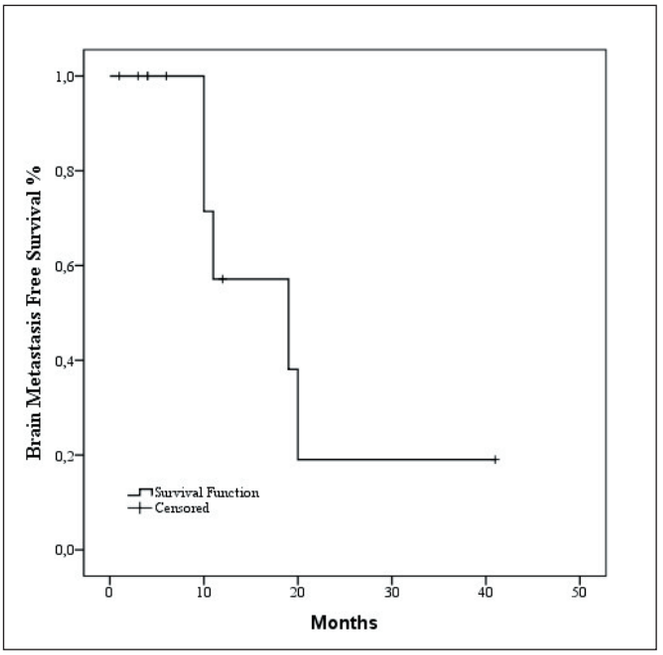

Figure 3: The Kaplan–Meier curve illustrates brain metastasis-free survival in pediatric patients with extracranial solid tumors. Tick marks denote censored events. Months represent the interval from the diagnosis of brain metastasis to the progression of irradiated lesions or the appearance of a newly diagnosed lesion.

The 2-year OS rate after BM was 16.7% (95% CI: 7.13%–21.53%) (Figure 4).

In the neuroblastoma group (n=5), the 2-year OS was 40% (95% CI: 14.26%–35.73%) and the BMPFS was 30% (95% CI: 6.52%–31.47%), with a median follow-up of 25 months (range, 15–47). All five neuroblastoma patients had high-risk disease and were referred to RT.

DISCUSSION

The median time from the diagnosis of the primary tumor to the detection of BM in pediatric solid tumors has been reported to range from 13 to 22 months (2,6-8,12,15). Consistent with previous reports, the median interval in our series was 13 months, with a range of 3 to 69 months. The median follow-up time was 31 (range, 13–72) months from the first diagnosis of the disease.

Neuroblastoma is the most common primary solid tumor that leads to BM in pediatric patients (5,6,8,15). At initial diagnosis, more than 50% of neuroblastoma cases present with widespread disease (5,6,8,15,19). However, BMs account for only 5% of all neuroblastoma cases (8,15,18). In neuroblastoma, CNS metastasis usually arises from adjacent skull metastases, which may lead to parenchymal BM (18). Lung metastases are also rare at diagnosis (6). DuBois et al. reported that 100 out of 2,708 patients with neuroblastoma (3.7%) had lung metastasis. Nearly all patients with lung metastases also have other metastatic sites, and 9% of these patients have BM (6).

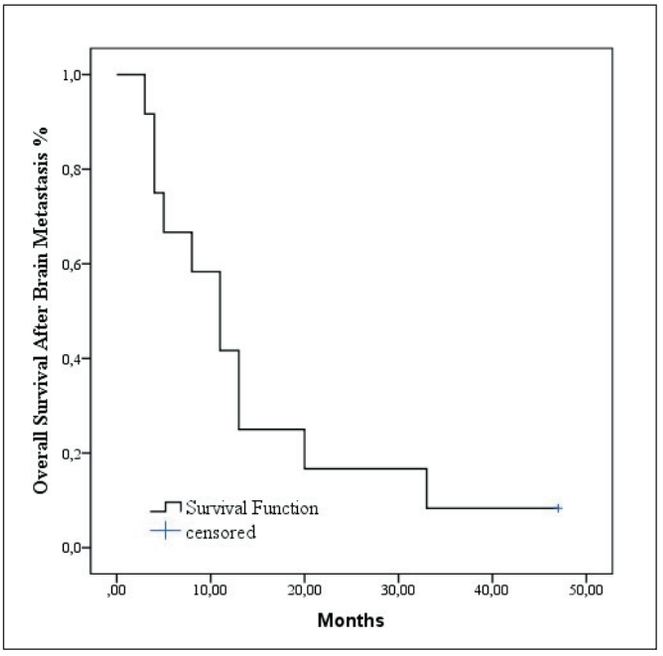

Figure 4: The Kaplan-Meirer curve demonstrates the overall survival in patients with extracranial solid tumor following brain metastasis. Tick marks indicate censored observations. Months represent the duration from brain metastasis to death or last follow-up.

In our study, five patients with neuroblastoma were included; all had high-risk diseases and were referred to RT according to their risk classification. One patient presented with a single supratentorial metastatic focus and no other extracranial metastases. Another patient had multiple metastases, including spinal involvement. Two of the neuroblastoma cases were alive at the time of analysis. Both patients initially presented with multi-organ metastases. On meta-iodobenzylguanidine scans, neither patient showed any uptake, and all MRI evaluations appeared normal. In our cohort, approximately 20% of neuroblastoma cases who were referred to RT developed BM during their treatment and follow-up. However, this rate likely reflects a selection bias, as these patients had high-risk or advanced disease and were referred for RT. Therefore, it may not be representative of the general neuroblastoma population. Moreover, routine cranial imaging may be considered for selected high-risk neuroblastoma patients, particularly those with advanced disease or unusual presentations. Nonetheless, it should be interpreted in the context of selection bias and the rarity of BM in the broader pediatric population. However, more careful cranial imaging evaluation may be warranted in patients with age, myc proto-oncogene, bHLH transcription factor positivity, and a high systemic disease burden (12,28).

Pulmonary metastases are the most common in osteosarcoma, whereas the brain is a rare site of distant metastasis (3,16). Nonetheless, the presence of lung metastases is the most significant factor associated with BMs in children (21). BMs likely originate from hematogenous tumor emboli derived from lung metastases (12). In our study, three patients with osteosarcoma developed BMs, and one of them had lung metastasis at the time of diagnosis. Six of 12 patients had lung metastases when they were diagnosed with BMs.

In our study, the typical presenting symptoms were nausea, vomiting, and seizures. The primary neurological symptoms in children included headaches, lethargy, and seizures (2,7, 11,12). For pediatric patients with non-hematological malignancies and BMs, approximately 10%–15% experience seizures as part of their clinical course. Seizure risk in metastatic cases may be more strongly associated with factors such as multiple lesions, involvement of highly epileptogenic brain regions, cortical involvement, hemorrhagic events, or treatment-related factors. The incidence of seizures was 33% in our cohort, which is higher than that in published reports for pediatric brain tumors and BMs. All metastatic lesions were located in or near the motor cortex. Speech disturbances, hemiparesis, diplopia, and facial palsy due to cranial nerve involvement were also observed, consistent with our cases. Two patients received CSI in our study. Leptomeningeal dissemination has been reported in the literature, in which case CSI may be recommended (4). However, in our cohort, patients received CSI specifically for positive CSF cytology.

Symptomatic treatment of BM involves corticosteroids to reduce peritumoral edema and anticonvulsants to control seizures (7,8,10,11,13). A curative approach includes surgery and/or RT, along with CT. However, the role of chemotherapy in treating BMs remains uncertain. For patients with a single metastasis and no systemic disease, surgery followed by RT and/or CT may be the preferred option. In such cases, combining RT with surgery might be recommended. For patients with multiple BMs, surgery may not be beneficial unless there is a life-threatening symptomatic lesion.

Most affected children ultimately die from their disease, even when brain lesions are successfully managed (12). Many of these children also develop metastases at other sites, which further negatively impact their overall prognosis. Although determining the cause of death in patients with multifocal tumors is challenging, our study found that neurological deterioration was the sole or a contributing cause of death in four of 10 patients who died. In seven patients, death was caused by progression of the primary disease, with no evidence of cranial progression at the time of death, accounting for 70% of cases.

Case series and systematic reviews published through 2024 indicate that cranial metastasis remains rare in pediatric populations, with MRI used selectively (11,16). Meanwhile, clinical management protocols have been actively refined for neuroblastoma, sarcoma, and germ cell tumors. Therefore, routine screening brain MRI is not standard for all patients, but may be considered in high-risk neuroblastoma, alveolar rhabdomyosarcoma, and selected clinical scenarios (neurologic symptoms or highly advanced/metastatic disease).

Our study has several limitations. The retrospective nature of the study, along with differences in RT doses and fields, and variability in patient diagnoses, constituted the foremost limitations. Despite these limitations, RT may improve freedom from neurological progression and increase BMPFS. Our patient cohort was small and included five different tumor types with diverse biological behavior, limiting the interpretation of pooled survival analyses. Therefore, survival and BMPFS rates should be interpreted with caution because of the small cohort size and heterogeneity. No subgroup analyses by diagnosis could be performed to enable robust comparisons or clinical recommendations. The wide confidence intervals for survival outcomes reflected a small sample size and limited statistical power. Therefore, these results should be considered exploratory rather than conclusive, and larger studies are needed for validation.

The limited number of cohorts also restricted the standardization of RT for BM. No stereotactic radiosurgery was planned, none received whole-brain RT, and almost all underwent limited-field (tumor bed) RT. Currently, radiosurgery is not routinely recommended for pediatric patients (17). Furthermore, routine MRI should be included in protocols only for patients with high-risk disease. The frequency of BM in the high-risk group referred for RT might reflect a selection bias and therefore could overestimate the overall incidence. Finally, since this study relied on retrospective data analysis, the outcomes assessed were primarily clinical rather than quality-of-life related.

CONCLUSION

In summary, BM remains a rare event in pediatric extracranial solid tumors. Mortality is predominantly driven by the progres-

sion of systemic disease rather than cranial relapse, and BMs themselves are not the primary cause of death in most cases. The role of CT in treating BMs remains uncertain. Surgery may be considered for patients with a single and/or symptomatic metastatic lesion. RT can effectively relieve symptoms and may delay BM progression. Tailored localized RT may also be recommended to address both the immediate and late radiation-related toxicities. Including the spinal region in imaging and sampling CSF cytology may be recommended before RT, as spinal dissemination can be detected in some patients. Further multicenter studies are needed to better elucidate clinical outcomes and refine imaging recommendations.

Declarations

Funding: This research did not receive any specific grant from funding agencies in the public, not-for-profit, or commercial sectors.

Availability of data and materials: The data that supports the findings of this study are available from the corresponding author upon reasonable request.

Disclosure: All authors declare they have no conflicts of interest.

AUTHORSHIP CONTRIBUTION

Study conception and design: DG, BMA
Data collection: DG, BTT, AD, ZO
Analysis and interpretation of results: DG, BTT, AD, ZO, BMA
Draft manuscript preparation: DG, BMA
Critical revision of the article: DG, BTT, AD, ZO, BMA
Other (study supervision, fundings, materials, etc...): n/a
All authors (DG, BTT, AD, ZO, BMA) reviewed the results and approved the final version of the manuscript.

REFERENCES

1. Arnold SM, Patchell RA: Diagnosis and management of brain metastases. Hematol Oncol Clin North Am 15:1085-1107, vii, 2001. https://doi.org/10.1016/s0889-8588(05)70269-0
2. Bouffet E, Doumi N, Thiesse P, Mottolese C, Jouvet A, Lacroze M, Carrie C, Frappaz D, Brunat-Mentigny M: Brain metastases in children with solid tumors. Cancer 15:79:403-410, 1997. https://doi.org/10.1002/(sici)1097-0142(19970115)79:2<403::aid-cncr25>3.0.co;2-3
3. Briccoli A, Rocca M, Salone M, Guzzardella GA, Balladelli A, Bacci G: High grade osteosarcoma of the extremities metastatic to the lung: long-term results in 323 patients treated combining surgery and chemotherapy, 1985-2005. Surg Oncol 19:193-199, 2010. https://doi.org/10.1016/j.suronc.2009.05.002
4. Cocito C, Martin B, Giantini-Larsen AM, Valcarce-Aspegren M, Souweidane MM, Szalontay L, Dahmane N, Greenfield JP: Leptomeningeal dissemination in pediatric brain tumors. Neoplasia 39:100898, 2023. https://doi.org/10.1016/j.neo.2023.100898
5. Cohn SL, Pearson AD, London WB, Monclair T, Ambros PF, Brodeur GM, Faldum A, Hero B, Iehara T, Machin D, Mosseri V, Simon T, Garaventa A, Castel V, Matthay KK; INRG Task Force: INRG Task Force the International Neuroblastoma Risk Group (INRG) classification system: an INRG Task Force report. J Clin Oncol 10:27:289-297, 2009. https://doi.org/10.1200/JCO.2008.16.6785
6. Dubois SG, London WB, Zhang Y, Matthay KK, Monclair T, Ambros PF, Cohn SL, Pearson A, Diller L: Lung metastases in neuroblastoma at initial diagnosis: A report from the International Neuroblastoma Risk Group (INRG) project. Pediatr Blood Cancer 51:589-592, 2008. https://doi.org/10.1002/pbc.21684
7. Goldman S, Echevarría ME, Fangusaro J: Pediatric brain metastasis from extraneural malignancies: a review. Cancer Treat Res 136:143-168, 2017. https://doi.org/10.1007/978-0-387-69222-7_8
8. Gultekin M, Esen C, Varan A, Akyuz C, Bilginer B, Yildiz F, Gurkaynak M: Pediatric Neuroblastoma with Brain Metastasis: The Prognostic Role of Surgery. Turk Neurosurg 32:204-210, 2022. https://doi.org/10.5137/1019-5149.JTN.33742-21.2
9. Gwak HS: Molecular biology of brain metastases. Brain Tumor Res Treat 11:8-15, 2023. https://doi.org/10.14791/btrt.2022.0045
10. Hudson MM, Neglia JP, Woods WG, Sandlund JT, Pui CH, Kun LE, Robison LL, Green DM: Lessons from the past: opportunities to improve childhood cancer survivor care through outcomes investigations of historical therapeutic approaches for pediatric hematological malignancies. Pediatr Blood Cancer 58:334-343, 2012. https://doi.org/10.1002/pbc.23385
11. Kara L, Unal E, Per H, Kumandas S, Canpolat M, Elmali F, Ozcan A, Yilmaz E, Karakukcu M, Ozdemir MA, Patiroglu T, Gumus H: Neurological complications of children with cancers: Experience from a single center in Türkiye. J Clin Pract Res 46:154-160, 2024. https://doi.org/10.14744/cpr.2024.59622
12. Kebudi R, Ayan I, Görgün O, Ağaoğlu FY, Vural S, Darendeliler E: Brain metastasis in pediatric extracranial solid tumors: survey and literature review. J Neurooncol 71:43-48, 2005. https://doi.org/10.1007/s11060-004-4840-y
13. Klos KJ, O'Neill BP: Brain metastases. Neurologist 10:31-46, 2004. https://doi.org/10.1097/01.nrl.0000106922.83090.71
14. Lamba N, Groves A, Torre M, Yeo KK, Iorgulescu JB: The epidemiology of primary and metastatic brain tumors in infancy through childhood. J Neurooncol 156:419-429, 2022. https://doi.org/10.1007/s11060-021-03927-z
15. Maris JM, Hogarty MD, Bagatell R, Cohn SL: Neuroblastoma. Lancet 23:369:2106-2120, 2007. https://doi.org/10.1016/S0140-6736(07)60983-0
16. Murphy ES, Sahgal A, Regis J, Levivier M, Fariselli L, Gorgulho A, Ma L, Pollock B, Yomo S, Sheehan J, Paddick I, Suh JH, Saxena A, Ahmed MA, Kotecha R: Pediatric cranial stereotactic radiosurgery: Meta-analysis and international stereotactic radiosurgery society practice guidelines. Neuro Oncol 27:517-532, 2025. https://doi.org/10.1093/neuonc/noae204
17. Murphy J, Sundby RT, Resch EE, Rahnama R, Lemberg KM, Maalouf A, Suru A, Fixler J, Ladle BH, Rhee DS, Levin AS, Pallavajjala A, Gocke C, Ladra MM, Groves ML, Acharya S, Gross JM, Llosa NJ, Pratilas CA: Brain Metastasis in pediatric patients with osteosarcoma. Curr Oncol 31:7014-7022, 2024. https://doi.org/10.3390/curroncol 31110516
18. Odone-Filho V, Cristofani LM, Maluf PT, Almeida MTA, Halley N, Vince CSC, de Azambuja AMP, Brumatti M, Lubraico P, da Camara Lopes LHA, Leite KRM, Silva JLF, Plese JPP, Weltman E: Involvement of the central nervous system in neuroblastomas: A potential direct pathway. Med Hypotheses 136:109479, 2010. https://doi.org/10.1016/j.mehy.2019.109479

19. Osawa S, Kumabe T, Saito R, Sonoda Y, Niizuma H, Watanabe M, Tominaga T. Infratentorial brain metastases of pediatric non-epithelial malignant tumors: three case reports. Brain Tumor Pathol 28:167-174, 2011. https://doi.org/10.1007/s10014-010-0014-0
20. Parasuraman S, Langston J, Rao BN, Poquette CA, Jenkins JJ, Merchant T, Cain A, Pratt CB, Pappo AS: Brain metastases in pediatric sarcomas: a single institution experience. Pediatr Blood Cancer 60:1016-1020, 2013. https://doi.org/10.1097/00043426-199909000-00007
21. Paulino AC, Nguyen TX, Barker JL Jr: Brain metastasis in children with sarcoma, neuroblastoma, and Wilms' tumor. Int J Radiat Oncol Biol Phys 57:177-183, 2003. https://doi.org/10.1016/s0360-3016(03)00502-9
22. Singh R, Stoltzfus KC, Chen H, Louie AV, Lehrer EJ, Horn SR, Palmer JD, Trifiletti DM, Brown PD, Zaorsky NG. Epidemiology of synchronous brain metastases. Neurooncol Adv 2:vdaa041, 2020. https://doi.org/10.1093/noajnl/vdaa041
23. Stefanowicz J, Iżycka-Świeszewska E, Szurowska E, Bień E, Szarszewski A, Liberek A, Stempniewicz M, Kloc W, Adamkiewicz-Drożyńska E: Brain metastases in paediatric patients: characteristics of a patient series and review of the literature. Folia Neuropathol 49:271-281, 2011.
24. Suki D, Khoury Abdulla R, Ding M, Khatua S, Sawaya R: Brain metastases in patients diagnosed with solid primary cancer during childhood: experience from a single referral center. J Neurosurg Pediatr 14:372-385, 2014. https://doi.org/10.3171/2014.7.PEDS13318
25. Wiens AL, Hattab EM: The pathological spectrum of solid CNS metastases in the pediatric population. J Neurosurg Pediatr 14:129-135, 2014. https://doi.org/10.3171/2014.5.PEDS13526
26. Wilhelm I, Molnár J, Fazakas C, Haskó J, Krizbai IA: Role of the blood-brain barrier in the formation of brain metastases. Int J Mol Sci 14:1383-1411, 2013. https://doi.org/10.3390/ijms14011383
27. Zhang RD, Price JE, Fujimaki T, Bucana CD, Fidler IJ: Differential permeability of the blood-brain barrier in experimental brain metastases produced by human neoplasms implanted into nude mice. Am J Pathol 141:1115-1124, 1992.
28. Zhu J, Wang J, Zhen ZJ, Lu SY, Zhang F, Sun FF, Li PF, Huang JT, Cai RQ, Sun XF: Brain metastasis in children with stage 4 neuroblastoma after multidisciplinary treatment. Chin J Cancer 34:531-537, 2015. https://doi.org/10.1186/s40880-015-0038-2