Journal of Research in Pharmacy

Research Article

www.jrespharm.com

Radioprotective effect of resveratrol for early and late ionizing radiation-induced damages on colon and rectum in rats

Ayfer BECEREN [1] *, Sezgin AYDEMİR [2], Beste Melek ATASOY [3], Esin AK [4], Feriha ERCAN [5], T. Emre ŞENER [6], Göksel ŞENER [7]

1 Department of Toxicology, Faculty of Pharmacy, Marmara University, Istanbul, Turkey.
2 Department of Pathology Laboratory Technicianship, Vocational School of Health Services, Marmara University, Istanbul, Turkey.
3 Department of Radiation Oncology, School of Medicine, Marmara University, Istanbul, Turkey.
4 Department of Histology and Embryology, Faculty of Dentistry, Marmara University, Istanbul, Turkey.
5 Department Histology and Embryology, School of Medicine, Marmara University, Istanbul, Turkey.
6 Department Urology, School of Medicine, Marmara University, Istanbul, Turkey.
7 Vocational School of Health Services, Fenerbahçe University, Istanbul, Turkey.

* Corresponding Author. E-mail: ayfertozan@hotmail.com, ayfer.tozan@marmara.edu.tr (A.B.); Tel. +90-533-244 25 86

Received: 16 June 2023 / Revised: 07 July 2023 / Accepted: 07 July 2023

ABSTRACT: Radiotherapy, which is routinely used to treat a wide range of oncological disorders, primarily affects the malignant tissue in the targeted area, but also have negative effects in the surrounding tissues. Pelvic radiotherapy causes early and late effects on the colon and rectum. Resveratrol (RVT) has been revealed to have a number of pharmacological effects in a variety of experimental models and clinical circumstances, therefore it has piqued the interest of scientists in recent years. In this study, we aimed to investigate the potential protective effects of resveratrol (RVT), a strong antioxidant, anti-inflammatory and anti-mutagenic agent, against toxicity of colonic and rectal tissues seen in the early and late stages after pelvic radiation. The treatment durations of the current study were designed as one week and ten weeks interval by following radiation exposure. Sprague Dawley rats were divided into 5 groups (8 animals/group) as the control, radiation-early effects (Rd-E), radiation-late effects (Rd-L), and RVT-treated Rd-E (Rd-E+RVT) and RVT-treated Rd-L (Rd-L+RVT) groups. İonizing radiation was performed to the pelvic area that covers colon and rectum in single fraction of 20 Gy in a linear accelerator using with 6 MV photon energy. RVT was orally administered (10 mg/kg/day) immediately following the radiation exposure and continued daily for 1 and 10 weeks for early and late groups, respectively. Pelvic radiation caused a significant decrease in glutathione level, while malondialdehyde levels, myeloperoxidase activity and 8-hydroxydeoxyguanosine were increased in both Rd-E and Rd-L groups in the colon and rectum tissues. Additionally, light microscopic evaluations (H&E staining) revealed degeneration of epithelium and inflammatory cell infiltration in the colonic and rectal tissues in radiation groups. RVT treatment reversed all conducted biochemical parameters and ameliorated histomorphological changes following early and late effects of pelvic radiation in tissues. In conclusion, resveratrol may be a candidate as a radioprotector for normal tissues during and after radiotherapy.

KEYWORDS: Resveratrol, early and late effect of radiation, pelvic radiation, radioprotection, oxidative stress, 8-OHdG.

1. INTRODUCTION

Pelvic radiation is frequently used to treat various oncological pathologies including prostate, colon and rectal cancers [1]. However, the major limitation of this treatment modality is its toxicity on healthy tissues surrounding the target volumes. Thus, the colon and rectum are at high risk as they receive considerable doses of ionizing radiation during abdominal and pelvic radiation radiotherapy [2]. Underlying mechanism in the development and progression of radiation-induced tissue injury are the induction of reactive oxygen species (ROS) and consequently changes in the inflammatory responses followed by molecular changes in the cell [3]. Radiotherapy produces ROS by decomposition of H_2O, resulting in hydroxyl radical (•OH), superoxide

How to cite this article: Beceren A, Aydemir S, Atasoy BM, Ak E, Ercan F, Şener TE, Şener G. Radioprotective effect of resveratrol for early and late ionizing radiation-induced damages on colon and rectum in rats. J Res Pharm. 2023; 27(X): 1617-1625.

© 2023 Marmara University Press
ISSN: 2630-6344

http://dx.doi.org/10.29228/jrp.446

radical ($O_2^{\bullet-}$) and hydrogen peroxide production [4]. As a consequence of the production of these substances, radiation therapy disturbs the chemical structures of DNA, lipids and proteins, as well as activation of early response transcription factors and signal pathways and causes functional alterations [5]. Radiotherapy has the ability of forming single-strand and double-strand breaks in the DNA by splitting chemical bonds on the double helix structure [6]. These undesired effects should be somewhat prevented or reduced and antioxidants can be beneficial to overcome the adverse effects of radiation therapy. Antioxidant molecules can contribute to the body defense system by blocking excessive formation of free radicals, and prevent tissue injury. Thus, development of natural products that inhibit or scavenge the ROS has received great attention as cancer prevention agents.

Resveratrol (3,4´,5-trihydroxystilbene; RVT), a stilbene-type phytoalexin, is found naturally in the skin of plants such as blueberries, cranberries, grapes, peanuts and pines and is useful in resisting environmental stress and fungal infections [7]. RVT attracted great interest after 1992, when it was demonstrated to be responsible for some of the cardioprotective effects of red wine [8]. Since then, numerous studies have shown that RVT exerts beneficial effects on a wide range of pathologies including various cancers, heart diseases and ischemic organ injuries [9, 10]. RVT is known to have multiple biological activities such as antioxidant, anti-inflammatory and anti-carcinogenic activities [11, 12]. As reported before in the literature, the effects of pelvic radiation in the early stage appear within a few days to weeks. However, life-threating consequences occur after the second week and in later stages following the radiation therapy [13]. In the light of information mentioned above, the aim of the present study was to investigate the protective effects of RVT treatment on the early and late periods of radiation-induced oxidative damage in the colon and rectum tissues in a rat model of pelvic irradiation.

2. RESULTS

2.1. Tissue MDA and GSH levels

As an indicator of lipid peroxidation, MDA levels of colon and rectum tissues are seen in Table 1. In the colon tissue; MDA levels were shown to be significantly higher ($p<0.001$) in the Rd-E and Rd-L groups (22.26 ± 1.23 and 22.47 ± 1.1 nmol/g tissuse, respectively) compared to the control (11.34 ± 1.09 nmol/g tissuse). RVT treatment reversed these effects significantly in the Rd-E+RVT and Rd-L+RVT groups ($p<0.001$; 21.41 ± 1.16 and 15.44 ± 0.88 nmol/g tissuse, respectively). Additionally, irradiation exposure diminished the endogenous GSH levels in the colon. On the other hand, the significant reduction in GSH levels was restored back to control level in the Rd-E+RVT and Rd-L+RVT groups ($p<0.01$). In the rectum tissue; MDA levels were significantly increased ($p<0.001$) in the Rd-E and Rd-L groups (26.44 ± 0.83 and 21.05 ± 1.50 nmol/g tissuse, respectively) respect to the control (12.62 ± 0.88). Moreover, GSH levels were statistically diminished by irradiation exposure in the Rd-E and Rd-L groups ($p<0.001$) compared to the control group. On the other hand, RVT treatment significantly reversed these effects and reduced the tissue MDA levels while increasing the GSH levels (Table 1).

2.2. Tissue Myeloperoxidase activity

Myeloperoxidase activity, a remarkable indicator of neutrophil infiltration in the injured tissue, was found significantly elevated in the colon tissue of the Rd-E and Rd-L groups as compared to the control ($p<0.001$). In the Rd-E+RVT and Rd-L+RVT groups, RVT treatment significantly decreased the MPO activities of colon tissue. Similar findings were seen in the rectum tissue, MPO activities were significantly elevated by irradiation exposure in the Rd-E and Rd-L groups compared to control group. RVT treatment in the Rd-E+RVT and Rd-L+RVT groups reduced the MPO activities in rectum tissue (20.87 ± 1.45 and 18.21 ± 1.38 U/ g tissue, respectively) to a level comparable to the control group (Table 1).

2.3. The tissue 8-*OHdG* levels

Quantitative biomarker of oxidative DNA damage was assessed using 8-OHdG ELISA kit. The level of 8-OHdG were significantly ($p<0.001$) higher in the Rd-E and Rd-L groups respect to control group in both the colon and rectum tissues. In the colon tissue, RVT treatment effectively reduced 8-OHdG levels in the early and late period of radiation groups (6.01 ± 1.63, $p<0.01$; 4.66 ± 1.02, $p<0.001$, respectively) (Table 1). Similar findings were seen in the rectum tissue and RVT treatment decreased 8-OHdG levels in the early and late period of irradiation groups ($p<0.01$) compared to Rd-E and Rd-L, respectively (Table 1).

Table 1. Malondialdehyde (MDA), glutathione (GSH) and 8-Hydroxydeoxyguanosine (8-OHdG) levels, and myeloperoxidase (MPO) activity in the colon and rectum tissues of rats.

Groups	MDA (nmol/g tissue)	GSH (µmol/g tissue)	MPO (U/g tissue)	8-OHdG (ng/ml)
Colon				
Control	11.34 ± 1.09	18.55 ± 2.6	12.63 ± 0.23	4.13 ± 0.88
Rd-E	27.26 ± 1.23***	6.6 ± 1.52***	35.98 ± 2.3***	9.25 ± 1.55***
Rd-E+RVT	21.41 ± 1.16+++	9.65 ± 0.45++	23.69 ± 1.85+++	6.01 ± 1.29++
Rd-L	22.47 ± 1.1***	10.62 ± 0.67***	25.32 ± 1.13***	8.27 ± 1.1**
Rd-L+RVT	15.44 ± 0.88###	14.68 ± 0.95##	17.78 ± 2.54###	4.66 ± 0.91###
Rectum				
Control	12.62 ± 0.88	3.70 ± 0.38	15.37 ± 0.31	3.27 ± 0.63
Rd-E	26.44 ± 0.83***	0.57 ± 0.10***	28.53 ± 2.09***	8.37 ± 1.22***
Rd-E+RVT	21.61 ± 1.13+++	1.36 ± 0.14+++	20.87 ± 1.45+++	5.93 ± 0.74++
Rd-L	21.05 ± 1.5***	1.37 ± 0.16***	24.30 ± 1.48***	8.26 ± 1.18***
Rd-L+RVT	17.12 ± 1.1###	2.05 ± 0.38##	18.21 ± 1.38###	5.12 ± 0.72##

Data are represented as mean ± standard deviation (n=8).
** p<0.01, *** p<0.001 compared to the control group.
++ p<0.01, +++ p<0.001 compared to the Rd-E group.
p<0.01, ### p<0.001 compared to the Rd-L group.

2.4. Light Microscopic Findings

Regular colonic and rectal mucosa and submucosa were observed in control group. Degenerated surface and glandular epithelium, inflammatory cell infiltration and submucosal edema were observed in radiation early period (Rd-E) in both colonic and rectal tissues. RVT treatment ameliorated colonic mucosa in radiation early period but, moderate degeneration of surface and glandular epithelium, inflammatory cell infiltration and mild submucosal edema were observed in rectal tissue. Mild degeneration in surface and glandular epithelium, inflammatory cell infiltration and submucosal edema were observed in radiation late period (Rd-E) in both colonic and rectal tissues. Quite regular surface and glandular epithelium, mild inflammatory cell infiltration were observed in Rd-L+RVT group in both colonic and rectal tissues (Figure 1). When the histopathological scoring was evaluated statistically, it was observed that the damage in both tissues (rectum and colon tissues) increased in the Rd-E and Rd-L groups compared to the control group ($p<0.001$). When the radiation exposure groups were compared among themselves, it was statistically determined that the damage of the Rd-E group was higher than the Rd-L Group but the damage was higher versus to control group. The groups receiving RVT treatment and radiation groups were compared among themselves and it was observed that the damage in the RVT treated groups was statistically lower in both colonic and rectal tissues ($p<0.001$) (Table 2).

Table 2. Mean scores of histopathological lesions and Kruskal Wallis Test result on comparison between each group; differences between pairs of means were further elucidated with a Tamhane post hoc test.

	Mean±SD	
Groups	**Colon**	**Rectum**
Control	0.50 ± 0.50	0.50 ± 0.50
Rd-E	9.75 ± 1.90***	10.50 ± 1.20***
Rd-E+RVT	5.88 ± 0.99+++	6.25 ± 0.46+++
Rd-L	8.80 ± 0.76***	8.5 ± 0.53***
Rd-L+RVT	4.88 ± 0.64###	5.63 ± 0.52###
Chi-Square	35.130	36.688
df	4	4
p-value	0.001	0.001

Data are represented as mean ± standard deviation (n=8).
*** p<0.001 compared to the control group.
+++ p<0.001 compared to the Rd-E group.
p<0.001 compared to the Rd-L group.

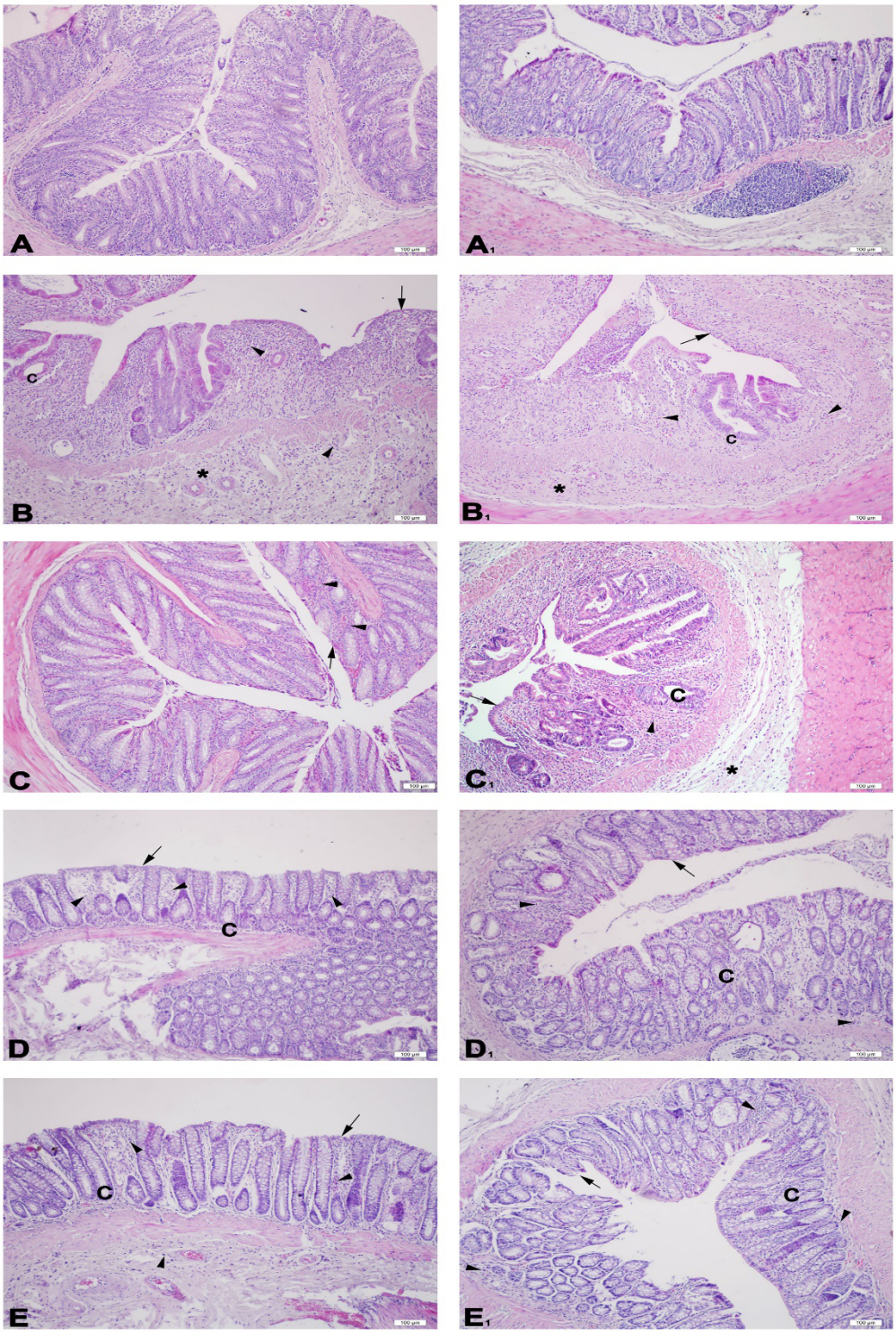

Figure 1: Representative light micrograps of experimental groups are seen. Regular colonic (A) and rectal (A1) mucosa and submucosa are seen in control group. Degenerated surface (arrow) and glandular (c) epithelium, inflammatory cell infiltration (arrowhead) and submucosal edema (*) are observed in both colonic (B) and rectal (B1) tissues of Rd-E group. Quite regular colonic (C) mucosa and submucosa, moderate degeneration in surface (arrow) and glandular (c) epithelium, inflammatory cell infiltration and mild submucosal edema in rectum (C1) are seen in Rd-E+ RVT group. Mild degeneration in surface (arrow) and glandular (c) epithelium, inflammatory cell infiltration (arrow) and submucosal edema (*) are seen in colon (D) and rectum (D1) of Rd-L group. Quite regular surface (arrow) and glandular (c) epithelium, mild inflammatory cell infiltration (arrowhead) is seen in both colon (E) and rectum (E1) tissues of Rd-L+RVT group. H&E staining, original magnification: x200

3. DISCUSSION

The colon and rectum tissues are the most frequently affected tissues due to pelvic radiation [14]. Clinical symptoms of gastrointestinal injury can arise during or soon following radiotherapy [2]. However, there is a lack of knowledge about the protective effects of RVT treatment for the early and late periods of pelvic radiation. The results of this study demonstrated that ionizing pelvic radiation causes oxidative damage in the colon and rectum tissues as demonstrated by increased 8-OHdG and lipid peroxidation levels and decreased GSH storages. RVT treatment decreased the MDA levels and restored GSH storages in these tissues, therefore, RVT may be considered to be protective against the oxidative damage. Along with these findings, oxidative damage of the colon and rectum is followed by neutrophil infiltration in both early and late periods after pelvic radiation. On the other hand, RVT treatment prevented the ionizing radiation-induced MPO activity increases as well as 8-OHdG level increases in both colon and rectum tissues.

Pelvic radiotherapy is one of the primary treatment options for various oncological pathologies. The mechanism of action of radiation therapy is based on destroying neoplastic cells however it may also result in undesired side effects on surrounding normal tissues. Colon and rectum are the potential target organs and life-threatening complications of these organs may emerge during radiotherapy [15]. Although used in treatment of various cancers, ionizing radiation has ability to cause oxidative DNA damage in adjacent healthy cells and it is classified as possibly carcinogenic to humans in Group 2B by IARC (International Agency for Research on Cancer) in 2000 [16]. DNA damage due to radiation therapy is generally by highly unstable •OH radical produced from the hydrolysis of water within the cells. •OH and other free radicals can interact with primarily DNA bases and, to a lesser extent, DNA sugars. The interaction of •OH radical with the DNA nucleobases, such as guanine, results in the formation of 8-hydroxy-2'-deoxyguanosine (8-OHdG) or its tautomer 8-oxo-7-hydro-2'-deoxyguanosine (8-oxodG) [17]. In recent years, the numerous studies, focused on the relationship between the 8-OHdG and oxidative DNA damage, and demonstrated that 8-OHdG can be used as an important biomarker to detect oxidative stress related damages [18, 19]. In the present study, 8-OHdG level increased in colonic and rectal tissues folowing irradiation. Administration of RVT reduced threse free radicals' level in early and late effect groups. These findings suggest that RVT showed antioxidative effects and protected DNA damage on irradiated tissues.

ROS have been demonstrated to be one of the main direct causes of radiation-induced damage and exposure to radiation results in the increased production of ROS and other free radicals. Besides DNA, due to their high reactivity, ROS can also readily react with lipids as well as sensitive enzymes and proteins. Notably, unsaturated fatty acids containing double bonds are susceptible to attack by ROS to yield the lipid radicals [20]. Lipid peroxidation is considered to be an important cause of damage to cells by altering membrane rigidity and permeability, and has been believed to be a contributing factor for progression of ROS-mediated tissue damage [21]. Additionally, the membrane proteins are attacked not only by •OH but also by lipid radicals as a consequence of radiation exposure, therefore, the oxidative protein modifications have also been recognized as they may play a role in the development and progression of the late effects of radiation injury [20]. MDA is one of the most abundant byproducts of lipid peroxidation and is used as a biomarker for determination of oxidative stress following radiation exposure. In previous studies, MDA was found to be increased in the ovaries [22], ileum and colon [23] tissues of rats exposed to radiation therapy, and the treatment with known antioxidant molecules decreased the elevated MDA levels in these tissues. Similarly, the present study demonstrated that there is an increased lipid peroxidation in both early and late period of pelvic radiation as demonstrated by the elevated MDA levels in colon and rectum tissues. On the other hand, compared with the early and late period of radiation, administration of resveratrol was shown to reduce MDA levels in these tissues. Contrary to the increase in MDA levels, GSH, an important antioxidant naturally found in the body, has been depleted in early and late periods of radiation therapy in the colon and rectum tissues. RVT treatment exerted a notable elevation of GSH levels in these tissues. These changes in the aforementioned biomarkers showed that RVT treatment suppressed and ameliorated the oxidative stress induced injury in the colon and rectum tissues in both early and late periods of pelvic radiation.

The pathological progresses of many diseases and acute inflammatory illnesses are linked to the neutrophils' capability to excrete a complex assortment of agents that can impair normal cells and dissolve connective tissue. İnflammatory response can occur in the pathogenesis of tissue injury in radiotherapy. Studies have shown that radiation therapy has the ability to stimulate macrophages, monocytes and fibroblasts, which in turn release pro-inflammatory cytokines, and consequently maintain the inflammatory and fibrogenic processes of radiation damage [24, 25]. MPO, an indicator of inflammatory response, plays an essential role for normal neutrophil function, and when neutrophils are triggered by various stimulants, MPO is excreted from the cells. Activated neutrophils can generate or exacerbate tissue damage through massive secretion of ROS by activating elastase, proteases and MPO [23]. Previous studies have reported that

radiotherapy increased MPO activity in hepatic, colonic, ileal tissues and mouth mucosa [26, 27]. In our study, similarly, we found that MPO activity increases in both early and late effect groups and RVT ameliorates these radiation-induced damages in the colon and rectum tissues. Furthermore, light microscopic findings of the colon and rectum tissues that degenerated epitheliums and inflammatory cell infiltrations was found to be correlated with increased MPO activity in both early and late periods of radiation. RVT treatment also reduced these degenerative effects of radiation therapy by revealing moderate inflammation in the tissues. It seems that RVT reversed neutrophil infiltration in both colonic and rectum tissues, where oxidative damages were also relieved by RVT, it may be suggested that the anti-oxidative role of RVT in these tissues includes depressing of neutrophil releases.

4. CONCLUSION

Although radiotherapy is a key treatment options in many oncological pathologies, the toxicity of this treatment modality in healthy tissues is a major concern in the clinical practice. Ionizing radiation can induce damage in healthy tissues in both acute and late phases. There is a growing interest in exploring new therapeutic agents that may reduce early and late side-effects of radiotherapy. In conclusion, the findings of our study indicate that resveratrol strikingly alleviates the toxic effects of ionizing radiation by inhibiting of neutrophil infiltration and reducing oxidative stress and DNA damage in colon and rectum tissues of rats in both early and late effects. Thus, we can conclude that resveratrol treatment may be beneficial to prevent damage to healthy tissues during and following radiotherapy. Further preclinical and clinical studies are required to suggest resveratrol as a radioprotector in clinical settings.

5. MATERIALS AND METHODS

5.1. Chemicals

Resveratrol, 3-Carboxy-4-nitrophenyl disulfide (DTNB), dimethyl sulfoxide (DMSO), o-dianisidine, 2-thiobarbituric acid (TBA), trichloroacetic acid (TCA), were purchased from Merck KGaA (Darmstadt, Germany); ELISA kit for 8-hydroxy-2'-deoxyguanosine (8-OHdG) was obtained from Elabscience Biotechnology Inc. (Houston, USA). All other chemical were used in analytically grade.

5.2. Animals

The experimental protocols of the present study were approved by a local Animal Care and Use Committee (Approval ID: 08.2014.mar). Sprague Dawley rats with the body weight of 250 to 300 g were used in this study. Animals were housed in polypropylene cages at room temperature (22 ± 2°C) with 12 h light/12 h dark cycle. Animals were fed with a standard rat pellet and water was available ad libitum.

5.3. Experimental Design

Sprague Dawley rats were randomly divided into 5 experimental groups with 8 rats in each: control (C), radiation-early effects (1 week) (Rd-E), radiation-late effects (10 weeks) (Rd-L), Rd-E + resveratrol (Rd-E+RVT) and Rd-L + resveratrol (Rd-L+RVT). Radiation was performed to the pelvic area that covers colon and rectum in single fraction of 20 Gy in a linear accelerator using with 6 MV photon energy. Resveratrol was given 10 mg/kg orally for 1 week in the Rd-E+RVT group and for 10 weeks in the Rd-L+RVT. Upon completion of the experimental protocol, all animals were decapitated, and colon and rectum tissues were excised. For biochemical assays, tissue samples of each organ were separately kept at -20°C until determinations of malondialdehyde (MDA), glutathione (GSH) levels, myeloperoxidase (MPO) activity and 8-OHdG measurements. For histopathological examination, tissue samples were stored in 10% neutral buffered formalin at room temperature.

5.4. Tissue MDA and GSH levels

MDA levels were determined by monitoring TBA reactive substance formation as described previously [28]. Colon and rectum tissues were homogenized in ice-cold 10% trichloroacetic acid, then centrifuged at 3000 rpm for 15 min. Supernatant was collected and the reaction between same volume of TBA and supernatant was monitored to determine tissue MDA levels at 100°C based on the level of absorbance at 532 nm in a spectrophotometer (Beckman Coulter DU 73, Fullerton, California, USA). The results were expressed as nmol MDA/g tissue. GSH levels were measured with modified Ellman procedure in the colon and rectum tissues by a spectrophotometer at 412 nm [29]. Results were expressed as µmol GSH/g tissue.

5.5. Tissue Myeloperoxidase activity

MPO activity was assayed in a procedure similar to that described by Hillegas et al. [30]. Colon and rectum tissue samples were homogenized in ice-cold 50 mM potassium phosphate buffer (PB) containing 0.5% hexadecyltrimethylammonium bromide (HETAB), and ethylenediaminetetraacetic acid (EDTA) then centrifuged at 12.000 rpm and 4°C for 10 minutes. Aliquots were added to 2.9 mL of reaction mixture consist of 50 mM PB, o-dianisidine and 20 mM H2O2 solution at 37°C. One unit of enzyme activity that caused a change in absorbance measured with spectrophotometer at 460 nm for 3 minutes. MPO activity was expressed as U/g tissue.

5.6. Enzyme-linked Immunosorbent Assay (ELISA) for 8-Hydroxydeoxyguanosine (8-OHdG)

The small pieces of tissues were rinsed in ice-cold PBS (phosphate buffered saline, 0.01M, pH=7.4) to remove excess blood. Then, tissue pieces were weighed and homogenized in ice-cold PBS with a glass homogenizer. The homogenates were then centrifuged for 5 min at 5000×g and supernatants were collected. The 8-OHdG levels were measured with 8-OHdG ELISA Kit (Cat. No: E-EL-0028, Elabscience Biotechnology Inc., Houston, USA) by according to the manufacturer's instructions. Briefly, standards (5 different concentrations) or samples were added into the appropriate wells in duplicate and then incubated at 37°C. Followed by the chromogenic reaction, the absorbance was measured at 450 nm using a microplate reader (Epoch, BioTek Instruments, Inc., Winooski, USA). The content of 8-OHdG in the tissue samples was expressed as ng/ml.

5.7. Light microscopic preparation

Colon and rectum samples were fixed with 10% neutral formaldehyde, dehydrated with ascending alcohol series and cleared with toluene and embedded in paraffin. Approximately 5 µm thick sections were stained with hematoxylin and eosin (H&E) for histological evaluation at light microscope (Olympus BX51, Tokyo, Japan) and photographed with digital camera (Olympus DP72, Tokyo, Japan). Assessment of the intestinal injury was performed by using the previously described criteria: Damage/necrosis (0: none, 1: localized, 2: moderate, 3: severe); Submucosal edema (0: none, 1: mild, 2: moderate, 3: severe); Inflammatory cell infiltration (0: none, 1: mild, 2: moderate, 3: severe); Vasculitis (0: none, 1: mild, 2: moderate, 3: severe); Perforation (0: absent, 1: present), with a maximum score of 13 [31].

5.8. Statistics

Statistical analysis was carried out using SPSS 17.0 (SPSS Inc, Chicago, IL, USA). All results are given as mean ± standard deviation (SD); groups of data were compared with ANOVA followed by Tukey's multiple comparison tests; $p<0.05$ was considered as significant.

Acknowledgements: None.

Author contributions: All the authors contributed equally to the experiments. All authors read and approved the final manuscript.

Conflict of interest statement: The authors have declared that there is no conflict of interest.

REFERENCES

[1] Abdallah NM, Noaman E, Eltahawy NA, Badawi AM, Kandil E, Mansour NA and Mohamed HE. Anticancer and radiosensitization efficacy of nanocomposite *Withania somnifera* extract in mice bearing tumor cells. Asian Pac J Cancer Prev. 2016;17(9):4367-4375.

[2] Shadad AK, Sullivan FJ, Martin JD, Egan LJ. Gastrointestinal radiation injury: symptoms, risk factors and mechanisms. World J Gastroenterol. 2013;19(2):185-198. https://doi.org/10.3748/wjg.v19.i2.185.

[3] Schmidt-Ullrich RK, Dent P, Grant S, Mikkelsen RB, Valerie K. Signal transduction and cellular radiation responses. Radiat Res. 2000;153(3):245-257. https://doi.org/10.1667/0033-7587(2000)153%5b0245:stacrr%5d2.0.co;2.

[4] Ertekin MV, Koçer I, Karslioğlu I, Taysi S, Gepdiremen A, Sezen O, Balci E, Bakan N. Effects of oral *Ginkgo biloba* supplementation on cataract formation and oxidative stress occurring in lenses of rats exposed to total cranium radiotherapy. Jpn J Ophthalmol. 2004;48(5):499-502. https://doi.org/10.1007/s10384-004-0101-z.

[5] Dainiak N, Tan BJ. Utility of biological membranes as indicators for radiation exposure: alterations in membrane structure and function over time. Stem Cells. 1995;13 Suppl 1: 142-152.

[6] Hubenak JR, Zhang Q, Branch CD, Kronowitz SJ. Mechanisms of injury to normal tissue after radiotherapy: a review. Plast Reconstr Surg. 2014;133(1):49e-56e. https://doi.org/10.1097/01.prs.0000440818.23647.0b.
[7] Pervaiz S, Holme AL. Resveratrol: its biologic targets and functional activity. Antioxid Redox Signal. 2009;11(11): 2851-2897. https://doi.org/10.1089/ars.2008.2412
[8] Siemann EH and Creasy LL. Concentration of the phytoalexin resveratrol in wine. Am J Eno Vitic. 1992;43: 49-52.
[9] Jang M, Cai L, Udeani GO, Slowing KV, Thomas CF, Beecher CW, Fong HH, Farnsworth NR, Kinghorn AD, Mehta RG, Moon RC, Pezzuto JM. Cancer chemopreventive activity of resveratrol, a natural product derived from grapes. Science. 1997;275(5297): 218-220. https://doi.org/10.1126/science.275.5297.218.
[10] Della-Morte D, Dave KR, DeFazio RA, Bao YC, Raval AP, Perez-Pinzon MA. Resveratrol pretreatment protects rat brain from cerebral ischemic damage via a sirtuin 1-uncoupling protein 2 pathway. Neuroscience. 2009;159(3):993-1002. https://doi.org/10.1016/j.neuroscience.2009.01.017.
[11] Martinez J, Moreno JJ. Effect of resveratrol, a natural polyphenolic compound, on reactive oxygen species and prostaglandin production. Biochem Pharmacol. 2000;59(7):865-870. https://doi.org/10.1016/s0006-2952(99)00380-9.
[12] Alturfan AA, Tozan-Beceren A, Sehirli AO, Demiralp E, Sener G, Omurtag GZ. Resveratrol ameliorates oxidative DNA damage and protects against acrylamide-induced oxidative stress in rats. Mol Biol Rep. 2012;39(4):4589-4596. https://doi.org/10.1007/s11033-011-1249-5.
[13] Brown KR, Rzucidlo E. Acute and chronic radiation injury [published correction appears in J Vasc Surg. 2012;55(2):627]. J Vasc Surg. 2011;53(1 Suppl):15S-21S. https://doi.org/10.1016/j.jvs.2010.06.175.
[14] Monti P, Wysocki J, van der Meeren A, Griffiths NM. The contribution of radiation induced injury to the gastrointestinal tract in the development of multi-organ dysfunction syndrome or failure. Br J Radiol Suppl. 2005;27: 89-94. https://doi.org/10.1259/bjr/53186341.
[15] Ooi BS, Tjandra JJ, Green MD. Morbidities of adjuvant chemotherapy and radiotherapy for resectable rectal cancer: an overview. Dis Colon Rectum. 1999;42(3):403-418. https://doi.org/10.1007/BF02236362.
[16] International Agency for Research on Cancer (IARC). Ionizing radiation, part 1: X- and gamma (γ)-radiation, and neutrons in IARC monographs on the evaluation of carcinogenic risks to humans, volume 75. IARC, Lyon-France, 2000.
[17] Panés J, Granger DN. Neutrophils generate oxygen free radicals in rat mesenteric microcirculation after abdominal irradiation. Gastroenterology. 1996;111(4):981-989. https://doi.org/10.1016/s0016-5085(96)70065-3.
[18] Dizdaroglu M, Jaruga P. Mechanisms of free radical-induced damage to DNA. Free Radic Res. 2012;46(4):382-419. https://doi.org/10.3109/10715762.2011.653969.
[19] Aydemir S, Akgun SG, Beceren A, Yuksel M, Kumas M, Erdogan N, Sardas S, Omurtag GZ. Melatonin ameliorates oxidative DNA damage and protects against formaldehyde-induced oxidative stress in rats. Int J Clin Exp Med. 2017;10(4): 6250-6261.
[20] Fenga C, Gangemi S, Teodoro M, Rapisarda V, Golokhvast K, Docea AO, Tsatsakis AM, Costa C. 8-Hydroxydeoxyguanosine as a biomarker of oxidative DNA damage in workers exposed to low-dose benzene. Toxicol Rep. 2017;31(4):291-295. https://doi.org/10.1016/j.toxrep.2017.05.008.
[21] Zhao W, Robbins ME. Inflammation and chronic oxidative stress in radiation-induced late normal tissue injury: therapeutic implications. Curr Med Chem. 2009;16(2):130-143. https://doi.org/10.2174/092986709787002790.
[22] Kaya H, Delibas N, Serteser M, Ulukaya E, Ozkaya O. The effect of melatonin on lipid peroxidation during radiotherapy in female rats. Strahlenther Onkol. 1999;175(6):285-288. https://doi.org/10.1007/BF02743581.
[23] Deniz M, Atasoy BM, Dane D, Can G, Erzik C, Çetinel Ş, Yeğen BÇ. Radiation-induced oxidative injury of the ileum and colon is alleviated by glucagon-like peptide-1 and -2. J Radiat Res Appl Sci. 2015;8(2): 234-242. https://doi.org/10.1016/j.jrras.2015.01.010.
[24] Rubin P, Finkelstein J, Shapiro D. Molecular biology mechanisms in the radiation induction of pulmonary injury syndromes: interrelationship between the alveolar macrophage and the septal fibroblast. Int J Radiat Oncol Biol Phys. 1992;24(1):93-101. https://doi.org/10.1016/0360-3016(92)91027-k.
[25] Stanojković TP, Matić IZ, Petrović N, Stanković V, Kopčalić K, Besu I, Đorđić Crnogorac M, Mališić E, Mirjačić-Martinović K, Vuletić A, Bukumirić Z, Žižak Ž, Veldwijk M, Herskind C, Nikitović M. Evaluation of cytokine expression and circulating immune cell subsets as potential parameters of acute radiation toxicity in prostate cancer patients. Sci Rep. 2020;10(1):19002. https://doi.org/10.1038/s41598-020-75812-0.
[26] Velioğlu-Oğünç A, Sehirli O, Toklu HZ, Ozyurt H, Mayadağli A, Ekşioğlu-Demiralp E, Erzik C, Cetinel S, Yeğen BC, Sener G. Resveratrol protects against irradiation-induced hepatic and ileal damage via its anti-oxidative activity. Free Radic Res. 2009;43(11):1060-1071. https://doi.org/10.1080/10715760903171100.
[27] Panés J, Granger DN. Neutrophils generate oxygen free radicals in rat mesenteric microcirculation after abdominal irradiation. Gastroenterology. 1996;111(4):981-989. https://doi.org/10.1016/s0016-5085(96)70065-3.
[28] Casini AF, Ferrali M, Pompella A, Maellaro E, Comporti M. Lipid peroxidation and cellular damage in extrahepatic tissues of bromobenzene-intoxicated mice. Am J Pathol. 1986;123(3):520-531.
[29] Aykaç G, Uysal M, Yalçin AS, Koçak-Toker N, Sivas A, Oz H. The effect of chronic ethanol ingestion on hepatic lipid peroxide, glutathione, glutathione peroxidase and glutathione transferase in rats. Toxicology. 1985;36(1):71-76. https://doi.org/10.1016/0300-483x(85)90008-3.
[30] Hillegass LM, Griswold DE, Brickson B, Albrightson-Winslow C. Assessment of myeloperoxidase activity in whole rat kidney. J Pharmacol Methods. 1990;24(4):285-295. https://doi.org/10.1016/0160-5402(90)90013-b.

[31] Stress-induced enhancement of colitis Gué M, Bonbonne C, Fioramonti J, Moré J, Del Rio-Lachèze C, Coméra C, Buéno L. in rats: CRF and arginine vasopressin are not involved. Am J Physiol. 1997;272(1 Pt 1): G84-G91. https://doi.org/10.1152/ajpgi.1997.272.1.g84.