Cardiology and Cardiovascular Surgery I

Editor
Mustafa PAÇ

AKADEMiSYEN
KiTABEVi

© Copyright 2019

Printing, broadcasting and sales rights of this book are reserved to Academician Publishing House Inc. All or parts of this book may not be reproduced, printed or distributed by any means mechanical, electronic, photocopying, magnetic paper and/or other methods without prior written permission of the publisher. Tables, figures and graphics cannot be used for commercial purposes without permission. This book is sold with banderol of Republic of Turkey Ministry of Culture.

ISBN
978-605-258-349-4

Page and Cover Design
Akademisyen Dizgi Ünitesi

Name of Book
Cardiology and Cardiovascular Surgery I

Publisher Certificate Number
25465

Editor
Mustafa PAÇ

Printing and Binding
Bizim Matbaacılık

Publishing Coordinator
Yasin Dilmen

Bisac Code
MED010000

GENERAL DISTRIBUTION
Akademisyen Kitabevi A.Ş.

Halk Sokak 5 / A
Yenişehir / Ankara
Tel: 0312 431 16 33
siparis@akademisyen.com

www.akademisyen.com

PREFACE

The directors of Academician Publishing House, have been conducting their commercial activities for a long time by transferring their 30 years of broadcasting experience to their legal entities. In the said period, it was proud to publish 750 books, particularly health and social sciences, cultural and artistic topics. The Academician, that defines the platform of being an international publishing house, is in the pursuit of creating a global brand in addition to broadcasting in Turkish and foreign languages.

The books, which are considered as permanent documents of scientific and intellectual studies, are the witnesses of hundreds of years as an information recording platform. **The future of the book, which has built on a solid basis with the invention of the printing press, will certainly have a place in our lives for a long period of time, even though it has moved into orbit of new inventions.**

Academician Publishing House has started the process of publishing books in international quality and quantity with its own name of "**Scientific Research Book**" series in Turkish and English. The publication process, which will take place in March and September every year, will continue with thematic sub titles. We owe to our thanks to all of our researchers who supported this process, which was starting with about 30 books, and to everyone in the background.

Academician Publishing House Inc.

CONTENTS

Chapter 1 Surgical Management of Acute and Chronic Pulmonary Embolism.....1
Mihriban YALÇIN

Chapter 2 Extracorporeal Membrane Oxygenation.....7
Mihriban YALÇIN

Chapter 3 Atherectomy For Lower Extremity Intervention: Why, When, and Which Device?.....13
Orhan RODOPLU

Chapter 4 Comparison Of Endovascular Laser Ablation With Nontumescent N-Butyl Cyanoacrylate Vena Saphena Magna Ablation.....19
Orhan RODOPLU

Chapter 5 Complications Related to Ecmo Use.....29
Şahin İŞCAN

Chapter 6 Electrocardiographic Findings of Wide Qrs Complex Tachycardias.....39
Alper KEPEZ
Abdülkadir USLU

Chapter 7 Cardioplegia Methods From Past Till Present.....53
Ayşe LAFÇI
Derya GÖKÇINAR

Chapter 8 Epicardial Adipose Tissue: From Cell to Bed Side.....59
Murat ZİYREK

Chapter 1

SURGICAL MANAGEMENT OF ACUTE AND CHRONİC PULMONARY EMBOLISM

Mihriban YALÇIN[1]

INTRODUCTION:

Pulmonary embolism (PE) is a common and life-threatening emergency cardiovascular disorder.

PEs are categorized either as submassive or massive. When unexplained hypotension is present, acute PE is defined as massive. These patients have especially high risk of mortality due to right ventricular (RV) failure and cardiovascular collapse. (LeVarge, Wright &Rodriguez-Lopez, 2018)

Acute massive pulmonary embolism is related with high mortality and morbidity rates, in spite of advances in diagnosis and therapy. Right ventricular failure and shock can be seen in patients with massive and submassive acute PE. In some patients, endogenous thrombolysis mechanisms fail and chronic PE develops. Systemic thrombolysis, catheter-based thrombolysis or embolectomy, extracorporeal membrane oxygenation (ECMO) support, and surgical embolectomy are treatment strategies. (LeVarge, Wright & Rodriguez-Lopez, 2018)

Surgery can be effective in treatment of convenient patients with acute and chronic PE.

INCIDENCE AND ETIOLOGY:

The incidence of PE increases with age, especially in the 7th decade, and is more common in males at this age. In the group under the age of fifty years, it is seen more frequently in women due to pregnancy and oral contraceptive use. (Peter & Fedullo, 2000)

In situ pulmonary arterial thrombus is rarely seen. 80-90% pulmonary embolism is the most serious complication of deep venous thrombosis; the diagnosis, however, can be difficult due to the atypical presentation. (Hirsch, 1990)

[1] MD, Ordu State Hospital Department of Cardiovascular Surgery, mihribandemir33@hotmail.com

CLINICAL SYMPTOMS:

In one study, 40% of patients with deep vein thrombosis had non-symptomatic pulmonary embolism. (Stahl, David & Lacner, 1984) In symptomatic cases, chest pain (88%), shortness of breath (84%), cough (53%), hemoptysis (30%) are among the most common symptoms. The pain due to pulmonary embolism can be seen in a very variable range from sudden onset pleuritic sharp pain, to unclear shoulder, abdomen and substernal pain. Since the findings are variable and nonspecific, angina, myocardial infarction, asthma, congestive heart failure, hepatitis, herpes zoster, sepsis, pancreatitis are some of the diseases that should be considered in the differential diagnosis. (Szues & et al. 1971, UPET, 1973). More than 50% of cases of fatal pulmonary embolism are diagnosed during autopsy. (Morgenthaler & Ryu, 1995)

DIAGNOSIS:

Pulmonary angiography is still the gold standard for diagnosis. Especially ventilation / perfusion (V / P) scintigraphy, investigations for deep vein thrombosis (DVT), computed tomographic methods, D-dimer determination and echocardiographic examinations, as well as the use of appropriate diagnostic algorithms significantly reduced the need for invasive diagnostic methods. (Saro & et al. 1999).

TREATMENT:

Patients with PE require hemodynamic and respiratory support. Before thrombolytic therapies surgical embolectomy was the only chose for patients in shock, but now medical management with heparin derivatives and oral anticoagulants are first therapy choices. (LeVarge, Wright & Rodriguez-Lopez, 2018)

Anticoagulation is the mainstay of therapy. Most patients recover with only anticoagulation therapy (Kearon & et al 2008), but a subset of patients with massive PE die because of hemodynamic collapse. (Sandler & Martin, 1989, Lindblad, Eriksson & Bergqvist, 1991)

Pharmacologic lytic therapy (Todd & Tapson, 2009) or catheter-based rheolytic therapy (Chechi, Vecchio & Spaziani, et al. 2009) may be considered when hemodynamic compromise is present. (strongly recommended (grade 1 American College of Chest Physicians (ACCP) recommendation) unless major contraindications for bleeding are present. (Kearon & et al. 2008). Streptokinase, urokinase and recombinant tissue plasminogen activator (tPA) form thrombolytic therapy. Surgical embolectomy should be preferred for patients with massive PE, with

hemodynamic compromise in whom anticoagulation is contraindicated, with persistent shock and with an embolus in transit. (Samoukovic, Malas & deVarennes, 2010) Embolectomy may restore cardiac functions. Surgery is usually successful when PE is located in the main left or right pulmonary arteries and in the absence of a large distal thrombus load. (Moorjani & Pric, 2013) Keeling et al reported 23.7% mortality rate for massive PE after surgical embolectomy. (Keeling, Sundt & Leacche, et al. 2016)

Chronic thromboembolic disease occurs in less than 3.8% of patients with acute PEs (Shemin,2017) These patients are candidates for endarterectomy.

OPERATIVE TECHNIQUES:

For embolectomy:

After median sternotomy bicaval and ascending aortic cannulation are done and cardiopulmonary bypass (CPB) initiates, aortic cross-clamping is performed. a longitudinal incision is made in the main pulmonary artery and embolus is removed from the pulmonary artery and right ventricle. (Figure 1) The distal pulmonary arteries are checked for additional emboli. They are controlled with a Fogarty balloon catheter. After the arteriotomy is closed, if there is concomitant diseases, it is also corrected and CPB is weaned.

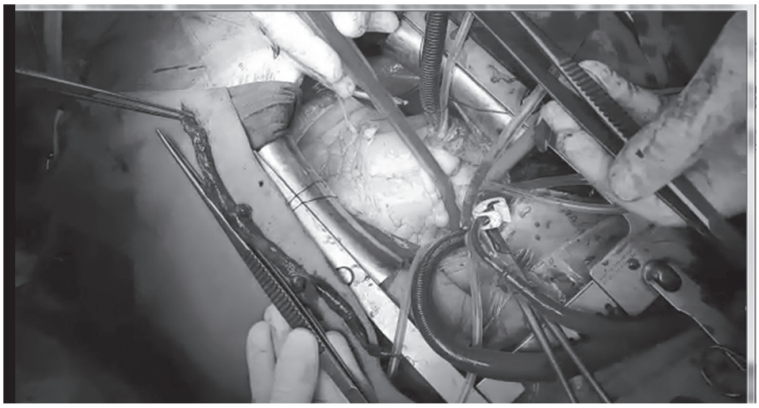

Figure 1. Intraoperative view of embolus

For endarterectomy:

After median sternotomy bicaval and ascending aortic cannulation are done and cardiopulmonary bypass (CPB) initiates, aortic cross-clamping is performed. Deep hypothermic circulatory arrest with cooling to 18ºC is started. Pulmonary artery is opened and pulmonary thromboendarterectomy is performed (Figure

2) And if there is concomitant diseases, it is also corrected. (Figure 3) When the patient is rewarmed, CPB is weaned.



Figure 2. Intraoperative view of opened right pulmonary artery

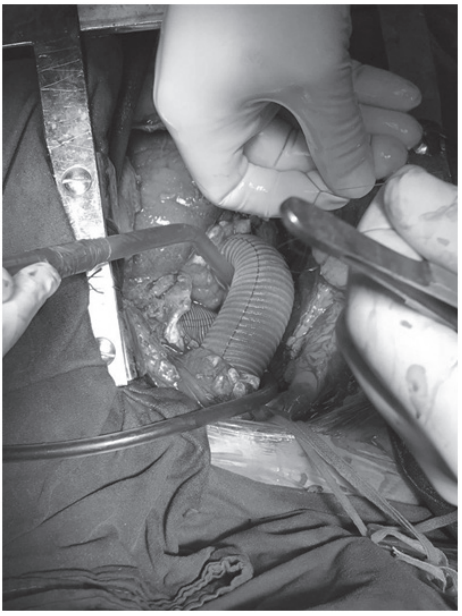

Figure 3. Intraoperative view of assending aortic dacron graft and right pulmonary artery repaired with patch

CONCLUSION:

Pulmonary embolism (PE) is related with high mortality and morbidity rates. Surgical pulmonary embolectomy and pulmonary thromboendarterectomy are well-known strategies for treating patients with acute and chronic PE.

Both techniques [pulmonary embolectomy and thromboendarterectomy (PTE)] require sternotomy and cardiopulmonary bypass, but PTE also requires deep hypothermic circulatory arrest (intervals of 20 minutes with a 10-minute reperfusion period). (Shemin,2017) Anticoagulation should be started as soon as possible after maintaining postsurgical hemostasis and the patients remain on anticoagulation for life. Pulmonary embolectomy for acute pulmonary emboli and thromboendarterectomy for chronic disease is approxiate with correcting the accompanying surgical problem.

REFERENCES:

1. Chechi T, Vecchio S & Spaziani G, et al. (2009) Rheolytic thrombectomy in patients with massive and submassive acute pulmonary embolism. Catheter cardiovasc Interv, 73(4),506-13.
2. Hirsch J. (1990) Diagnosis of venous thrombosis and pulmonary embolism. Am J Cardiol, 65, 45-9.
3. Kearon C & et al. (2008) American College of Chest Physicians. Antithrombotic therapy for venous thromboembolic disease: American College of Chest Physicians Evidence- Based Clinical Practice Guidelines (8th Edition). Chest 134(4):892.
4. Keeling WB & et al. (2016) SPEAR Working Group. Outcomes after surgical pulmonary embolectomy for acute pulmonary embolus: a multi-institutional study. Ann Thorac Surg, 102(5),1498-502.
5. LeVarge BL,Wright CD & Rodriguez-Lopez JM. (2018) Surgical Management of Acute and Chronic Pulmonary Embolism Surgical Management of Acute and Chronic Pulmonary Embolism. Clin Chest Med, 39, 659–67.
6. Lindblad B, Eriksson A & Bergqvist D. (1991) Autopsy-verified pulmonary embolism in a surgical department: analysis of the period from 1951 to 1988. Br J Surg, 78(7),849-52.
7. Moorjani N & Price S. (2013) Massive pulmonary embolism. Cardiol Clin, 31(4),503-18.
8 Morgenthaler TI & Ryu JH. (1995) Clinical characteristics of fatal pulmonary embolism in a referral hospital. Mayo Clin Proc, 70, 417-24.
9. Peter F & Fedullo MD.(2000) Pulmonary thromboembolism. In: Murray JF, Nadel JA, eds. Textbook of Respiratory Medicine. Philadelphia: WB Saunders Company,1503-32.
10. Samoukovic G, Malas T & deVarennes B. (2010) The role of pulmonary embolectomy in the treatment of acute pulmonary embolism: a literature review from 1968 to 2008. Interact Cardiovasc Thorac Surg,11(3), 265-70.

11. Sandler DA & Martin JF.(1989) Autopsy proven pulmonary embolism in hospital patients: are we detecting enough deep vein thrombosis? J R Soc Med, 82(4),203-5.
12. Saro G, & et al. (1999) Diagnostic approach to patients with suspected pulmonary embolism: A report from real world. Postgrad Med J, 75,285-9.
13. Shemin RJ. (2017) Surgical Embolectomy for Massive and Submassive Pulmonary Embolism and Pulmonary Thromboendarterectomy for Chronic Thromboembolic Pulmonary Hypertension. Tech Vasc Interv Radiol., 20(3),175-78.
14. Stahl RL, David JP & Lacner H. (1984) Unrecognized pulmonary embolism presenting as disseminated intravascular coagulation. Am J Med, 76:772.
15. Szues MM & et al. (1971) Diagnostic sensitivity of laboratory findings in acute pulmonary thromboembolism. Ann Intern Med, 74,161-6.
16. Todd JL & Tapson VF. (2009) Thrombolytic therapy for acute pulmonary embolism: a critical appraisal. Chest, 135(5),1321-1329.
17. UPET (1973): The Urokinase Pulmonary Embolism Trial: A national cooperative study. Circulation, 47,1-108.

Chapter 2

EXTRACORPOREAL MEMBRANE OXYGENATION

Mihriban YALÇIN[1]

INTRODUCTION

Extracorporeal membrane oxygenation (ECMO) is an assist device for providing prolonged but temporary cardiac or respiratory support. While in patients with normal heart function veno-venous (VV) ECMO is sufficient for respiratory support, in acute heart failure veno-arterial (VA) ECMO should be applied.

ECMO is the smaller, closed and portable state of the standard cardiopulmonary bypass device. The cannulas are specially designed for ECMO. ECMO consists of nonpulsatile pump, membrane oxygenator, entry and exit cannula of flow. The mean duration of treatment required for most patients is 1 week.

HISTORY

Firstly, membrane oxygenator was formed in laboratory conditions in 1950s. (Gibbon, 1954) After successful application of the heart-lung machine in 1953 by Gibbon, Hill et al. was treated a 24 - year - old patient who had undergone aortic transection after traffic accident with femoro-femoral venoarterial ECMO for 3 days in 1971. (Hill, O'Brien & Murray)

MECHANISM OF ECMO

Blood is drawn from the venous circulation. Oxygenation increases, carbon dioxide decreases. Blood is given back to the patient's venous or arterial circulation. ECMO is used as a temporary support unit to prevent organ damage in patients with pulmonary or cardiac failure (or both) when there is no other treatment option or failure. ECMO is a modification of the cardiopulmonary bypass pump, which is mainly used routinely in cardiac surgery.

INDICATIONS:

ECMO indications can be analyzed in two separate titles; cardiac and respiratory-induced causes. ECMO can be applied in 2 ways:VA and VV. (Ayık & et al.,2014)

[1] MD, Ordu State Hospital Department of Cardiovascular Surgery, mihribandemir33@hotmail.com

The most common indication for cardiac induced cause is the diffuculty for weaning from cardiopulmonary bypass (CPB). (Marasco & et al.,2005) ECMO is also used for neonatal and paediatric respiratory support.

1.VA ECMO Indications:

It provides both gas exchange and circulation support. It is used in heart and lung failure. Low-flow VA ECMO with small catheters in cardiac and pulmonary insufficiency is considered as an emergency resuscitative procedure (ECMO CPR). The right atrium, femoral vein, subclavian vein, internal jugular vein can be used as venous outlet and the aorta, femoral artery, axillary artery, subclavian artery and carotid artery can be used as an arterial return location.

Cardiogenic Shock :

1. Acute coronary syndrome
2. Myocarditis
3. Peripartum cardiomyopathy
4. Resistant cardiac arrhythmia
5. Drug overdose / toxicity leading to deep cardiac depression
6. Acute anaphylaxis
7. Pulmonary embolism
8. Sepsis with deep cardiac depression
9. Failure to weaning cardiopulmonary bypass after cardiotomy

Bridge for Another Treatment:

1. Primary graft failure after heart-lung transplantation
2. Chronic cardiomyopathy (long-term VAD insertion / transplantation)
3. Support for high-risk percutaneous cardiac interventions
4. Transition to heart transplantation

2. VV ECMO Indications:

It provides only gas exchange. It is applied in isolated lung failure. Femoral vein, subclavian vein, internal jugular vein and right atrium can be used for outlet and return location. Double lumen catheters are mainly used.

1. ARDS
2. Pneumonia
3. Trauma
4. Primary graft failure after lung transplantation
5. Hypoxic despite the optimal mechanical ventilator support
6. Hypercapnic respiratory failure

CONTRAINDICATIONS:

VA ECMO Contraindications:

1. Heart failure is irreversible and inappropriate for transplant or VAD
2. Diffuse malignancy
3. Known advanced brain injury
4. Unrecognized cardiac arrest
5. Extended cardiopulmonary resuscitation (CPR) devoid of appropriate tissue perfusion
6. Aortic dissection
7. Advanced aortic insufficiency
8. Advanced chronic organ dysfunction (emphysema, cirrhosis, renal failure)
9. Peripheral VA ECMO inadvanced peripheral artery disease
10. The obstacle to the use of anticoagulation, obesity and advanced age. are considered as a relative contraindications

VV ECMO Contraindications:

1. Mechanical ventilation at high settings over 7 days
2. Non-witness cardiac / respiratory arrest
3. Common malignancy
4. Major pharmacological immunosuppression (neutrophil count <400 mm3)
5. Recent or progressive central nervous system bleeding
6. Non-recyclable major CV damage
7. Terminal malignancy
8. Advanced pulmonary hypertension (mPAP> 45-50mmHg, or> systemic blood pressure of 75%)

ECMO COMPLICATIONS:

1. Bleeding/ Hemolysis
2. Infection
3. Coagulopathy / Thrombocytopenia
4. Non-Pulsatile Perfusion of End Organs:

- Kidney failure
- Splanchnic circulation disorder
- GI bleeding, ulceration and perforation
- Liver dysfunction

5. Mechanical Complications:

- Tube rupture
- Pump Disorder
- Technical error, such as connecting problems

6. Local Complications:

- Leg ischemia (especially in peripheral VA ECMO application)
- Air embolism / Thromboembolism

7. Neurological:

- Intracerebral hemorrhage



Figure 1. The photograph of an ECMO device

GENERAL INFORMATION:

Weaning from CPB means a spontaneous heart activity with sufficient blood flow and pressure through the pulmonary and systemic circulation. For successful weaning from CPB prompt decision(including pharmacological support, ventricular assistance, and additional surgical interventions) is necessary to prevent myocardial damage. Because of structural or functional cardiac abnormalities, vasoplegic syndrome, or ventricular dysfunction some of cardiac surgical patients have difficulty to wean off CPB.

Ischemia, reperfusion organ injury, or activation of compliments, neutrophils, and cytokines by the cardiopulmonary bypass machine are the reasons of low cardiac output syndrome after routine cardiac surgical operations.(Smith & et al., 2001, Doll & et al.,2004) Postcardiotomy cardiogenic shock occurs in 0.5–5% of adult cardiac operations. (Doll & et al.,2004) Despite the usage of inotropes and IABP, it is a critical clinical condition with the high mortality rate, only a low percentage of patients (25–48%) survive to be discharged home. (Loforte & et al., 2011, Rastan & et al., 2010) Surgical tissue trauma, myocardial ischemia, reperfusion injuries, down regulation of beta-adrenergic receptors, coronary embolization (air, atheroma, etc.), activation of inflammatory and coagulation cascades, uncorrected preexisting cardiac disease,and myocardial stunning are causes of post-CPB ventricular dysfunction.(Knapp & et al., 2016)

ECMO is considered a suitable short-term therapy of cardiorespiratory insufficiency following cardiac surgery, especially for patients with severe pulmonary edema, with persistent ventricular arrhythmias and with right ventricle failure. (Bartlett & Gattinoni, 2010) The main indications for ECMO support are to maintain right ventricular and/or pulmonary function. (Finney, 2014) Patients were considered to be ECMO candidates when their cardiac index is less than 2.0 L/min despite adequate filling volumes, use of multiple inotropic agents, and insertion of IABP. ECMO rapidly improves patients hemodinamics and end-organ function. Most important parameters to improve the outcomes are patient selection, timing and management. Old age, evidence of organ system dysfunction, history of previous cardiac operation, extensive aortic operations, neurologic events, and not using an IABP are the factors for the increased mortality. (Smedira & et al., 2001)

Several authors reported the successful use of ECMO for cardiopulmonary failure.(Smith & et al., 2001, Smedira & et al., 2001, Ko & et al., 2002) And several studies have demonstrated mortality rates of 50% to 70% among patients requiring ECMO support. (Goldstein & Oz, 2000, Magovern & et al., 1994) Russo et al. reported three postcardiotomy ECMO usage, one patient has been transplanted, one weaned from ECMO and one dead-on device support. (Russo & et al., 2010) Vanzetto et al. reported that it is an acceptable modality for temporary circulatory support for the stunned myocardium. (Vanzetto & et al., 2009)

CONCLUSION:

ECMO is an important device to provide mechanical circulatory and respiratory support during acute, reversibl cardiopulmonary failure in patients . ECMO can provide effective mechanical support in cardiac surgery patients during post-

operative periods. It is an expensive therapy and is only available at a limited number of centers, some critically ill patients who otherwise had no chance of survival, may benefit from this treatment

REFERENCES:

1. Ayık MF & et al.(2014) Kalp Cerrahisinde Ekstrakorporeal Membran Oksijenasyonu (ECMO) Kullanımının Genişlemekte Olan Endikasyonları. Turkiye Klinikleri J Cardiovasc Surg-Special Topics, 6(2),97-101.
2. Bartlett RH & Gattinoni L (2010) Current status of extracorporeal life support (ECMO) for cardiopulmonary failure. Minerva Anestesiol,76,534-40.
3. Doll N & et al. (2004) Five-Year results of 219 consecutive patients treated with extracorporeal membrane oxygenation for refractory postoperative cardiogenic shock. Ann Thorac Surg.,77(1),151–7.
4. Finney S. J (2014) Extracorporeal support for patients with acute respiratory distress syndrome. European Respiratory Review,23,379–89.
5. Gibbon Jr JH. (1954) Application of a mechanical heart and lung apparatus to cardiac surgery. Minn Med,37(3),171–85
6. Goldstein DJ & Oz, MC (2000) Mechanical support for postcardiotomy cardiogenic shock. Semin Thorac Cardiovasc Surg,12,220– 28.
7. Hill JD & et al., (1972) Prolonged extracorporeal oxygenation for acute post-traumatic respiratory failure (shock-lung syndrome). Use of the Bramson membrane lung. N Engl J Med,286(12),629–34.
8. Knapp K & et al., (2016) Spontaneous, Postpartum Coronary Artery Dissection and Cardiogenic Shock with Extracorporeal Membrane Oxygenation Assisted Recovery in a 30-Year-Old Patient. Case Reports Cardiol., 2016,1–4.
9. Ko WJ & et al., (2002) Extracorporeal membrane oxygenation support for adult postcardiotomy cardiogenic shock. Ann Thorac Surg,73,538–45.
10. Loforte A & et al., (2011) Levitronix CentriMag third-generation magnetically levitated continuous flow pump as bridge to solution. ASAIO J,57,247–53.
11. Magovern GJ Jr & et al., (1994) Extracorporeal membrane oxygenation: preliminary results in patients with postcardiotomy cardiogenic shock. Ann Thorac Surg,57,1462–68.
12. Marasco SF & et al., (2005), Early institution of mechanical support improves outcomes in primary cardiac allograft failure. J Heart Lung Transplant,24 (12),2037-42.
13. Rastan AJ & et al., (2010)Early and late outcomes of 517 consecutive adult patients treated with extracorporeal membrane oxygenation for refractory postcardiotomy cardiogenic shock. J Thorac Cardiovasc Surg, 139,302–11.
14. Russo CF & et al., (2010) Venoarterial extracorporeal membrane oxygenation using Levitronix centrifugal pump as bridge to decision for refractory cardiogenic shock. J Thorac Cardiovasc Surg,140, 1416–21.
15. Smedira NG & et al., (2001) Clinical experience with 202 adults receiving extracorporeal membrane oxygenation for cardiac failure: survival at five years. J Thorac Cardiovasc Surg,93,92–102.
16. Smith C & et al. (2001) An extracorporeal membrane oxygenation-based approach to cardiogenic shock in an older population. Ann Thorac Surg,71,1421–27.
17. Vanzetto G & et al., (2009)Prevalence, therapeutic management and medium-term prognosis of spontaneous coronary artery dissection: results from a data base of 11,605patients. Eur J Cardiothorac Surg, 35(2),250-54.

Chapter 3

ATHERECTOMY FOR LOWER EXTREMITY INTERVENTION: WHY, WHEN, AND WHICH DEVICE?

Orhan RODOPLU[1]

INTRODUCTION:

Peripheral artery disease (PAD) is the clinical term commonly used to describe stenotic or occlusive lesions in lower extremity arteries due to atherosclerotic or thromboembolic disease. Data from the National Health and Nutrition Examination Survey (1999 to 2004) estimate a prevalence of 5.9% in patients >40 years of age, corresponding to ~7.1 million affected individuals in the U.S. (Pande & et al.,2011) and >200 million people worldwide. Despite aggressive risk factor therapies and recent improvements in medical management of atherosclerotic disease with statins and antiplatelet agents, patients with PAD frequently require invasive procedures to improve claudication symptoms and to prevent tissue loss in those with critical limb ischemia (CLI).(Golomb, Dang & Criqui, 2006)

Endovascular technological advances have made a minimally invasive percutaneous approach the treatment of choice in the initial management of the majority of symptomatic patients over the traditional surgical approach. However, the presence of severe vascular calcification, particularly in the infrainguinal vasculature, presents a significant procedural challenge to current endovascular strategies. Due to a lack of large randomized, prospective trials with independent core laboratory adjudication of device-related acute and late events, operators have used different approaches to treat femoropopliteal or infrapopliteal disease. Percutaneous transluminal angioplasty (PTA) or balloon angioplasty has been traditionally used for treatment of focal lesions. However, early elastic recoil, frequent dissections, and poor primary and secondary patency rates for long lesions, with 40-50% of cases requiring bail-out stenting, limit balloon angioplasty of "severely" calcified lesions, despite the high procedural success rates. Although the use of the last generation self-expanding nitinol stents may be an effective treatment for focal lesions, with high acute procedural success rates, restenosis rates can be as high as 10-40% at six to 24 months, and stent fractures may

[1] MD, Private Yalova Hospital, orhanrodoplu@yahoo.com.tr

occur at sites of excessive movement and flexion. Furthermore, the presence of rigid calcified plaques may result in incomplete stent expansion and significant residual stenosis.(Rocha-Singh, Zeller & Jaff,2014) Lack of effective therapy for restenosis has led many interventional cardiologists to seek alternative treatment strategies, such as plaque modification by means of debulking, using an atherectomy device.

Atherectomy is a procedure performed to remove or "debulk" the atherosclerotic plaque from diseased arteries. It is usually combined with low-pressure balloon angioplasty with the goal of minimizing plaque shift while avoiding stent placement. In densely calcified vessels, atherectomy has been used to better "prepare" the vessel prior to stenting in order to prevent incomplete and/or eccentric stent expansion.

TYPES OF ATHERECTOMY DEVICES:

There are different atherectomy devices designed to cut, shave, sand, or vaporize atherosclerotic or calcified plaques, and they have slightly different indications that depend on the lesion characteristics. Four different methods of atherectomy have been utilized for treatment of femoropopliteal or small-vessel infrapopliteal disease: plaque excision (directional) atherectomy, rotational atherectomy/aspiration, laser atheroablation, and orbital atherectomy.

1.Directional or Extractional Atherectomy Devices:

These devices utilize carbide rotating cutter disks that resect and remove the atherosclerotic plaque. They have the advantage of avoiding barotrauma, which may decrease the risk of neointimal hyperplasia and dissection. Distal embolization remains a concern with these devices, given that these devices require retrieval of removed plaque, and the use of distal protection devices may be needed, particularly in cases of heavily calcified lesions. The SilverHawk and TurboHawk (Covidien/Medtronic) plaque excision systems are the two U.S. Food and Drug Administration (FDA)-approved directional atherectomy devices in use today, with the HawkOne system recently being FDA cleared as well. The SilverHawk and TurboHawk devices come in various sizes to enable atherectomy in vessels ranging from a diameter of 1.5 mm to 7 mm. The SilverHawk plaque excision system is a forward-cutting, directional atherectomy device that consists of a rotating blade inside a tubular housing with a collection area. The TurboHawk system is similar to the SilverHawk except with a different number of inner blades, allowing for a larger luminal gain. While SilverHawk has one inner blade, TurboHawk has four contoured blades, thusavoring use in highly calcified lesions and

achieving more plaque removal per pass. As the name implies, the new HawkOne system is intended to simplify device selection, allowing treatment of lesions with different morphologies (including severe calcification) with one device.

The Determination of Effectiveness of SilverHawk Peripheral Plaque Excision [SilverHawk Device] for the Treatment of Infrainguinal Vessels/Lower Extremities (DEFINITIVE LE) study is the largest study to evaluate directional atherectomy, with enrollment of 800 patients worldwide with both claudication and/or CLI across 50 sites in the U.S. and Europe. The device success was reported at 89%, with a post-atherectomy bail-out stenting rate of 3.2%. Rates of distal embolization, dissection, and perforation were 3.8%, 2.3%, and 5.3%, respectively. At 12 months, primary patency rate in claudicants was 78%, whereas the rate of freedom from major unplanned amputation of the target limb at 12 months in CLI subjects was 95%.(McKinsey & et al.,2014)

2.Rotational Atherectomy Devices:

It is currently available as the Jetstream Atherectomy (currently Boston Scientific, previously Pathway Medical Technologies, Inc.), and the Phoenix atherectomy catheter (AtheroMed). The Boston Scientific/Pathway Jetstream Atherectomy System is a single-use catheter with a reusable, compact console power source and a front-cutting tip that allows it to go through severely stenotic lesions without predilation. It is the only atherectomy device to offer continuous aspiration and active removal of atherosclerotic debris and thrombus. Thus, this device may be particularly useful in lesions of mixed morphologies, particularly those with presence of thrombus (e.g., acute or subacute occlusions).

In a multicenter study of 172 patients, Jetstream use had a 99% device success, and six-month and 12-month clinically-driven, target-lesion revascularization rates of 15% and 26%, respectively; with a one-year restenosis rate of 38% based on duplex imaging.(Zeller & et al.,2009) The Phoenix atherectomy device is still under investigation and the Endovascular Atherectomy Safety and Effectiveness (EASE) study is currently evaluating the safety and short-term efficacy of the Phoenix device.(U.S. National Institutes of Health 2010-2014)

3.Excimer Laser Atherectomy (Spectranetics) Devices:

They use the high-energy, monochromatic light beam to alter or dissolve (vaporize) the plaque without damaging the surrounding tissue. These devices include a Turbo Elite ablation catheter as well as a Turbo-Tandem system that combines a laser guide catheter with an excimer laser atherectomy catheter.

In the Laser Angioplasty for Critical Limb Ischemia (LACI) trial, 155 critically ischemic limbs with above- or below-knee disease that were poor candidates

for surgical revascularization were treated with excimer laser-assisted intervention with a limb-salvage rate of 93% at six months.(Laird & et al.,2006)

The excimer laser has an advantage of not only debulking, but also being able to penetrate the proximal fibrous cap in chronic total occlusions. Thus, it may be advantageous for utilization when the intention is to enhance crossing capability as well as further debulk the occluded vessel. Recent results from the EXCImer Laser Randomized Controlled Study for Treatment of FemoropopliTEal In-Stent Restenosis (EXCITE ISR) trial of 250 patients demonstrated the safety and efficacy of excimer laser atherectomy in femoropopliteal in-stent restenosis. (Dippel & et al.,2015)Excimer laser plus PTA subjects demonstrated superior procedural success (93.5% vs. 82.7%; p = 0.01), with fewer procedural complications compared with PTA only (any dissection 7.7%, embolization 8.3%, bailout stenting 4.1%). In the excimer laser plus PTA versus PTA-only patients, six-month freedom from target lesion revascularization (TLR) was 73.5% versus 51.8% (p <0.005). Thus, excimer laser debulking may be particularly advantageous for recurrent in-stent restenosis lesions, given its ability to effectively remove hyperplastic tissue.

4.Orbital Atherectomy Devices:

It is an atherectomy device with an eccentrically-mounted crown that is being used to reduce the total atheroma burden and decrease the vessel-wall trauma, particularly in calcified vessels. Orbital atherectomy utilizes a diamond-coated tungsten crown that orbits 360 degrees eccentrically within the vessel, while employing circumferential plaque removal by differential sanding. The currently available orbital atherectomy devices include the CSI Stealth 360 and Diamondback 360 Orbital atherectomy systems (Cardiovascular Systems, Inc).

The CONFIRM registry series evaluated the use of orbital atherectomy in peripheral lesions of the lower extremities and showed that it effectively reduced the degree of stenosis from 88% to ~10% with the use of adjunctive low-pressure balloon angioplasty.(Das & et al.,2014) The COMPLIANCE 360° trial compared acute and 12-month results in 50 patients between orbital atherectomy plus PTA versus PTA in calcified femoropopliteal disease. (Dattilo, Himmelstein & Cuff,2014) At 12 months, freedom from TLR or restenosis was achieved in ~80% of lesions in both groups, despite rare use of bail-out stenting after atherectomy (5.3% vs. 77.8% in PTA). The peri-procedural adverse events were seen infrequently with orbital atherectomy: perforations (0%), dissections (16%), and embolization (2.6%). Given its mechanism of action, orbital atherectomy may be particularly advantageous in severely calcified lesions, while minimizing vessel wall trauma and need for bail-out stenting. Furthermore, newer low-profile (4 French) systems allow for alternative access options, such as tibiopedal approach.

Table 1. Atherectomy Devices and Where Each Device is Most Advantageous

Atherectomy Type	Directional	Rotational	Photo-Ablative	Orbital
Device	SilverHawk/ TurboHawk	Jetstream	Laser	Diamondback 360
Eccentric, focal calcification	XX			X
Thrombotic lesion		XX	X	
BTK lesion	X		X	X
Highly calcific, diffuse plaque	X			XX
In-stent restenosis			XX	
In-stent restenosis with thrombus		X	X	
Chronic total occlusion	X		XX	

CONCLUSION:

Despite different choices of atherectomy devices and advanced technologies, there have been no comparative efficacy or safety studies evaluating the four FDA-approved atherectomy devices. Atherectomy devices can reduce the burden of soft atheromatous or calcific plaque, change the vessel compliance, reduce vessel wall trauma, leading to a decrease in the need for bail-out stenting. (Feldman, 2014)

On the other hand, atherectomy devices carry significantly higher capital equipment-related costs, particularly when used in conjunction with distal protection filters, and lead to an increase in procedure duration and exposure to radiation. Given the availability of multiple atherectomy devices, in day-to-day clinical practice, it is important to initially obtain expertise with a single device, paying attention to patient/lesion selection and whether to utilize distal protection.

The recent encouraging data from drug-coated balloons (DCB) have renewed the interest in atherectomy devices, (Cioppa & et al.,2012) and several ongoing randomized trials are currently evaluating a strategy of combining atherectomy and DCB. Additional studies are required to identify subsets of patients benefiting from atherectomy and to establish an optimal, cost-effective therapy, which may include a combination of atherectomy and emerging technologies, such as drug-eluting stents, DCB, and possibly bioabsorbable stent platforms to ensure a more durable patency in complex lesions.

REFERENCES:

1. Pande, RL. & et al. (2011) Secondary prevention and mortality in peripheral artery disease: National Health and Nutrition Examination Study, 1999 to 2004.*Circulation*,124,17-23.
2. Golomb, BA. Dang, TT. & Criqui, MH. (2006) Peripheral arterial disease: morbidity and mortality implications.*Circulation,*114,688-99.
3. Rocha-Singh, KJ. Zeller, T. & Jaff, MR.(2014) Peripheral arterial calcification: prevalence, mechanism, detection, and clinical implications.*Catheter Cardiovasc Interv*, 83,E212–E220.
4. McKinsey, JF. & et al.(2014) Lower extremity revascularization using directional atherectomy: 12-month prospective results of the DEFINITIVE LE study.*JACC Cardiovasc Interv,*7,923-33.
5. Zeller, T. & et al.(2009) One-year outcome of percutaneous rotational atherectomy with aspiration in infrainguinal peripheral arterial occlusive disease: the multicenter pathway PVD trial.*J Endovasc Ther,*16,653-62.
6. U.S. National Institutes of Health 2010-2014. Endovascular Atherectomy Safety and Effectiveness Study (EASE) (ClinicalTrials.gov website). Available at:Accessed 4/12/15.
7. Laird, JR. & et al.(2006). Limb salvage following laser-assisted angioplasty for critical limb ischemia: results of the LACI multicenter trial.*J Endovasc Ther,* 13,1-11.
8. Dippel, EJ. & et al.(2015) Randomized controlled study of excimer laser atherectomy for treatment of femoropopliteal in-stent restenosis: initial results from the EXCITE ISR trial (EXCImer Laser Randomized Controlled Study for Treatment of FemoropopliTEal In-Stent Restenosis).*JACC Cardiovasc Interv,*8,92-101.
9. Das, T. & et al.(2014) Technique optimization of orbital atherectomy in calcified peripheral lesions of the lower extremities: the CONFIRM series, a prospective multicenter registry.*Catheter Cardiovasc Interv,*83,115-22.
10. Dattilo, R. Himmelstein, SI. & Cuff, RF. (2014)The COMPLIANCE 360° Trial: a randomized, prospective, multicenter, pilot study comparing acute and long-term results of orbital atherectomy to balloon angioplasty for calcified femoropopliteal disease.*J Invasive Cardiol,* 26,355-60.
11. Feldman, DN. (2014) Atherectomy for calcified femoropopliteal disease: are we making progress?*J Invasive Cardiol,*26,304-6.
12. Cioppa, A & et al. (2012) Combined treatment of heavy calcified femoropopliteal lesions using directional atherectomy and a paclitaxel coated balloon: one-year single centre clinical results.*Cardiovasc Revasc Med,*13,219-23.

Chapter 4

COMPARISON OF ENDOVASCULAR LASER ABLATION WITH NONTUMESCENT N-BUTYL CYANOACRYLATE VENA SAPHENA MAGNA ABLATION

Orhan RODOPLU[1]

INTRODUCTION:

Chronic venous insufficiency and varicose vein disease is an important venous pathology responsible for significant morbidity. It may present a series of findings including lower extremity edema, pigmentation and venous ulcers.(Bergan, Schmid-Schönbein & Smith, 2006)

Venous insufficiency treatment has changed dramatically in the last decade. Traditional methods are being introduced to modern invasive-endovenous methods and new technologies are introduced every year. Traditional methods such as ligation and stripping are associated with many complications including hematoma and paresthesia. (Almeida & *et al*., 2009) Long recovery times associated with conventional methods reduce the popularity of these methods.(Winterborn, Foy & Earnshaw, 2004) Foam sclerotherapy is the most widely used minimally invasive technique for the treatment of venous insufficiency and varicose vein disease worldwide, but high recurrence rates have been observed. (Jia & *et al*., 2007) Side effects such as air embolism, headache, pulmonary embolism and deep vein thrombosis (DVT) are the major disadvantages of this therapy. (Jia & *et al*., 2007)

Endovascular ablation techniques such as laser (EVLA) and radiofrequency ablation are widely used and proven therapies. The results are basically similar, and both reach approximately 90% of long-term success rates. (Puggioni & *et al*., 2005, Rasmussen & *et al*., 2013)Although thermal ablation has less complication compared to open surgical methods, the need for side effects such as edema, burns, pigmentation, paresthesia and the need for anesthesia are inevitable. (Puggioni & *et al*., 2005- Almeida & *et al*., 2015)

Although the current techniques are successful, the search for new innovative techniques with the goal of increasing the success rate, improving the patient's

[1] MD, Private Yalova Hospital, orhanrodoplu@yahoo.com.tr

quality of life and reducing the potential complications is rapidly increasing. A new technique for vein ablation has recently been developed, including the endovenous application of n-butyl cyanoacrylate (NBCA). and does not require the use of tumescent anesthesia. During endovenous application, NBCA rapidly solidifies and forms a rapid polymerization reaction. This reaction creates an inflammatory effect in the vessel wall that causes an ablative reaction. When injected into the vein, a compress on the vein polymerizes the polymer and closes the vessels .(Almeida & *et al*., 2013- Morrison & *et al*., 2015)

We want to present our experience with ablation method, to compare this experience with laser ablation and to present both anatomical and clinical results of our 12-month follow-up.

MATERIALS AND METHODS:

Between May 2014 and May 2017, 202 patients were initially treated with EVLA; Then, between April 2014 and August 2017, there were 166 patients treated with VVSS. The study records were examined retrospectively. Follow-up was 1 year. All patients with full follow-up were selected for comparison. 189 patients treated with NBCA endovenous application (Variclose Vein Sealing System [VVSS]; BIOLASE, Ankara, Turkey) and 150 patient treated with 1470-nm endovenous laser ablation (EVLA; Evlas Circular Fiber BIOLASE) are compared.

The primary indications for the procedures were a great saphenous vein (GSV) diameter > 5.5 mm [2 cm distal to the saphenofemoral junction (SFJ)] with venous reflux lasting> 0.5 seconds. All patients were symptomatic. No concurrent treatment of small saphenous vein or anterior accessory saphenous vein was performed. In the first evaluation, the patients' history and physical examination findings and color Doppler ultrasound (CDUS) results were recorded.

Preoperative clinical disease severity was graded according to Clinical, Etiology, Anatomy and Pathophysiology (CEAP) classification and clinical findings were evaluated by Venous Clinical Severity Score (VCSS).

Inclusion Criteria:

1. Age ≥20 years and ≤ 70 years
2. Vein diameter at the GSV ≥ 5.5mm and ≤15mm
3. Reflux in GSV > 0.5 second
4. CEAP classification between C2 and C5
5. Patients were sufficiently mentally healthy to consent to the operation

Exclusion Criteria:

1. Tortuous GSV
2. Symptomatic peripheral arterial disease history or an ABI<0.9
3. History of DVT or PE
4. Life expectancy < 2 years
5. Active thrombophlebitis in the deep or superficial veins
6. Significant femoral or popliteal venous insufficiency and perforator vein insufficiency
7. Known sensitivity to cyanoacrylate adhesives
8. Aneurysm > 15mm in the target vein
9. Previously treated GSV
10. Existence of malignant disease
11. Pregnancy
12. Immobilization.

PROCEDURAL PROTOCOLS:

Endovenous Application of NBCA:

Single-use VVSS includes 3 mL of VariClose NBCA and VariClose Delivery System (VDS). The GSV was accessed with the help of CDUS with the 6F introducer set. A 150 cm guide wire of 0.035 inch was sent from the 6F introducer sheath to the SFJ.

After the guide wire was verified with CDUS at SFJ, the 5F long introducer sheath was advanced over the guide wire to the SFJ. After confirming the position of the long introducer sheath at the beginning of SFJ, the long introducer sheath was withdrawn 6 cm from the SFJ. The sheath was withdrawn 6 cm because the tip of the 4F conduction catheter is 3 cm from the long introducer sheath. Thus, the 4F delivery catheter should be placed 3 cm distal to the SFJ. Once the location of the 4F transmission catheter has been confirmed, the NBCA injection setup is complete. A VDS gun and adapter are connected to each other and 2 mL of 3 mL of NBCA is aspirated into the syringe. The injector is connected to the gun adapter and to the end of the delivery catheter by a clamping mechanism. After the installation and positioning of the VDS was completed, the procedure was initiated. First, pressure on SFJ was performed with CDUS and the closure of SFJ was confirmed. Before the NBCA injection into the lumen of the vein, a delivery catheter was prepared. A trigger push was applied for one second to initiate the delivery catheter. After preparation, the trigger was pushed again for 5 seconds and this time the delivery catheter was withdrawn at 2 cm / s.

VDS was established for injection of 0.03 ml NBCA per centimeter. Continuous pressure was applied to the target vein segment by withdrawing the delivery catheter with the CDUS probe without releasing the pressure from the SFJ. The trigger had to be pressed every 5 seconds or 10 cm. This trigger suppression and pressure application routine was performed continuously until the target vessel segment was completely closed. After the entire vessel segment was injected with NBCA with continuous pressure during the procedure, a final pressure was applied for 30 seconds across the entire target vessel segment.

EVLA:

Disposable Biolas Evlas Circular Fiber EVLA kit consisted of 6F introducer kit and 600 mm radially extending fibers running at 1470 nm wave length. Access to GSV was achieved with the help of CDUS and 6F introducer kit. The laser fiber was advanced through the sheath up to 0.5 cm distal to the superficial epigastric vein. Confirmation of the position of the fiber was performed on the basis of both CDUS and laser beam. After confirmation, tumescent anesthesia was performed around the tissue surrounding the GSV. The thermal laser energy was applied to the 10 J / mm access point from SFJ (10 J energy per millimeter of diameter) and the device was slowly retracted. During withdrawal, pressure was applied to the vein to increase the obliteration of the vein.

Before and after the procedure, physical examination and CDUS control were performed at the first week and 6 and 12 months after the treatment. NCBA patients were mobilized immediately after treatment without compression stockings. Patients in the group of laser were prescribed class II compression stockings (thigh high) for 2 weeks after treatment.

The procedural success was defined as complete obstruction of the treated vessel segment or <5 cm of partial recanalization. Clinical improvement was assessed by comparing VCSS values before and after procedures.

SIDE EFFECTS:

Skin rash and swelling of the skin

Pain

Ecchymosis

Paresthesia

STATISTICS ANALYSIS:

SPSS Statistics was performed using Windows, version 22.0 (IBM Corp., Armonk, NY). Continuous data is presented as mean 6 standard deviation and median (minimum-maximum) values. Intergroup comparisons were made with c2 and Fisher exact tests for categorical variables. As the results of the Shapiro-Wilk test for normality showed that continuous variables were not normally distributed, the Mann-Whitney U test was used to compare groups and Wilcoxon rank total test was used for comparison between groups. P value <.05 was considered statistically significant.

RESULTS:

339 successful ablation procedures were performed for GSV deficiency. In the same session, there were no bilateral patients.The VVSS group consisted of 74 men, 76 women (total 150 patients), and the EVLA group consisted of 95 men and 94 women (total 189 patients). The mean age in the VVSS group was 45.09 ± 12 years and in the EVLA group 47.08 ± 11 years (p = .11). The mean preprocedural GSV diameters were 6.88 ± 1.80 mm in the VVSS group and 7.15 ± 1.77 mm in the EVLA group (p = 0.06).

The mean length of the ablated veins was 31.97±6.83 cm in the VVSS group and 31.65±6.25 cm in the EVLA group. The mean value of tumescent anesthesia was 300 mL (range, 60-600 mL) in the EVLA group. The mean operation time was 7 minutes in the VVSS group and 18 minutes in the EVLA group (p<.01).

Table 1. Procedure characteristics

	VVSS	EVLA	P-value
GVS diameter,mm	6.88±1.80	7.15 ± 1.77	.065
Length of the ablated GVS,cm	31.97±6.84	3.64±6.26	.974
Amount of tumescent anesthesia, ml		300 (range,60 -600)	
Procedure duration,minutes	7 (range,4 – 11)	18 (range,60- 600)	<.001
Occlusion rate	148(98.6)	184(97.3)	.659
Pre-treatment VCSS	7.53±1.03	7.73±1.58	.493
Post - treatment VCSS	2.79±1.05	2.83±1.21	.882

EVLA: endovenous laser ablation; GSV: great saphenous vein; VCSS: Venous Clinical Severity Score; VVSS: VariClose Vein Sealing System.

Table 2. Adverse events			
Group	VVSS (= 150)	EVLA (n= 189)	P value
Pain (first week)	7(4.7)	17(9.09)	.123
Burn		4(2.1)	.133
Pigmentation		11(5.9)	.002
Ecchymosis		5(2.6)	.069
Paresthesia		3(1.6)	.258
Phlebitis	3(2.1)	15(7.9)	.015
DVT		3(1.6)	.258

All of the procedures in both groups were successful and the target vessel segments were completely closed. A patient in the VVSS group experienced a partial recanalization of> 5 cm at the SFJ level. In 6 months, one patient in the VVSS group presented with a 5-cm partial recanalization in the middle of the GSV, t wo patients in the total recanalization and one patient in the EVLA group with a 5-cm partial recanalization.

Thus, the 12-month occlusion rates were 98.6% and 97.3% respectively in the VVSS and EVLA groups (P = .65). VCSS values were recorded in each follow-up and compared with the baseline values.,but there was no difference between the groups (Table 1). Adverse events were less than that of EVLA for pigmentation and phlebitis after VVSS treatment (Table 2).

The most significant side effects were pain and phlebitis in the VVSS group. Postoperative pain was observed in the first 3 days (1-3 days) at the SFJ or entry level. Patients with phlebitis recovered completely after 4 days (3-5 days).

DISCUSSION:

Intravascular use of NBCA has a history of> 20 years in venous applications in arteriovenous malformations and other parts of the body. The results of the study showed that NBCA in contact with intravascular tissue underwent a rapid polymerization reaction and began to solidify (Rasmussen & *et al*., 2013a, Almeida & *et al*., 2011). This polymerization creates an inflammation effect on the vein wall. This inflammatory effect immediately forms a tensile force which is the first stage of the polymerization process. The second stage consists of a stable tensile force, and the third stage is the last polymerization of the endothelium to which it is bound. Recent studies have reported promising results with the use of NBCA for the treatment of venous insufficiency. (Almeida & *et al*., 2013) The results also confirm previous findings regarding the use of NBCA in chronic

venous disease. (Almeida & *et al*., 2015- Proebstle & *et al*., 2015) This study showed that the complication rate after NBCA use was significantly lower than that of EVLA summarized in Table 2. EVLA complications are usually caused by thermal effects that support the use of NBCA due to the lower frequency of complications associated with this procedure.

The closure rate after NBCA was as high as that of EVLA. Recent studies have compared EVLA, ultrasonography guided foam sclerotherapy and conventional surgery for large saphenous varicosis, and after 1 year the anatomic success rate is highest after EVLA (88.5%), followed by conventional surgery (88.2%) and ultrasonography guided foam sclerotherapy (72.2%). (Rasmussen & *et al*., 2013a)

Rasmussen et al. reported that a 5-year follow-up of a randomized controlled trial comparing open surgery with EVLA in patients with GSV deficiency did not show a significant difference between the two groups at the primary or secondary end. EVLA appears to be a viable alternative to open surgery. (Rasmussen & *et al*., 2013b)

Both treatment methods showed good safety profiles. In a European multicenter cohort study, Proebstle et al reported an instant success rate of 98.6% . (Proebstle & *et al*. 2015) In a randomized study comparing NBCA and radiofrequency ablation, the NBCA closure rate was reported to be 100%, while in our study a closure rate of 98.6% was observed in 12 months follow-up. In the previous report, the application and type of NBCA were different from those used in our study. (Morrison & *et al*., 2015).

The differences between these studies included viscosity, application type and initial positioning 5 cm away from SF Junction. The product we use in this study is a low viscosity NBCA which provides immediate polymerization and provides a sealing effect every 5 seconds. This polymerization enabled rapid procedures (average NBCA administration time was 20 seconds). Since NBCA administration was continuous and rapid and non-stop, each millimeter of venous lumen was injected with a thin layer of NBCA. The combination of this application method and the low viscosity of NBCA significantly increased the success rate (98.6%) and reduced the phlebitic ratio (2%) compared to the results obtained from previous NBCA studies. It also prevented DVT and pulmonary embolism with rapid closure and minimal procedure time.

Because NBCA polymerizes very rapidly, the SFJ portion of the GSV was rapidly closed and the right amount of pressure on SFJ decreased the risk of flow of media into the deep vein. Furthermore, no heat, burn marks, pigmentation, and paresthesia occurred. The need for tumescent anesthesia is largely taken into

account for better procedure time (7 minutes for VVSS and 18 minutes for EVLA in our study) for VVSS and for patient comfort after the procedure. (Proebstle & *et al*., 2015) Postoperative pain decreased slightly compared with EVLA. In addition, the need for compression stocking did not need to improve the quality of life of patients. Morrison et al. reported that side effects were similar among these groups. No serious events or device related adverse events occurred in both groups. Device-related adverse event with cyanoacrylate embolization is mostly phlebitis. (Morrison & *et al*., 2015)

STUDY LIMITATIONS:

This study has some limitations, including the retrospective nature of the analysis of a single database, a relatively small number of patients, and the lack of objective measurements to evaluate post-traditional pain.

We also failed to stratify patients on the basis of objective measurements of the reported varicose veins or the quality of life before and after the procedure. We did not record data on the rate of disappearance of varicose veins after procedures. We focused only on the closure rates of the techniques. In addition to these limitations, our follow-up period was too short and the data on the long-term effectiveness of NBCA use is still lacking. Thus, long-term success, as compared to other treatment options such as surgery, continues to be evaluated with future studies.

CONCLUSION:

Nowadays, the minimally invasive methods available to close the defective saphenous vein require the use of thermal energy, the use of intraoperative tumescent anesthesia and postoperative compression stockings. It has been suggested that it is a suitable alternative method because it does not involve the use of tumescent anesthesia or does not require postoperative use of compression stockings and has a shorter procedure period.

REFERENCES:

1. Almeida JI & *et al*., (2009). Radiofrequency endovenous ClosureFAST versus laser ablation for the treatment of great saphenous vein reflux: a multicenter, single-blinded, randomized study (RECOVERY study). J Vasc Interv Radiol, 20, 752-59.
2. Almeida JI & *et al*.(2011) Cyanoacrylate adhesive for the closure of truncal veins: 60-day swine model results. Vasc Endovascular Surg, 45, 631-35.
3. Almeida JI & *et al*. (2013) First human use of cyanoacrylate adhesive for treatment of saphenous vein incompetence. J Vasc Surg Venous Lymphat Disord, 1,174-180.

4. Almeida JI & *et al.* (2015) Two-year follow-up of first human use of cyanoacrylate adhesive for treatment of saphenous vein incompetence. Phlebology, 30,397-404.
5. Bergan JJ, Schmid-Schönbein GW & Smith PD. (2006). Mechanism of disease: chronic venous disease. N Engl J Med, 355, 488-98.
6. Jia X & *et al. (2007*) Systematic review of foam sclerotherapy for varicose veins. Br J Surg,925-36,
7. Morrison N, & *et al*.(2015).Randomized trial comparing cyanoacrylate embolization and radiofrequency ablation for incompetent great saphenous veins (VeClose). J Vasc Surg, 61, 985-94.
8. Proebstle TM & *et al*.(2015)The European multicenter cohort study on cyanoacrylate embolization of refluxing great saphenous veins. J Vasc Surg Venous Lymphat Disord, 3, 2-7
9. Puggioni A & *et al*.(2005) Endovenous laser therapy and radiofrequency ablation of the great saphenous vein: analysis of early efficacy and complications. J Vasc Surg, 42, 488-93.
10. Rasmussen & *et al*.(2013a)Randomized clinical trial comparing endovenous laser ablation, radiofrequency ablation, foam sclerotherapy and surgical stripping for great saphenous varicose veins. J Vasc Surg Venous Lymphat Disord, 1(4),349-56.
11. Rasmussen L & *et al*., (2013b) Randomized clinical trial comparing endovenous laser ablation and stripping of the great saphenous vein with clinical and duplex outcome after 5 years, J Vasc Surg, 58, 421-26.
12. Winterborn RJ, Foy C & Earnshaw JJ (2004) C. Causes of varicose vein recurrence: late results of a randomized controlled trial of stripping of the long saphenous vein J Vasc Surg, 40, 634-39.

Chapter 5

COMPLICATIONS RELATED TO ECMO USE

Şahin İŞCAN[1]

INTRODUCTION

Extracorporeal membrane oxygenation (ECMO) is an extracorporeal life support system that can temporarily provide oxygenated blood to the body in patients with acute or chronic heart deficiency and pulmonary failure. ECMO is in use since 1971, but in recent years its use increased with technological improvements (Hill, O'Brien & Murray, 1972 and Lee, Yu & Lee, 2015).

ECMO is consisting of a pump circuit and a membrane oxygenator. It can be used in two configurations, as veno-arterial (VA) and veno-venous (VV). VV-ECMO is the main way for pulmonary recovery in patients with reversible acute respiratory failure, acute respiratory distress syndrome, failed lung transplant and pulmonary contusion. VA-ECMO is the more used configuration for cardiovascular surgery practices. It is used as bridge to recovery of heart and lungs, bridge to permanent ventricular assist device implantation, or bridge to heart transplantation for patients with heart failure. After cardiac surgery, ECMO is used to wean cardiopulmonary bypass and to provide heart recovery (Beckmann, Benk & Beyersdorf, 2011) (Table 1, 2). VA-ECMO can be implanted in peripheral or central way. In peripheral VA-ECMO, venous cannula is placed in right atrium via femoral vein via percutaneous technique. Arterial cannula is placed in femoral or axillary artery. Femoral cannulation is mostly preferred via percutaneous technique. But, axillary cannulation of arterial circuit is usually performed after a graft anastomosis to axillary artery and than cannulation of arterial cannula into the graft. In central VA-ECMO, femoral percutaneously venous cannulation, or rarely direct right atrial cannulation is used and arterial system return direct to ascending aorta or via graft anastomosis. All of these cannulation techniques bring out many complication risk (ELSO, 2013).

In some circumstances, only VA-ECMO use may not be enough to wean heart form cardiopulmonary bypass or for recovery of the heart from postcardiotomy failure. Intraaortic balloon pump can be used to decrease afterload and to im-

[1] MD., Department of Cardiovascular Surgery, Izmir Katip Celebi University, Ataturk Training and Research Hospital, sahiniscan@hotmail.com

prove left ventricle recovery with VA-ECMO. These devices may increase vascular complication rate or it may lead decrease in peripheral organ perfusion, in kidney, liver or brain according to cannulation site of arterial cannula (Ng, Yuen & Sin, 2017). Also, need to heparinization during ECMO process is the other factor which increases bleeding risk. ECMO perfusion in postcardiotomy patients causes more bleeding complications.

Table 1. ECMO indications for cardiac support (VA-ECMO)

- Postcardiotomy shock: Inability to wean from cardiopulmonary bypass
- Cardiogenic shock: Acute coronary syndrome, myocarditis, dilated cardiomyopathy, arrhythmia, cardiac depression related to multiple factors
- Bridge to permanent assist device
- Bridge to heart transplant
- Periprocedural support for high risk percutaneous cardiac interventions

Table 2. ECMO indications for pulmonary support (VV-ECMO)

- Pneumonia
- Acute respiratory distress syndrome
- Interstitial lung disease
- Pulmonary hemorrhage
- Sepsis
- Pulmonary embolism
- Aspiration syndromes
- Bridge to lung transplant
- Extracorporeal assistance for lung rest: Pulmonary
- contusion or smoke inhalation

Due to all of these risky cannulation strategies and unstable or multivariate blood perfusion technique, ECMO is one of the most risky extracorporeal circulation device for extremities, peripheral organs, brain and heart. Today, these high complication risk is not decreased its use in cardiovascular surgery practice (Table 3). In this study we wanted to present complications related to ECMO use and current tendency to decrease ECMO related complications.

BLEEDING

Bleeding is the most seen complication in patients with ECMO. There are many of studies in the literature which indicate that ECMO perfusion may cause bleeding risk between 25-60% (Khorsandi, Dougherty & Bouamra, 2017 and Pavasini, Cirillo & Campo, 2017). Cannulation sites, surgical incisions, gastrointestinal system, respiratory system, urinary tract and thoracic cavities are commonly seen bleeding areas. In cardiovascular surgery practices over anticoagulation, deficiency of coagulation factors, thrombocytopenia and surgical causes

are the main bleeding factors. Heparin is used for anticoagulation during ECMO process and activated clotting time, aPTT, PT and platelet count is used to monitorize anticoagulation level. Heparin infusion rate is titrated to maintain ACT between 160 and 220 s (Thomas & Kostousov, 2018).

Table 3. ECMO complications

Bleeding
Thrombosis
Neurologic complications (Bleeding, infarction and seizures)
Air embolism
Hemolysis
Coagulation problems
Arrhythmias, hypotension, acute pulmonary edema
Thrombus formation in left atrium and ventricle
Sepsis
Organic perfusion problems(Renal, cerebral, differential hypoxia)
Myocardial perfusion problems
Cannulation related complications(Extremity ischemia, arterial dissection, arterial and venous injury, hematoma)

Patients who need to ECMO usually have a coagulopathy risk due to patients' primary pathology and increased inflammatory process in the body. In cardiovascular surgery practices it is seen more commonly because of the effect of cardiopulmonary bypass and cross clamp process. Cardiopulmonary bypass consumes coagulation factors. Membrane oxygenator decreases platelet count and it also disrupt platelet function. Hypothermia and prolonged cardiopulmonary bypass time increase this coagulopathy by the effect of inflammation, acidosis and decreased activity of coagulation factors. In this impaired coagulation process after cardiac surgery, initiation of ECMO will increase this coagulopathy process. In a non-operated patient, coagulopathy is also immediately occurs with the initiating of ECMO. Dilutional coagulopathy and dilutional thrombocytopenia always occur starting of ECMO perfusion. Fibrinogen level decreases. During ECMO process, thrombocytopenia and platelet dysfunction continue due to physical stress into the ECMO tubing sets and ECMO oxygenator. These coagulation problems last until disconnection of ECMO (Ranucci, Baryshnikova & Cotza, 2016 and Kalbhenn, Wittau & Schmutz, 2015). In this dilution or consumption coagulopathy phase, it is needed to correct decreased levels of platelets, fibrinogen, erythrocytes and coagulation factors, by platelet aphaeresis, cryoprecipitate, red blood cell and factor solutions, respectively. The another entity complicating ECMO circulation is acquired von Willebrand syndrome which is characterized decreased von Willebrand activity or dysfunction of von Willebrand factor. It is also seen in patients with left ventricular assist device and it may frequently be

underrecognized or misdiagnosed in patients with ECMO. Acquired von Willebrand syndrome causes bleeding and it may be treated with crioprespitat transfusion or von Willebrand concentrate infusion (Thomas & Kostousov, 2018).

Postoperative surgical-site bleeding is the most important cause of morbidity and mortality in postcardiotomy patients. Cardiopulmonary bypass results in platelet and clotting factor consumption which increases the risk of clinically significant postcardiotomy hemorrhage. Surgical site bleeding risk is 30% for children and it increase to 60% for adults according to ELSO registry data. There are improvements for ECMO circuits to reduce surgical site bleeding like heparin coated tubing sets, but delaying heparin administration or reducing heparin dose in following days of ECMO perfusion are usually used treatment strategy in many centers. Replacement of platelet aphaeresis, fresh frozen plasma, cryoprecipitate and factor solutions are commonly used to prevent bleeding but these blood products also increase thrombosis risk in ECMO circuit and ECMO oxygenator. Follow-up of the patients with open sternum where the pleural and vascular structures are buffered by sponges is another follow-up method in patients with ECMO for postcardiotomy patients.

THROMBOSIS

Thrombosis is another common problem for ECMO perfusion. Tubing sets and ECMO oxygenator are the places where clotting occurs most frequently. Its incidence may increase to 19% (Makdisi & Wang, 2015). Thrombosis of venous cannula may cause ineffective venous drainage but thrombosis of arterial cannula causes embolic complications which differ according to cannulation site. Membrane oxygenator is a secure point for arterial embolic thrombi, but it is not enough when there is an ineffective anticoagulation process. Continuous peripheral micro embolism may cause skin lesions, but major embolic materials may cause organic function disturbance in liver, intestine or brain. The incidence of intracranial infarction is reported 2–5% (Sutter R, 2018). All of these complications can be seen in axillary artery, femoral artery or ascending aortic cannulation sites. Rarely, ECMO cannulae may also cause intracardiac thrombosis.

Besides of thrombosis of ECMO circuit, in vivo thrombotic complications may also be seen. Thrombotic blood products which are given to prevent bleeding like platelet aphaeresis, fresh frozen plasma or crioprestiptate may increase intravascular thrombotic risk. Therefore, it should be avoided to transfuse excessive blood product during ECMO perfusion to prevent thrombosis risk. Heparin coated ECMO circuits may be helpful to prevent thromboemboli risk but, the most important thing preventing thrombosis risk is providing adequate heparin

infusion and avoiding excessive blood transfusion. Despite all the efforts to prevent thrombus formation, ECMO termination is reported nearly one third of adult ECMO runs (Zangrillo, Landoni & Biondi-Zoccai, 2013).

NEUROLOGIC COMPLICATIONS

Neurologic complications are the most important complications which effect patient's mortality and often involve a poor prognosis for survival. According to the ELSO registry data, the incidence of neurologic complications in patients with VA-ECMO is 15% (Ng, Yuen & Sin, 2017). Intracranial hemorrhage and cerebral infarction are the mainly seen cerebral pathologies. Hypotension, hypertension, unstable blood flow, thromboembolism, thrombocytopenia and systemic heparinization are the main causes of cerebral pathologies (Lidegran, Mosskin & Ringertz, 2007). In pediatrics, carotid artery ligation increases the risk of neurologic events. Early diagnosis of neurologic problems is very important to prevent morbidity and mortality. Cranial ultrasound is a useful method for children but for adults there is limited and it is difficult due to transport process of patients to imaging laboratory. The incidence of brain death is 7.9%, cerebral infarction is 3.6%, seizure is 1.8%, and cerebral hemorrhage is 1.8% during VA-ECMO perfusion according to ELSO registry data. Hospital mortality in patients with neurologic complications increases to 89%, but in patients without neurologic complications is 57%. (Lorusso, Barili & Mauro, 2016). Incidence of neurologic complication is 7.1% in patients with VV-ECMO (Lorusso, Gelsomino & Parise, 2017).

Cannulation related neurologic complications may also be seen. In pediatrics, ligation of carotid artery may be a risk, because left carotid artery perfusion may become insufficient due to variations of circle of Willis. Variations of circle of Willis may also be a problem for adults. Axillary artery cannulation of arterial line of ECMO may cause Venturi effect from right carotid artery. This may result in right carotid perfusion problem. In patients with variations of circle of Willis this problem may cause cerebral pathologies. Abdominal aortic thrombi, abdominal aorta aneurysm or air embolisms are risk factors for neurologic pathologies in patients with femoral arterial cannulation. These risks must take into account before starting ECMO circulation.

AIR EMBOLISM

ECMO is formed as closed circuit. It is so hard forming air into the ECMO circuit. In VV-ECMO, lung is a filter to avoid systemic air embolism. But for VA-ECMO perfusion, air embolism has high morbidity and mortality. Air embo-

lism may be primary cause of neurologic and renal problems. Major air embolism into the lungs may also cause pulmonary problems.

Air embolism risk is primary related to insufficient priming of ECMO circuit. Complicated systems which contain more connectors, multiple venous drainage cannulae, ineffective venous drainage or multiple checking valves increase embolism risk. Connecting different devices to ECMO circuit like hemofiltration device may cause air in ECMO circuit and it is not a recommended approach. When air is detected in ECMO circuit, pump should be stopped. Arterial lines are clamped and air is carefully removed.

CANNULATION RELATED COMPLICATIONS

Vascular complications are the major cause of mortality in patients with ECMO. The survival in patients with vascular complications is 18%. It increases to 49% in patients who did not have vascular complications (Tanaka, Hirose & Cavarocchi, 2016). We may investigate in two parts the complications which are related to cannulation site and technique. Perforation of artery and vein, intimal dissection, extremity ischemia, bleeding from cannulation area, retroperitoneal bleeding and pseudo aneurysm are the complications which are related to cannulation area. Experienced ECMO physician and ECMO team is very important to prevent these complications risk.

In emergent situations, femoral arterial and venous approach is the gold option. But it may be hard to cannulate these patients. So, complication risk is high during cannulation process. Seldinder technique is gold standard for all vascular cannulations. Small arterial diameters, calcified arterial wall, stenosis into the arterial lumen may increase complication rate. Perforation, arterial dissection and hematoma risk is very high in these arterial pathologies and they may be seen between 7% and 14% (Roussel, Al-Attar & Alkhoder, 2012). But, limb ischemia risk is very high in patients with femoral arterial cannulation and it increase mortality. There are studies which indicate that limb ischemia risk may change between 10% and 70% (Aziz, Brehm & El-Banyosy, 2014 and Bisdas, Beutel & Warnecke, 2011). Difficult cannulation process also increases the limb ischemia risk. In all femoral arterial ECMO cannulations it is always suggested that the placement of a distal perfusion catheter. This reduces the risk of limb ischemia. It is preferred to place catheters which are larger than 5 French due to increase perfusion pressure to superficial femoral artery. Femoral arterial cannulation may also cause to differential hypoxia which is characterized poorly oxygenated blood in ascending aorta which is ejected from left ventricle. This phenomenon may also show pulmonary deficiency. Poor oxygenated blood which is ejected from

left ventricle competes with retrograde ECMO flow which comes from femoral arterial cannula. This perfusion problem causes myocardial and cerebral ischemia and it negatively effects brain oxygenation, myocardial oxygenation and myocardial recovery. So this phenomenon increase ECMO related complications and it prolongs ECMO need. Dynamic perfusion strategy according to patients' cardiac performance, delivering fully oxygenated blood to right atrium and into proximal aorta with a cannula separated from arterial ECMO cannula and as possible as avoiding femoral cannulation are methods to avoid differential hypoxia.

For femoral venous cannulation, double lumen bicaval cannula is the reliable cannula due to easy drainage of inferior vena cava, superior vena cava and right atrium. Easy venous drainage positively effects ECMO perfusion and myocardial venting. It decrease cannulation related complication risk. All of arterial and venous cannulations should be performed under fluoroscopy and confirmed with echocardiography.

Axillary artery cannulation is the other method which may prevent vascular complications, especially limb ischemia. But surgical exploration of axillary artery and vascular anastomis of a dacron graft to axillary artery have additional complication risk. Only experienced surgeon can prevent these vascular complication risks. Strict bleeding control during exploration and secure anastomosis with strong stitches facing to the brachiocephalic artery are the important points of this cannulation strategy. Today, use of axillary artery cannulation with an anastomosed graft is increasing for patients having lower extremity ischemia risk or for patients needing to long term ECMO perfusion. Axillary artery perfusion is also a good option for peripheral perfusion. It is suggested that antegrade perfusion from axillary artery, instead of retrograde perfusion using femoral artery, is more effective for kidney, intestine, liver and brain perfusion (Iscan, Cakir & Eygi, 2017 and Etz, Plestis & Kari, 2008).

The best perfusion strategy which provides physiological flow for arterial cannulation is central cannulation (Iscan, Cakir & Eygi, 2017). It is mostly preferred for postcardiotomy failure. It is provided with an anastomosed graft to ascending aorta. It is important to close mediastinum to prevent infection risk in this cannulation site and in mediastinum. In this process the sepsis risk may increase. Infection risk may increase also in recurrent mediastinal revision need due to bleeding problems. Antibiotherapy is very important for these patients. However central cannulation provides a physiologic way for body perfusion, it is also important venting the heart to increase myocardial perfusion and myocardial recovery. In the situations of ineffective myocardial discharging, myocardial oxygen need increases and myocardial recovery is affected negatively. It is not possible

to vent left ventricle with classical ECMO cannulation strategy. These problems may be solved with an intraaortic balloon pump which will decrease afterload and providing drainage of the left atrium to right atrium via septostomy. Ineffective ventricular discharge and cannula displacement may also cause intracardiac thrombosis in left ventricle or left atrium. Thromboembolism of these embolic materials cause cerebral or peripheral embolism and it will irreversibly increase patients' mortality.

HEPARIN INDUCED THROMBOCYTOPENIA

Heparin induced thrombocytopenia is an immunological complication which may occur in patients receiving ECMO. It characterized by thrombocytopenia that unfractionated heparin and low molecular weight heparin cause in 5 to 10 days of the treatment. When heparin induced thrombocytopenia is proven, heparin infusion should be stopped and it must be replaced by a non-heparin anticoagulant such as Argatroban, Bivarulidin or Fondaparinux (Makdisi & Wang, 2015 and Kawada, Kitagawa & Hoson, 2000). Heparin induced thrombocytopenia causes venous and arterial thrombosis. It is also associated with high thrombotic complications in patients' ECMO circuit. Unexpected clotting of ECMO oxygenator raises heparin induced thrombocytopenia suspicion.

RENAL COMPLICATIONS

Renal complication is commonly seen during ECMO perfusion. It increases patients' mortality and morbidity. Its incidence may change between 10-85% and mortality may rise to 51% in patients with ECMO (Hill, O'Brien & Murray, 1972 and Meuwese, Ramjankhan & Braithwaite, 2018). ECMO circulation triggers inflammatory reactions in addition to present renal deficiency due to low cardiac flow or postcardiotomy stress. Further, sepsis, capillary leak, intravascular volume depletion and nephrotoxic agents may trigger ECMO related renal deficiency. ECMO perfusion related hemolysis due to high flow and excessive blood and blood products transfusion also increase kidney injury. Renal deficiency starts with oliguric phase in 2 days and it may recover in 4 days. There are studies which indicate that ECMO related renal replacement treatment incidence may increase to 60% (Makdisi & Wang, 2015 and Kielstein, Heiden & Beutel, 2013).

REFERENCES

Aziz F, Brehm CE & El-Banyosy A. (2014) Arterial complications in patients undergoing extracorporeal membrane oxygenation via femoral cannulation. Ann Vasc Surg 28, 178-183. doi: 10.1016/j.avsg.2013.03.011

Beckmann A, Benk C & Beyersdorf F. (2011) Position article for the use of extracorporeal life support in adult patients. Eur J Cardiothorac Surg 40, 676-680. doi: 10.1016/j.ejcts.2011.05.011

Bisdas T, Beutel G & Warnecke G. (2011) Vascular complications in patients undergoing femoral cannulation for extracorporeal membrane oxygenation support. Ann Thorac Surg 92, 626-631. doi: 10.1016/j.athoracsur.2011.02.018.

ELSO (2013) ELSO adult cardiac failure supplement to the ELSO general guidelines. Version 1.3. Ann Arbor, MI: The Extracorporeal Life Support Organization.

Etz CD, Plestis KA & Kari FA. (2008) Axillary cannulation significantly improves survival and neurologic outcome after atherosclerotic aneurysm repair of the aortic root and ascending aorta. Ann Thorac Surg 86, 441-447. doi: 10.1016/j.athoracsur.2008.02.083.

Hill JD, O'Brien TG & Murray JJ. (1972) Prolonged extracorporeal oxygenation for acute post-traumatic respiratory failure (shocklung syndrome). Use of the Bramson membrane lung. N Engl J Med 286, 629–634. doi: 10.1056/NEJM197203232861204

Iscan S, Cakir H & Eygi B. (2017) Dynamic alterations in cerebral, celiac and renal flows resulting from ascending aorta, subclavian artery and femoral artery cannulations of extracorporeal devices. Perfusion. 32, 561-567. doi: 10.1177/0267659117706606.

Lee SW, Yu MY & Lee H. (2015) Risk Factors for Acute Kidney Injury and In-Hospital Mortality in Patients Receiving Extracorporeal Membrane Oxygenation. PLoS One 10, e0140674. doi: 10.1371/journal.pone.0140674.

Kalbhenn J,Wittau N & Schmutz A. (2015) Identification of acquired coagulation disorders and effects of target controlled coagulation factor substitution on the incidence and severity of spontaneous intracranial bleeding during venovenous ECMO therapy. Perfusion 30, 675–682. doi: 10.1177/0267659115579714.

Kawada T, Kitagawa H & Hoson M. (2000) Clinical application of argatroban as an alternative anticoagulant for extracorporeal circulation. Hematol Oncol Clin North Am. 14, 445-457. doi: https://doi.org/10.1016/S0889-8588(05)70144-1

Khorsandi M, Dougherty S & Bouamra O. (2017) Extracorporeal membrane oxygenation for refractory cardiogenic shock after adult cardiacsurgery: a systematic review and meta-analysis. J Cardiothorac Surg. 17 (12), 55. doi: 10.1186/s13019-017-0618-0.

Kielstein JT, Heiden AM & Beutel G. (2013) Renal function and survival in 200 patients undergoing ECMO therapy. Nephrol Dial Transplant 28, 86-90. doi: 10.1093/ndt/gfs398.

Lidegran MK, Mosskin M & Ringertz HG. (2007) Cranial CT for diagnosis of intracranial complications in adult and pediatric patients during ECMO: Clinical benefits in diagnosis and treatment. Acad Radiol 14, 62-71. doi: https://doi.org/10.1016/j.acra.2006.10.004

Lorusso R, Barili F & Mauro MD. (2016) In-Hospital Neurologic Complications in Adult Patients Undergoing Venoarterial Extracorporeal Membrane Oxygenation: Results From the Extracorporeal Life Support Organization Registry. Crit Care Med. 44, 964-

972. doi: 10.1097/CCM.0000000000001865.

Lorusso R, Gelsomino S & Parise O. (2017) Neurologic Injury in Adults Supported With Veno-Venous Extracorporeal Membrane Oxygenationfor Respiratory Failure: Findings From the Extracorporeal Life Support Organization Database. Crit Care Med. 45, 1389-1397. doi: 10.1097/CCM.0000000000002502.

Makdisi G & Wang IW. (2015) Extra Corporeal Membrane Oxygenation (ECMO) review of a lifesaving technology. J Thorac Dis. 7, 166-176. doi: 10.3978/j.issn.2072-1439.2015.07.17.

Meuwese CL, Ramjankhan FZ & Braithwaite SA. (2018) Extracorporeal life support in cardiogenic shock: indications and management in current practice. Neth Heart J 26, 58–66. doi: 10.1007/s12471-018-1073-9.

Ng GW, Yuen HJ & Sin KC. (2017) Clinical use of venoarterial extracorporeal membrane oxygenation. Hong Kong Med J 23, 282-290. doi: 10.12809/hkmj166096.

Pavasini R, Cirillo C & Campo G. (2017) Extracorporeal Circulatory Support in Acute Coronary Syndromes: A Systematic Review and Meta-Analysis. Crit Care Med. 45, 1173-1183. doi: 10.1097/CCM.0000000000002692.

Ranucci M, Baryshnikova E & Cotza M. (2016) Group for the Surgical and Clinical Outcome Research (SCORE). Coagulation monitoring in postcardiotomy ECMO: conventional tests, point-of-care, or both? Minerva Anestesiol 82, 858–866.

Roussel A, Al-Attar N & Alkhoder S. (2012) Outcomes of percutaneous femoral cannulation for venoarterial extracorporeal membrane oxygenation support. Eur Heart J Acute Cardiovasc Care 1, 111-114. doi: 10.1177/2048872612449417.

Sutter R. (2018) Acute neurologic complications during extracorporeal membrane oxygenation-a systematic review. Crit Care Med. 1, 3223.

Tanaka D, Hirose H & Cavarocchi N. (2016) The Impact of Vascular Complications on Survival of Patients on Venoarterial Extracorporeal Membrane Oxygenation. Ann Thorac Surg 101, 1729-1734. doi: 10.1016/j.athoracsur.2015.10.095.

Thomas J & Kostousov V. (2018) Bleeding and Thrombotic Complications in the Use of Extracorporeal Membrane Oxygenation. Semin Thromb Hemost. 44, 20-29. doi: 10.1055/s-0037-1606179.

Zangrillo A, Landoni G & Biondi-Zoccai G, (2013) A meta-analysis of complications and mortality of extracorporeal membrane oxygenation. Crit Care Resusc. 15, 172–178.

Chapter 6

ELECTROCARDIOGRAPHIC FINDINGS OF WIDE QRS COMPLEX TACHYCARDIAS

Alper KEPEZ[1]
Abdülkadir USLU[2]

INTRODUCTION

Twelve derivation electrocardiography (ECG) obtained both during sinus rhythm and tachycardia may give important clues about the tachycardia mechanism. Information obtained from ECG may not only be valuable for clinical diagnosis but also increase the safety and success of electrophysiological study (EPS) and ablation procedures.

Tachycardia with QRS duration <120 ms is considered to be a 'narrow QRS complex tachycardia' and tachycardia with QRS duration ≥ 120 ms is considered to be a 'wide QRS complex tachycardia' on surface ECG. Narrow QRS complex tachycardias are usually of supraventricular origin; however certain rare type ventricular tachycardias (VT) may also manifest themselves with narrow QRS on ECG. Differential diagnosis for the wide QRS complex tachycardia includes VT, aberrantly conducted supraventricular tachycardia (SVT) and preexcitation.

In this chapter wide QRS complex tachycardias will be evaluated and clues from surface ECG will be emphasized for each type of wide QRS complex tachycardia.

ELECTROCARDIOGRAPHY IN WIDE QRS COMPLEX TACHYCARDIAS

Electrocardiographic differential diagnosis of wide QRS complex tachycardias may be challanging in clinical practice . VT, SVT with aberrant conduction, preexcitation and intraventricular conduction delay should be considered in the differential diagnosis of wide QRS complex tachycardia (Alzand & Crijns, 2011). VT is the most important diagnosis due its possible association with worse prog-

[1] Assoc. Prof., Marmara University School of Medicine, Department of Cardiology, alperkepez@yahoo.com.
[2] M.D., Kartal Kosuyolu Yuksek Ihtisas Training and Research Hospital, Cardiology Clinic, dr.akadiruslu@gmail.com.

nosis. Failure to diagnose VT and administration of medications which are used for the treatment of SVT (verapamil, adenosine) may have serious consequences as ventricular fibrillation and cardiac arrest (Alzand & Crijns, 2011). Algorithms like Brugada and Vereckei have been defined to aid in differential diagnosis of VT and SVT with aberrant conduction.

Electrocardiographic Differential Diagnosis of VT and SVT With Aberrant Conduction

Brugada Criteria

The Brugada Criteria are commonly used for differentiating VT and SVT with aberrant conduction (Brugada & et al, 1991). According to these criteria first step is to examine whether there is concordance in the precordial leads from V1 to V6. If all the QRS complexes are completely upright, or completely downward in the precordial leads then the diagnosis will be VT. If there is no concordance in the precordial leads time interval from the beginning of R wave to the nadir of the S wave should be measured in the second step. An interval more than 100 ms in any precordial lead is diagnostic for VT. If this criteria is not met one should examine the presence of AV dissociation with is diagnostic of VT. If none of these criteria are present then morphology criteria should be applied.

Following morphology is diagnostic for VT if QRS is upright in lead V1 (Right bundle branch block (RBBB) pattern);

- A monophasic R or biphasic qR complex in V1
- If an RSR' pattern is present in V1, R peak being higher in amplitude than the R' peak
- rS complex in lead V6

Following morphology is diagnostic for VT if QRS is downward in lead V1 (Left bundle branch block (LBBB) pattern);

- The presence of any Q or QS wave in lead V6
- A wide R wave in lead V1 or V2 of 40 ms or more
- Slurred or notched downstroke of the S wave in V1 or V2
- Duration of onset of the QRS complex to nadir of QS or S wave > 60 ms

Failure to observe any of the above-mentioned criteria is suggestive of SVT with aberrant conduction. An example of wide QRS complex tachycardia with RBBB pattern is displayed as figure 1. Diagnosis was VT according to the morphology criteria with qR complex in V1 and rS complex in lead V6.



Figure 1. A wide QRS complex tachycardia with RBBB pattern. Note qR complex in V1 and rS complex in lead V6 which are suggestive of VT according to the morphology criteria

Vereckei Criteria

According to Vereckei criteria the most important lead for differentiating VT and SVT with aberrant conduction is lead aVR (Vereckei & et al., 2008). Any of the following in lead aVR is suggestive of VT;

- Presence of initial R wave
- Width of an initial r- or q-wave >40 ms
- Notching on the initial downstroke of a predominantly negative QRS complex
- The ratio of voltage during the initial 40 ms (Vi) and the terminal 40 ms (Vt) of QRS complex ≤ 1

An example of wide QRS complex tachycardia with LBBB pattern is displayed as figure 2. The diagnosis was VT according to the criteria proposed by Vereckei et al.

Criteria for Differentiating Preexcited SVT vs VT

It should be kept in mind that both the Brugada and Vereckei algorithms to differentiate wide QRS tachycardia have low specificity for diagnosing VT in patients with pre-excited antidromic AVRT. Brugada working group had proposed criteria for differentiating VT and pre-excited SVT (Antunes & et al. 1994). According to their criteria following findings are consistent with VT;

- The presence of predominantly negative QRS complex in leads V4–6
- The presence of a QR complex in one or more of the leads V2–6
- Atrioventricular relation different from 1:1 (more QRS complexes than P-waves)

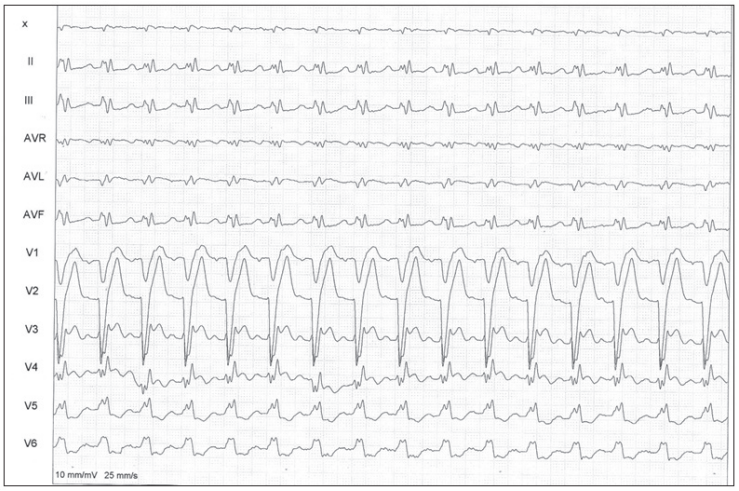

Figure 2. A wide QRS complex tachycardia with LBBB pattern. There is notching of the initial downstroke of a predominantly negative QRS complex on lead aVR and Vi/Vt is <1. These findings are suggestive of VT according to the Vereckei criteria

Electrocardiographic Findings of Various Type of VT's

Recently the mechanisms of monomorphic VT's have been more clearly elucidated and success of catheter mapping and ablation of this tachycardias has increased. Surface ECG may give important clues related with the tachycardia mechanism and localization before invasive EPS and ablation procedures.

Ventricular geometry and activation pattern determine electrocardiographic appearence of VT. Some principles are outlined as below (Haqqani, Morton & Kalman, 2009);

1. VT that originates from left ventricle free wall has right bundle branch block pattern, VT that originates from interventricular septum or right ventricle has left bundle branch block pattern.
2. VT's from septal origin have narrower QRS complex than VT's originating from other sites.
3. VT's that originate from basal region have positive precordial concordance, whereas VT's originating from apical region have negative precordial concordance.

These principles may also be applicable in the presence of structural heart disease; however, presence of prior myocardial infarction, cardiomyopathy and congenital heart disease may decrease their diagnostic value. For instance, VT originating from right ventricle in a patient with a prior history of surgery for Fallot Tetrology might have right bundle branch block pattern on surface ECG.

Idiopathic Right Ventricular Outflow Tract Ventricular Tachycardia (RVOT VT):

Idiopathic right ventricular outflow tract ventricular tachycardia (RVOT VT) is the most common type of idiopathic VT. The classical ECG findings are left bundle branch block (LBBB) configuration, inferior QRS axis on frontal plane and presence of deep negative QS complex on derivations aVL and aVR (Haqqani, Morton & Kalman, 2009). ECG findings may differ according the the region that tachycardia originates. Tachycardia orginating from septal region in the RVOT tend to have narrower QRS complex with LBBB configuration. In addition tachycardia from septal region usually has increased QRS amplitudes on inferior derivations with earlier precordial transition on the precordial leads (Positive QRS on derivation V3 or earlier) (Dixit & et al., 2003) (Figure 3). RVOT VT from free wall usually has later precordial transition, QRS complexes tend to be broader and there is notching of QRS complex on inferior derivations (Dixit & et al., 2003). However, it should be kept in mind that significantly wide QRS complex might be due to underlying structural heart disease or myocardial fibrosis. RVOT VT originating from the posterior region has positive QRS complex on derivation I due to leftward direction of activation vector (Jadonath & et al, 1995). In contrast, RVOT VT originating from anterior region may have isoelectric, negative or multiphasic QRS complex on derivation I (Dixit & et al., 2003). It has been reported that most of the RVOT VT originate in the superior RVOT within 1-2 cm of level of pulmonary valve (Haqqani, Morton & Kalman, 2009). In this situation there is negative QS complex on derivation aVL (Kamakura & et al.,1998). Isoelectric or positive QRS complex on derivation aVL may be related with a more caudal and basal location which might be close to His region (Haqqani, Morton & Kalman, 2009). Parahisian tachycardia usually has smaller R wave amplitude and narrower QRS complexes on inferior derivations and increased R wave amplitude on derivations I, V5 and V6 compared with RVOT VT (Yamauchi & et al., 2005).

VT originating from pulmonary artery usually originates from the region which is 0.5-2 cm superior to pulmonary valve and has similar ECG findings with RVOT VT (Haqqani, Morton & Kalman, 2009). However, it may display higher

R wave amplitude on inferior derivations. Pulmonary artery is slightly leftward compared to infundibulum and this anatomic difference is reflected on ECG as earlier precordial transition and deeper QS pattern in derivation aVL compared to aVR (Sekiguchi & et al., 2005).

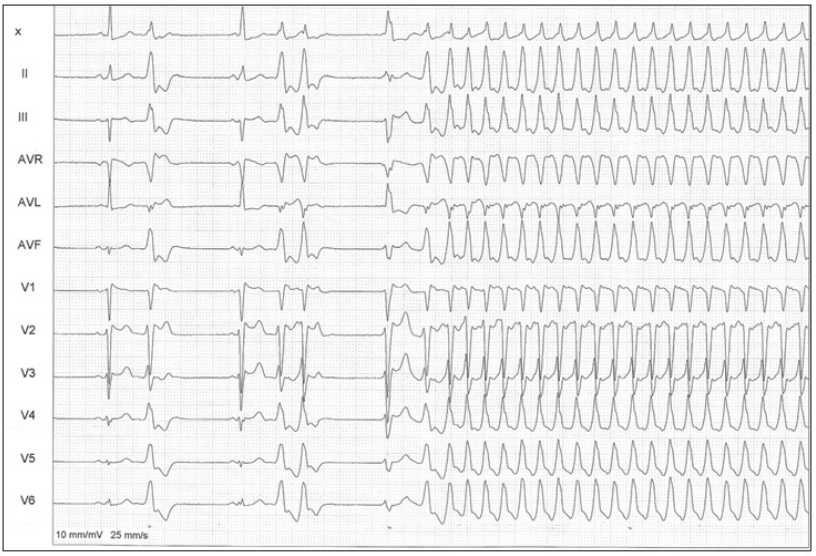

Figure 3. RVOT VT arising from posteroseptal region. Precordial transition is early (positive QRS on derivation V3) and there is positive QRS complex on lead I

Idiopathic Ventricular Tachycardia that Originates from the Aortic Sinus Valsalva Region

Ventricular tachycardia that originates from the aortic sinus valsalva region constitute approximately 21% of all idiopathic VT's in clinical practice (Tada & et al., 2005). This tachycardia is thought to be related with myocardial tissue sleeves that extend to aortic valve and sinus valsalva. VT originating from left coronary cusp is more common (Haqqani, Morton & Kalman, 2009). ECG findings of VT from the aortic sinus of valsalva are; early precordial transition, broader R waves with higher amplitude on V1 or V2 compared with RVOT VT, high amplitude R waves on inferior derivations, S wave on derivation I and absence of S wave on derivations V5 and V6 (Hachiya & et al., 2002) (Figure 4). It has been shown by pacemapping that activation from left coronary cusp produces characteristic multiphasic notching on V1('M' or 'W' patern) (Lin & et al., 2008). The cause of this finding has been suggested to be related with transseptal activation which occurs after left ventricular activation. Pacemapping from right coronary cusp in

same study produced precordial early transition, broader R waves on derivation V2 and longer mean QRS interval (Lin & et al., 2008). Derivation I has also been suggested for the differential diagnosis of VT that originates from right or left coronary cusp. VT from left coronary cusp usually displays QS or rS pattern on derivation I, however positive direction usually predominates on derivation I in VT from right coronary cusp (Haqqani, Morton & Kalman, 2009). There is no specific ECG finding of tachycardia from non-coronary cusp. Pacemapping produced atrial capture in this region due to close anatomical relationship (Lin & et al., 2008).

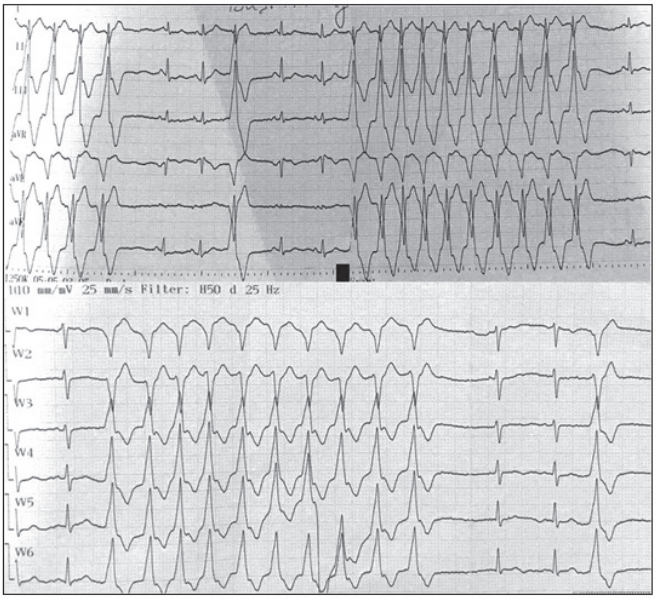

Figure 4. VT arising from left coronary cusp. Note early precordial transition, high amplitude R waves on inferior derivations, S wave on derivation I and absence of S wave on derivations V5 and V6

Idiopathic Left Ventricular Outflow Tachycardia (LVOT VT)

Precordial transition earlier than V2 is a finding of left ventricular outflow tract tachycardia (LVOT VT) (Callans & et al., 1997). Most of these tachycardias originate from anterolateral mitral annulus and usually display positive precordial concordance, right bundle branch pattern on V1 and late notching on inferior derivations (Haqqani, Morton & Kalman, 2009). Tachycardias that originate from septal site close to the His region usually display left bundle branch block pattern, dominant R wave on derivation I and left inferior axis (Haqqani, Morton & Kalman, 2009). The most discriminative ECG pattern is seen in tachycardia

that originates from aortomitral continuity and characterized by qR pattern on derivation V1. The cause of this pattern is the leftward directing of early electrical activation by fibrous trigone (Dixit & et al, 2005).

Fascicular Ventricular Tachycardia

Fascicular VT is also known as left septal VT or verapamil-sensitive VT. Patogenesis of this arrythmia is related with reentry involving structurally altered Purkinje fibers at the septal side of left ventricle. On the surface ECG, the QRS morphology in fascicular tachycardia is usually narrower and QRS duration can vary from 100 to 140 ms (Alahmad & et al, 2017). Fascicular VT has 3 types and each type has specific ECG findings. Most common type develops due to reentry involving posterior fascicle and the exit site is at inferoapical left ventricular septum. ECG findings of left posterior fascicular VT are right bundle branch block, left superior axis and RS complex on derivations V5 and V6 (Haqqani, Morton & Kalman, 2009) (Figure 5). Late precordial R waves will progressively disappear if exit site is displaced apically. Second type of fascicular VT develops due to reentry involving left anterior fascicle. ECG findings of this tachycardia is right bundle branch block pattern and right axis deviation (Alahmad & et al, 2017). The least common type of fascicular VT is upper septal fascicular VT and originates from proximal left bundle. Upper septal fascicular VT usually has narrow QRS and displays right bundle branch block pattern (may also display left bundle branch block pattern) with rightward deviated or normal axis (Alahmad & et al, 2017) (Haqqani, Morton & Kalman, 2009).



Figure 5. Posterior fascicular ventricular tachycardia. Note the presence of right bundle branch block and left superior axis. rS complex on derivations V5 and V6 is suggestive of more apically located exit of tachycardia

Post Myocardial Infarction Ventricular Tachycardia

Post myocardial VT usually develops due to scar related reentry. ECG characteristics of QRS complex during VT can be used to identify the exit site from the slow conduction path in the scarred tissue which may guide VT mapping and ablation. However, presence of extensive myocardial scars can alter the impulse propogation and may limit the accuracy of ECG for localization of VT origin (de Riva, Watanabe & Zeppenfeld, 2015). In addition subtle changes in the exit sites from scar related circuits can lead to significant alterations on surface ECG morphology (Haqqani, Morton & Kalman, 2009).

A number of ECG algorithms have been defined for predicting the site of VT origin (Miller & et al., 1988) (Kuchar, Ruskin & Garan, 1989) (Segal & et al., 2007). Each of these algorithms have limitations. Recently, Andreu et al. have described a novel QRS axis based algorithm that had accurately identified the segment of origin of VT in the 17 segment American Heart Association model in patients with structural heart disease (Andreu & et al, 2018) **(Figure 6)**. They have reported an accuracy rate of 81.9% for identification of true segment of origin of VT. A two-step evaluation was proposed for predicting the site of origin;

1- Identification of limb lead with the highest voltage magnitude (positive or negative) : If the highest magnitude is seen in leads I, II or III; the adjecent two leads should be examined for higher magnitude. The adjacent limb lead with higher magnitude will determine the group of segments where VT might originate.
2- Identification of the QRS polarity on precordial leads V3 and V4. Concordance indicate basal (both positive) or apical (both negative) origin. Other combinations indicate mid segment origin

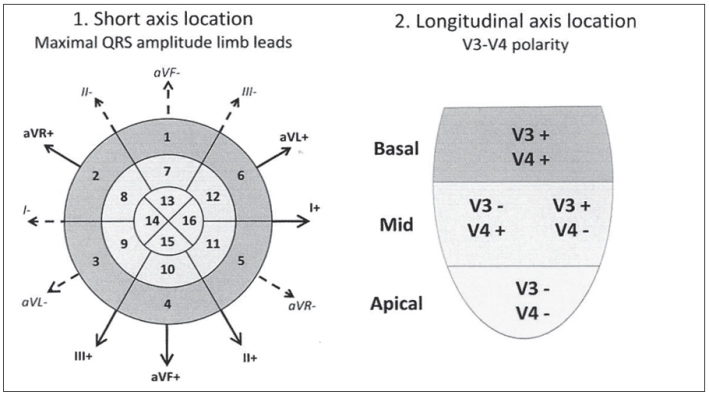

Figure 6. The QRS axis based algorithm on 17 segment American Heart Association model proposed by Andreu et al.

VT's that originate from left ventricular free wall usually have right bundle branch block pattern whereas those originating from septal region usually have left bundle branch block pattern (Haqqani, Morton & Kalman, 2009). Segment of origin analysis of two VT's are presented on figure 7 and figure 8.

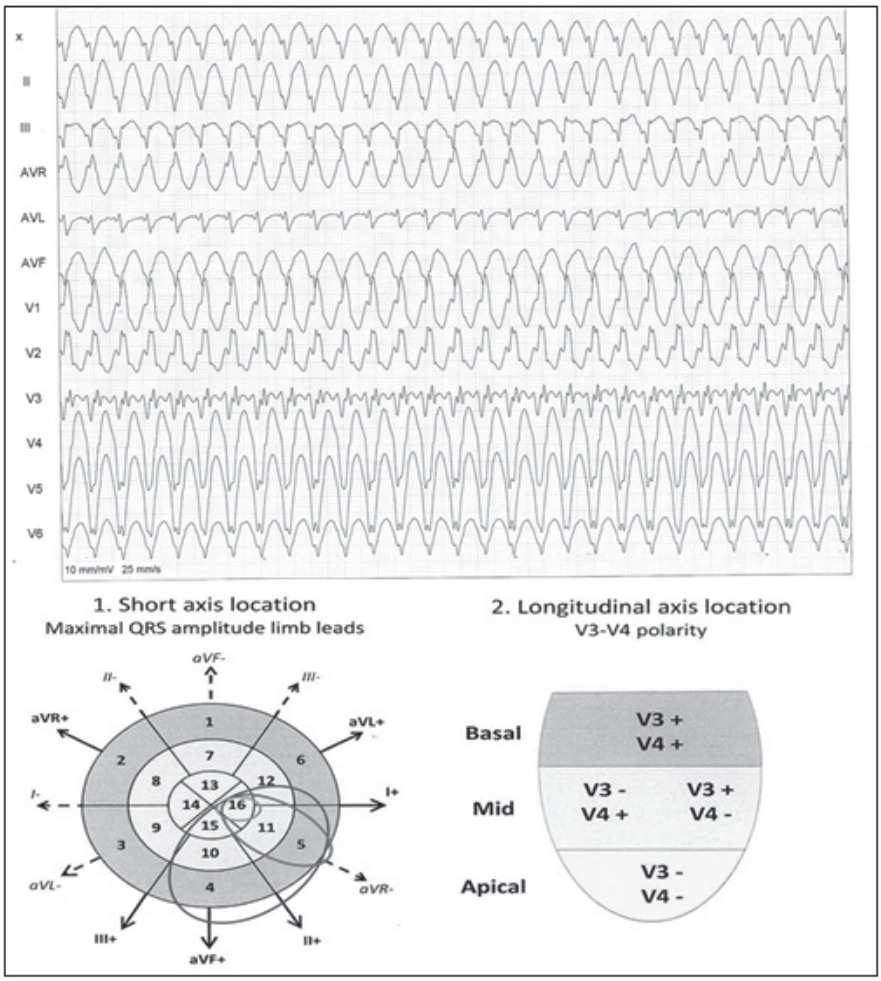

Figure 7. Scar related VT with exit site at left ventricular lateral-apical region. The lead with the highest voltage magnitude is II- (Blue circle). Next step is to examine adjacent leads aVF- an aVR +. aVR + has more voltage amplitude than aVF- (Red circle). QRS comples is both negative in leads V3 and V4 suggesing apical origin (Green circle). VT origin seems to be in segment 16 (lateral-apical region) which was confirmed with 3D electroanatomical mapping system. Right bundle branch block pattern is also consistent with LV free wall origin

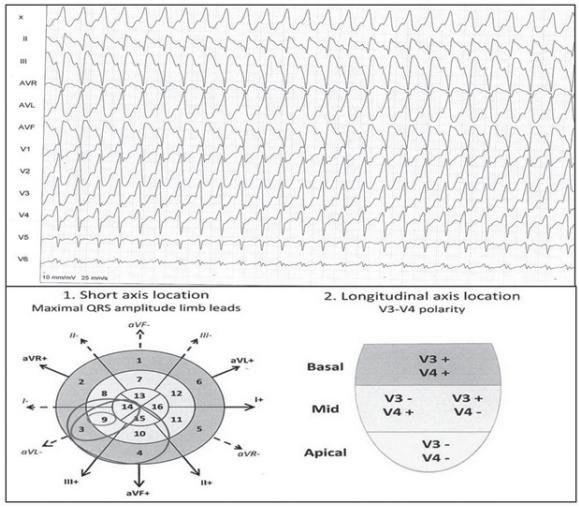

Figure 8. Scar related VT with exit site at left ventricular mid-posteroseptal region. The lead with the highest voltage magnitude is III- (Blue circle). Next step is to examine adjacent leads aVF- an aVL +. aVL + has more voltage amplitude than aVF- (Red circle). QRS complex is positive in V3 and negative in V4 suggesing mid-segment origin (Green circle).

'Bundle Branch Reentry (BBR)' Tachycardia

One of the important causes of VT in patients with non-ischemic cardiomyopathy is bundle branch reentry and related arrythmias. The diagnosis of this VT is important because curative therapy with ablation is possible. Most of the patients display right or left bundle branch block pattern on their ECG's during sinus rhythm due to presence of His-Purkinje disease. In most cases, antegrade conduction occurs through right bundle and retrograde conduction occurs through left bundle during tachycardia (Romero & et al., 2018). ECG findings of this reenterant tachycardia is left bundle branch block pattern with normal or left axis. QRS morphology during tachycardia is usually similar to that during sinus rhythm. Seldomly BBR with reverse reentry circuit may be seen; antegrade conduction occurs through left bundle and retrograde conduction occurs through right bundle. In this case right bundle branch block pattern will be seen on ECG during tachycardia (Romero & et al., 2018). In some cases,VT may originate from the distal branches of His-Purkinje system related with interfascicular reentry or increased fascicular automaticity. In this case, right bundle branch block will be seen on ECG with variable axis depending on the fascicle through which antegrade conduction occurs (Romero & et al., 2018). In addition, QRS morphology observed during tachycardia will be similar to QRS morphology in sinus rhythm.

REFERENCES

1- Alahmad Y, Assad NA, Arafa SO, Ahmad Khan SH, Mahmoud A. (2017). Idiopathic fascicular left ventricular tachycardia. *Heart Views 18* (3): 83-87. doi: 10.4103/HEARTVIEWS.HEARTVIEWS_145_15.

2- Alzand BS, Crijns HJ. (2011). Diagnostic criteria of broad QRS complex tachycardia: decades of evolution. *Europace 13* (4): 465-472. doi: 10.1093/europace/euq430

3- Andreu D, Fernández-Armenta J, Acosta J, Penela D, Jáuregui B, Soto-Iglesias D, Syrovnev V, Arbelo E, Tolosana JM, Berruezo A. (2018). A QRS axis-based algorithm to identify the origin of scar-related ventricular tachycardia in the 17-segment American Heart Association model. *Heart Rhythm 15* (10): 1491-1497. doi: 10.1016/j.hrthm.2018.06.013

4- Antunes E, Brugada J, Steurer G, Andries E, Brugada P. (1994). The differential diagnosis of a regular tachycardia with a wide QRS complex on the 12-lead ECG: ventricular tachycardia. supraventricular tachycardia with aberrant conduction and supraventricular tachycardia with anterograde conduction over an accessory pathway. *PACE 17* (9): 1515–1524.

5- Brugada P, Brugada J, Mont L, Smeets J, Andries EW. (1991). A new approach to the differential diagnosis of a regular tachycardia with a wide QRS complex. *Circulation 83* (5): 1649–1659.

6- Callans DJ, Menz V, Schwartzman D, Gottlieb CD, Marchlinski FE. (1997) Repetitive monomorphic tachycardia from the left ventricular outflow tract: Electrocardiographic patterns consistent with a left ventricular site of origin. *J Am Coll Cardiol 29* (5): 1023-1027.

7- de Riva M, Watanabe M, Zeppenfeld K. (2015). Twelve-lead ECG of ventricular tachycardia in structural heart disease. *Circ Arrhythm Electrophysiol 8* (4): 951–962. doi: 10.1161/CIRCEP.115.002847.

8- Dixit S, Gerstenfeld EP, Callans DJ, Marchlinski FE. (2003). Electrocardiographic patterns of superior right ventricular outflow tract tachycardias: Distinguishing septal and free-wall sites of origin. *J Cardiovasc Electrophysiol 14* (1) : 1-7.

9- Dixit S, Gerstenfeld EP, Lin D, Callans DJ, Hsia HH, Nayak HM, Zado E, Marchlinski FE. (2005). Identification of distinct electrocardiographic patterns from the basal left ventricle: Distinguishing medial and lateral sites of origin in patients with idiopathic ventricular tachycardia. *Heart Rhythm 2* (5): 485-491. doi: 10.1016/j.hrthm.2005.01.023.

10- Hachiya H, Aonuma K, Yamauchi Y, Igawa M, Nogami A, Iesaka Y. (2002) How to diagnose, locate, and ablate coronary cusp ventricular tachycardia. *J Cardiovasc Electrophysiol 13* (6): 551-556.

11- Haqqani HM, Morton JB, Kalman JM. (2009) Using the 12-lead ECG to localize the origin of atrial and ventricular tachycardias: Part 2. Ventricular tachycardia. *J Cardiovasc Electrophysiol 20* (7): 825-832. doi: 10.1111/j.1540-8167.2009.01462.x.

12- Jadonath RL, Schwartzman DS, Preminger MW, Gottlieb CD, Marchlinski FE. (1995). Utility of the 12-lead electrocardiogram in localizing the origin of right ventricular outflow tract tachycardia. *Am Heart J 130* (5):1107-1113.

13- Kamakura S, Shimizu W, Matsuo K, Taguchi A, Suyama K, Kurita T, Aihara N, Ohe T, Shimomura K. (1998). Localization of optimal ablation site of idiopathic ventricular tachycardia from right and left ventricular outflow tract by body surface ECG. *Circulation 98* (15):1525-1533.

14- Kuchar DL, Ruskin JN, Garan H. (1989) Electrocardiographic localization of the site of origin of ventricular tachycardia in patients with prior myocardial infarction. *J Am Coll Cardiol 13* (4): 893–903.
15- Lin D, Ilkhanoff L, Gerstenfeld E, Dixit S, Beldner S, Bala R, Garcia F, Callans D, Marchlinski FE. (2008). Twelve-lead electrocardiographic characteristics of the aortic cusp region guided by intracardiac echocardiography and electroanatomic mapping. *Heart Rhythm 5* (5) :663-669. doi: 10.1016/j.hrthm.2008.02.009.
16- Miller JM, Marchlinski FE, Buxton AE, Josephson ME. (1988). Relationship between the 12-lead electrocardiogram during ventricular tachycardia and endocardial site of origin in patients with coronary artery disease. *Circulation 77* (4):759–766.
17- Romero J, Santangeli P, Pathak RK, Grushko M, Briceno D, Cerrud-Rodriguez R, Quispe R, Grupposo V, Di Biase L. (2018). Bundle branch reentrant ventricular tachycardia: review and case presentation. *J Interv Card Electrophysiol 52* (3): 385-393. doi: 10.1007/s10840-018-0434-z.
18- Segal OR, Chow AW, Wong T, Trevisi N, Lowe MD, Davies DW, Della Bella P, Packer DL, Peters NS. (2007). A novel algorithm for determining endocardial VT exit site from 12-lead surface ECG characteristics in human, infarct-related ventricular tachycardia. *J Cardiovasc Electrophysiol 18* (2):161–168. doi: 10.1111/j.1540-8167.2007.00721.x.
19- Sekiguchi Y, Aonuma K, Takahashi A, Yamauchi Y, Hachiya H, Yokoyama Y, Iesaka Y, Isobe M. (2005). Electrocardiographic and electrophysiologic characteristics of ventricular tachycardia originating within the pulmonary artery. *J Am Coll Cardiol 45* (6): 887-895. doi: 10.1016/j.jacc.2004.10.071.
20- Tada H, Ito S, Naito S, Kurosaki K, Kubota S, Sugiyasu A, Tsuchiya T, Miyaji K, Yamada M, Kutsumi Y, Oshima S, Nogami A, Taniguchi K. (2005). Idiopathic ventricular arrhythmia arising from the mitral annulus: A distinct subgroup of idiopathic ventricular arrhythmias. *J Am Coll Cardiol 45* (6): 877-886. doi: 10.1016/j.jacc.2004.12.025.
21- Vereckei A, Duray G, Szénási G, Altemose GT, Miller JM. (2008). A new algorithm using only lead aVR for the differential diagnosis of wide QRS complex tachycardia. *Heart Rhythm 5* (1): 89–98. doi: 10.1016/j.hrthm.2007.09.020.
22- Yamauchi Y, Aonuma K, Takahashi A, Sekiguchi Y, Hachiya H, Yokoyama Y, Kumagai K, Nogami A, Iesaka Y, Isobe M. (2005). Electrocardiographic characteristics of repetitive monomorphic right ventricular tachycardia originating near the His-bundle. *J Cardiovasc Electrophysiol 16* (10): 1041-1048. doi: 10.1111/j.1540-8167.2005.40787.x.

Chapter 7

CARDIOPLEGIA METHODS FROM PAST TILL PRESENT

Ayşe LAFÇI[1]
Derya GÖKÇINAR[2]

INTRODUCTION

All cardiac surgical interventions are associated with varying degrees of myocardial injury. This is one of the major causes of postoperative mortality and morbidity, and may be a reason for surgical failure. Various methods have been developed for myocardial protection in arrested heart. The procedure in which cardiac pump and pulmonary gas exchange functions are undertaken by the heart-lung machine during cardiac surgery is called as "cardiopulmonary bypass" (CPBP) or "extracorporeal circulation". It is important to sustain cardiac arrest and maintain a blood-free surgical field in the interventions where this procedure is performed. Cardioplegia is a temporary cessation of myocardial contractions during CPBP, which is performed through administration of cardioplegic solutions, an important tool for myocardial protection (Buckberg & Athanasuleas, 2016). Cardiac arrest with cardioplegic solutions is also called pharmacological arrest.

History of cardioplegic solutions

Sealy et al., who worked on elective cardiac arrest in the 1950s, applied cardioplegia with a solution containing potassium, magnesium, and neostigmine (Sealy et al., 1958). Cardiac arrest solutions were continued to develop and used in open heart surgery in the 1960s (Holscher, Just & Mercker, 1961; Bretschneider, 1964). In the 1970s, Kirsch et al. published their clinical study on cardioplegia (Kirsch, Rodenwald & Kalmar, 1972). In San Francisco, Benson Roe et al., reported safe cardioplegia by the "cold Ringer's solution" which contained 20 mEq of potassium (Roe et al., 1977). In the 1970s, Bretschneider's solution was first used as organ protection solution and then used to provide cardiac arrest in

[1] M.D., Department of Anesthesiology and Reanimation, Ankara Numune Training and Research Hospital, University of Health Sciences, Ankara, Turkey, ayselafci971@gmail.com
[2] M.D., Assoc. Prof., Department of Anesthesiology and Reanimation, Ankara Numune Training and Research Hospital, University of Health Sciences, Ankara, Turkey, deryaozgurgokcinar@gmail.com

cardiac surgery. Hearse et al. reported to develop St. Thomas cardioplegia solution (Hearse, Stewart, & Braimbridge, 1976). In 1978, Follette et al. published a study on mixture of blood cardioplegic which was reported to reduce post-ischemic myocardial injury (Follette et al., 1978). In the 1990s, Pedro del Nido developed a cardioplegia solution, del Nido cardioplegic solution, to be used in neonatal and pediatric cardiac surgery (Matte & del Nido, 2012).

The mode of action of cardioplegic solutions

Cardioplegic solutions have been developed for various purposes in the form of a wide variety of solutions. The main purpose of using cardioplegia solution is to diminish the energy demand during ischemia and establish a rapid arrest. Some cardioplegic solutions inhibit the recurrence of electrical activity by their hypothermic properties. These contain the buffering systems required during the hypothermia and provide the substrate for sustained energy production. These solutions are hyperosmolar to reduce edema. In addition, they prevent hypocalcemia and have membrane-stabilizing properties (Hearse, Garlic & Humphrey, 1977; Corr, Gross & Sobel, 1984).

It is important to protect the myocardium in open heart surgeries using CPBP method. Prevention of intracellular acidosis and reperfusion injury as well as the reduction of cellular metabolic demands allow the protection of the myocardium. Cardioplegic solutions act by altering the ion balance intracellularly or extracellularly. Intraoperatively, intracellular calcium accumulation occurs during the ischemic period. During reperfusion, hypercontractility occurs in cardiac myocytes due to post-ischemic calcium overload. This leads to irreversible damage and death in the cytoskeletal components. Solutions that contain polarizing agents such as magnesium and lidocaine slow the rate of energy consumption and reduce intracellular calcium accumulation. Stable arrest of cardiac myocytes can thus be achieved during cardiac arrest (Sorabella et al., 2014).

The addition of mannitol to cardioplegic solutions contributes to the scavenging of free radicals and the reduction of myocardial edema. The mechanism for providing myocardial protection by adding varying amounts of red blood cells to cardioplegia is controversial. Warm blood cardioplegic solution also helps to prevent reperfusion injury. Sodium bicarbonate added to cardioplegia helps maintain intracellular pH. del Nido cardioplegia (dNC), owing to its administration in single dose and small volume, could be regarded as advantageous compared to other cardioplegic techniques, as such properties offered efficacious protection and long-lasting surgery time (Yerebakan et al., 2014). dNC promotes glycemic control as it is not a dextrose-based solution (Kim et al., 2014).

Histidine tryptophan ketoglutarate (HTK) Bretschneider's solution is an intracellular crystalloid cardioplegic. It arrests the heart by decreasing extracellular sodium and calcium concentrations up to near intracellular levels. Diminished calcium concentrations reduce cardiac electromechanical activity and prevents its re-initiation. On the other hand, low sodium concentration provides rapid cardiac arrest. Histidine in HTK solution is an important buffer system. This amino acid can not enter the cell. This buffer system and the additional anti-osmotic effect of mannitol provide myocardial protection. It acts as a substrate for aerobic energy production during arresting and then recovering of the heart. Numerous cardioplegic solutions and protocol combinations have been developed based on these various mechanisms. Compositions of cardioplegic solutions were provided in the Table 1 (Chambers & Hearse, 1999).

Table 1. Composition of cardioplegic solutions

	STC	BC	dNC	HTK
Formulation		Mixed 4:1 BC	Plasma-Lyte A	
Total volume	1000 mL	1000 mL	1000 mL	1000 mL
Additive				
Mannitol	30 mmol L–1	10 g	3.26 g	30 mmol L–1
Dextrose	10g/L			
Potassium	16 mmol L–1	46 mEq	26 mEq	10 mmol L–1
Magnesium	16 mmol L–1	2.5 g	2 g	4 mmol L–1
Lidocaine		40 mg	130 mg	
Sodium Bicarbonate	22.5 mmol L–1	1 mEq	13 mEq	
Sodium	110 mmol L–1			15 mmol L–1
Calcium	1.2 mmol L–1			0.02 mmol L–1
Ketoglutarate				1 mmol L–1
Tryptophan				2 mmol L–1
Histidine				180mmol L–1
Osmolality	281 mOsm/L			330 mOsm/L

STC: St. Thomas cardioplegic solution; **BC:** blood cardioplegia; **dNC:** del Nido cardioplegia; **HTK:** Histidine tryptophan ketoglutarate(Bretschneider's) solution

Major cardioplegic solutions used in cardiac surgery

St Thomas Cardioplegia Solution

Crystalloid cardioplegics offer effective myocardial protection at low cost (Hendry, Masters & Haspect, 1994). St. Thomas cardioplegia has been widely

used worldwide throughout the 1980s and 1990s (Bilfinger et al., 1992). It serves as a buffer in ischemia and reperfusion periods, regulates electrolytes, and meet substrate needs of the myocardium. In addition, it reduces myocardial edema with low sodium content and hyperosmolar property of mannitol. Its lower viscosity was suggested to provide rapid cardiac arrest. The potassium in the solution allows the heart to be arrested in the diastole and reduces ventricular fibrillation (Koller, Riccio & Amp; Gilmour Jr., 2000). As an easy to use method, crystalloid cardioplegia can be delivered by anterograde or retrograde route.

Blood cardioplegia

Several studies reported that blood cardioplegia provided better myocardial protection (Verma et al., 2002). It was reported as more physiological owing to its oxygen-carrying and buffering capacity, electrolyte content, an osmolarity near to that of the body. Administration of warm blood cardioplegia just prior to aortic clamp removal provided rapid improvement in enzymatic and metabolic functions to reduce reperfusion injury and increased myocardial oxygen utilization. Blood cardioplegia was reported to be associated with better protection in patients with prolonged cross-clamp time, and especially with low ejection fraction. It may be administered as warm or cold; as anterograde or retrograde; and continuously or intermittently (Teoh et al., 1986).

Del Nido cardioplegia

Del Nido cardioplegia solution was first designated for use in the pediatric patient group. This cardioplegia is usually given as a single dose of 20 mL/kg in anterograde fashion. In addition to reducing the energy consumption of the myocardium, it prevents cellular calcium influx, preserves high-energy phosphates, and promotes anaerobic glycolysis during arrest. Charette et al. reported no difference in postoperative complications between those who received single dose del Nido cardioplegia and those receiving multi-dose cardioplegia strategies (Charette et al., 2012). In addition to pediatric cases, the use of del Nido cardioplegia has been increasing in adult cardiac surgery, especially in recent years.

Histidine tryptophan ketoglutarate (Bretschneider's) solution

It was first developed in the 1970s by Bretschneider et al. for organ-protective purposes. As an intracellular solution, HTK prevents myocardial contraction by removing the sodium gradient between intracellular and extracellular compartments. In 1975, it was used for establishing cardiac arrest in 100 cardiac surgery cases; and found to provide up to 100 minutes of arrest with good clinical outcomes (Bretschneider HJ et al., 1975). While histidine component of the solution

serves as the buffer, tryptophan provides membrane stabilization. Ketogluterate was reported to prevent ischemia-reperfusion injury by providing high energy production via ATP during reperfusion. The anti-edema property of mannitol also helps to reduce myocardial edema. Today, HTK solution could protect the myocardium by providing cardiac arrest for 90, 120, or 180 minutes during heart surgery (Edelman et al., 2013). It may be used both in anterograde and retrograde fashion. It is still most costly cardioplegic solution.

Conclusion

While cardioplegic solutions are useful for myocardial protection, controversies still exist about its composition, warmth, and way of administration. Different institutions use various cardioplegic solutions. New large-sized randomized controlled trials are needed to demonstrate evidence-based methods that provides effective myocardial protection.

REFERENCES

Bilfinger T.V., Moeller J.T., Kurusz M., Grimson R.C. & Anagnostopoulos C.E. (1992). Pediatric myocardial protection in the United States: A survey of current clinical practice. Thorac Cardiovasc Surg 40:214–218.

Bretschneider H.J. (1964). Uberlebenszeit und Weider-Belbungxzeit des Herzens bet normo und Hypothermic. Verh Dtsch Ges Kreisl-Forsh 30:11-34.

Bretschneider H.J., Hübner G., Knoll D., Lohr B., Nordbeck H. & Spieckermann P.G. (1975). Myocardial resistance and tolerance to ischemia: physiological and biochemical basis. J Cardiovasc Surg 16(3):241-60.

Buckberg G.D. & Athanasuleas C.L. (2016). Cardioplegia: solution or strategies? Eur J Cardiothorac Surg 50:787-91.

Chambers D.J. & Hearse D.J. (1999). Developments in cardioprotection: Polarized arrest as an alternative to depolarized arrest. Ann Thorac Surg 68:1960–1966.

Charette K., Gerrah R., Quaegebeur J., Chen J., Riley D., Mongero L., Corda R. & Bacha E. (2012). Single dose myocardial protection utilizing del Nido cardioplegia solution during congenital heart surgery procedures. Perfusion 27:98–103.

Corr P.B., Gross R.W. & Sobel B.E. (1984). Amphipathic metabolites and membrane dysfunction in ischemic myocardium. Circ Res 55: 135.

Edelman J.J., Seco M., Dunne B., Matzelle S.J., Murphy M., Joshi P., Yan T.D., Wilson M.K., Bannon P.G., Vallely M.P. & Passage J. (2013). Custodiol for myocardial protection and preservation. A systematic review. Ann Cardiothorac Surg 2(6):717-728. doi: 10.3978/j.issn.2225-319X.2013.11.10

Follette D.M., Fey K.H., Steed D.L., Foglia R.P. & Buckberg GD. (1978). Reducing reperfusion injury with hypocalcemic, hyperkalemic, alkalotic blood during reoxygenation. Surg Forum 29:284-6.

Hearse D.J., Stewart D.A. & Braimbridge M.V. (1976). Cellular protection during myocardial ischemia: the development and characterization of a procedure for the induction of reversible ischemic arrest. Circulation 54:193-202.

Hearse D.J., Garlick P.B. & Humprey S.M. (1977). Ischemic contracture of the myocardium: Mechanisms and prevention. Am J Cardiol 39:993.

Hendry P.J., Masters R.G. & Haspect A. (1994). Is There a Place for Cold Crystalloid Cardioplegia in the 1990s? Annals of Thoracic Surgery 58:1690-1694.

Holscher B., Just O.H. & Mercker A.J. (1961). Studies by electron microscope on various forms of induced cardiac arrest in dog and rabbit. Surgery 49:492-9.

Kirsch U., Rodenwald C. & Kalmar P. (1972). Induced ischemic arrest: clinical experience with cardioplegia in open heart surgery. J Thorac Cardiovasc Surg 63:121-30.

Koller M.L., Riccio M.L. & Gilmour Jr. R.F. (2000). Effects of (K) on Electrical Restitution and Activation Dynamics during Ventricular Fibrillation. *The American Journal of Physiology*: *Heart and Circulatory Physiology* 279:H2665-H2672.

Kim K., Ball C., Grady P. & Mick S. (2014). Use of del Nido Cardioplegia for adult cardiac surgery at the cleveland clinic: perfusion implications. J Extra Corpor Technol 46(4): 317–323.

Matte G.S. & del Nido P.J. (2013). History and use of del Nido cardioplegia solution at Boston Children's Hospital. J Extra Corpor Technol 2012 Sep;44(3):98-103. Erratum in: J Extra Corpor Technol 45(4):262.

Roe B.B., Hutchinson J.C., Fishman N.H., Ullyot D.J. & Smith D.L. (1977). Myocardial protection with cold, ischemic, potassiuminduced cardioplegia. J Thorac Cardiovasc Surg 73: 366 -74.

Sealy W.C., Young W.G. Jr., Brown I.W. Jr., Lesage A., Callaway H.A. Jr., Harris J.S. & Merritt D.H. (1958). Potassium, magnesium and neostigmine for controlled cardioplegia; studies on the deg using extracorporeal circulation and hypothermia. AMA Arch Surg 77(1):33-38.

Sorabella R.A., Akashi H., Yerebakan H., Najjar M., Mannan A., Williams M.R., Smith C.R. & George I.J. (2014). Myocardial protection using del nido cardioplegia solution in adult reoperative aortic valve surgery. Card Surg 29(4):445-9. doi: 10.1111/jocs.12360.

Teoh K.H., Christakis G.T., Weisel R.D., Fremes S.E., Mickle D.A., Romaschin A.D., Harding R.S., Ivanov J., Madonik M.M., Ross I.M., et al. (1986). Accelerated myocardial metabolic recovery with terminal warm blood cardioplegia. J Thorac Cardiovasc Surg 91:888-895.

Yerebakan H., Sorabella R.A., Najjar M., Castillero E., Mongero L., Beck J., Hossain M., Takayama H., Williams M.R., Naka Y., Argenziano M., Bacha E., Smith C.R. & George I. (2014) J.Del Nido Cardioplegia can be safely administered in high-risk coronary artery bypass grafting surgery after acute myocardial infarction: a propensity matched comparison. Cardiothorac Surg Oct 30;9:141.

Verma S., Fedak P.W., Weisel R.D., Butany J., Rao V., Maitland A., Li R.K., Dhillon B. & Yau T.M. (2002). Fundamentals of reperfusion injury for the clinical cardiologist. Circulation 100:2332-2336.

Chapter 8

EPICARDIAL ADIPOSE TISSUE: FROM CELL TO BED SIDE

Murat ZİYREK[1]

Adipose tissue is a type of loose connective tissue composed mostly of adipocytes. Apart from adipocytes periadipocytes, fibroblasts, macrophages, and endothelial cells are also present in the stromal vascular fraction of adipose tissue. In recent years adipose tissue has been recognized as a major endocrine organ secreting various types of cytokines having both paracrine and endocrine effect (Kershaw & Flier, 2004)1. In the human body, localization of adipose tissue might be: beneath the skin (subcutaneous adipose tissue), around the viscera (visceral adipose tissue), in yellow bone marrow, and in breast tissue. Of all these, visceral adipose tissue (also known as organ specific fat) has the greater detrimental effect on metabolic health. Visceral adipose tissue is located in the abdominal cavity, packed between the organs. Excess visceral fat is clinically known as abdominal obesity. Besides, excess visceral fat is also known to be associated with type 2 diabetes mellitus (Montague & Rahilly, 2000)2, insulin resistance (Kern & et al, 2001)3, and inflammatory diseases (Marette, 2003)4. That' s why visceral adipose tissue attracts considerable attention. Epicardial adipose tissue (EAT) is a particular form of visceral adipose tissue which shares the same embryologic origin of omental and mesenteric fat (Talman & et al, 2014)5. Like visceral adipose tissue closely packing the abdominal organs, EAT also encases coronary arteries with no fascial barrier (figure 1). Consequently, it has been postulated that EAT may display endocrine or paracrine effects on the adjacent arterial wall to influence atherosclerotic process (Nitesh & et al, 2017)6.

The objective of this review is to explore EAT from cell to the bedside.

ANATOMICAL ASPECT:

The pericardium is composed of visceral and parietal layers. The fibrous (parietal) pericardium is a resilient sac that surrounds the heart and attaches onto the great vessels (Edwrads, 1984)7. On the other hand, the serious pericardium forms

[1] Cardiologist. Sağlık Bilimleri University Konya Education and Research Hospital Dep. of Cardiology, muziyrek@yahoo.com

the delicate inner lining of the fibrous pericardium as well as the outer lining of the heart and great vessels (visceral pericardium). Over the heart, it is referred to as the epicardium. Epicardium contains the epicardial coronary arteries and veins, autonomic nerves, lymphatics, and a variable amount of EAT. EAT mainly concentrated in the atrioventricular and interventricular grooves and along the major branches of the coronary arteries, and to a lesser extent around the atria, over the free wall of the right ventricle and over the apex of the left ventricle (Icobellis,Corradi & Sharma, 2005)8. Amount of EAT varies with increasing age and obesity (Edwards, 1995)9.

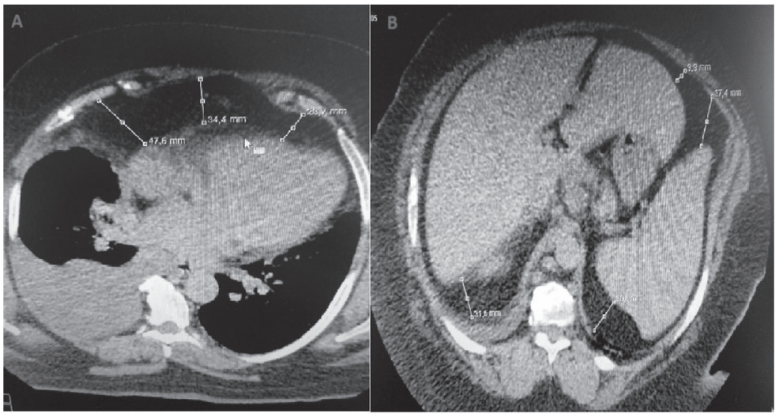

Figure 1. Thorax and abdomen CT scan images of a morbidly obese patient. In figure A EAT thickness measured. In figure B perihepatic and perisplenic visceral adipose tissue thickness measured. As they have same mesenchymal and embryological origin, radiodensity of both tissues is similar. Also, note a large amount of subcutaneous adipose tissue.

CELLULAR ASPECT:

For centuries, scientists have investigated the biology and possible role on cardiac health of EAT. As we mentioned before, EAT lies underneath the epicardium. EAT is present human as early as the fetal life (Jornet & et al, 1990)10. During early embryonic life, epicardial cells migrate and spread over the heart surface to form epicardium (Viragh & Challice, 1981)11. Once formed, epicardium secretes various cytokines that influence the mitogenic expansion of the ventricular myocardium and organization of the coronary vessels (Sucov & et al, 2009)12. Another important property, because epicardial cells are multipotent progenitor cells (Riley, 2012)13, they also transform to generate mesenchymal cells. At first, these mesenchymal cells localize between epicardium and myocardium. One subset of these cells assembles around nascent coronary endothelial

tubes and constitutes the smooth muscle layer of the mature coronary vessels. A separate subpopulation migrates as single cells into the myocardium and becomes the predominant source of cardiac fibroblasts that secrete extracellular matrix needed for mature heart structure (Acharya & et al, 2012)14. Besides, epicardium-derived mesenchyme also underwent adipogenic differentiation to form EAT (Yamaguchia & et al, 2015)15.

Adipose tissue is composed of adipocytes and stromal vascular fraction which contains various types of cells like preadipocytes, fibroblasts, endothelial cells and immune cells (Lucas, Verwaerde & Wolowczuk, 2009)16. Both adipocytes and stroma vascular fraction cells contribute in adipokine secretion. Adipokines secreted from adipose tissue are listed in table 1.

Table 1. Adipokines secreted from tha adipose tissue. (IL. Interleukin, TNF. Tumor necrosis factor, PAI. Plasminogen activator inhibitor, MCP. Monocyte chemoattractant protein, CXCL. Chemokine C-X-C motif ligand)

Adipokines	Function
Leptin	Regulation of feeding behavior, fat storage and insulin signaling
Resistin	Regulation of gluconeogenesis, insulin resistance, inflammation
IL-1	Role in macrophage chemotaxis and thermogenesis
IL-6	Effect on glucose metabolism
IL-7	Effect on regulation of body weight, adipose tissue mass, insulin signalling
IL-8	Role in neutrophil chemotaxis
TNF-α	Effect on insulin and glucose metabolism, increases insulin resistance
PAI-1	Inhibitor of fibrinolytic pathway
MCP-1	Increases macrophage recruitment in adipose tissue
Chemerin	Regulates adıpocyte development and metabolism
Vaspin	Regulates insulin sensitivity
CXCL5	Regulates insulin signalling in muscle tissue.
Visfatin	Regulates insulin secretion, sensitivity and inflammation
Adiponectin	Improves insulin resistance and glucose metabolism
Omentin	Improves glucose uptake and supresses inflammation

The complex alterations in adipose tissue secretion of various adipokines observed in adipose tissue-related pathologies such as obesity, insulin resistance and inflammation have been, and still are, an active research area.

IMAGING OF EPICARDIAL ADIPOSE TISSUE:

Various imaging modalities can be used to quantify the amount of EAT. Magnetic resonance imaging (MRI) is the gold standart modality for quatification of EAT. Cine four chamber and short axis MRI views of patients' used to measure EAT area in cm2. Measurements are done at the end-diastolic phase after careful delineation of pericardial border. Computer tomography (CT) could also be used to measure EAT amount. 3D CT scans should be used for reliable results. Motion artifacts are the most important problems in CT imaging. Beta blocker drugs are usually prescribed to decrease heart rate to overcome this problem. Trans thoracic echocardiography is the most common, cost effective and easily applicable method for measurement of EAT. EAT defined as the echo-lucent space between epicardium of the right ventricle free wall and parietal pericardium at the parasternal long axis view of transthoracic echocardiography (figure 2).

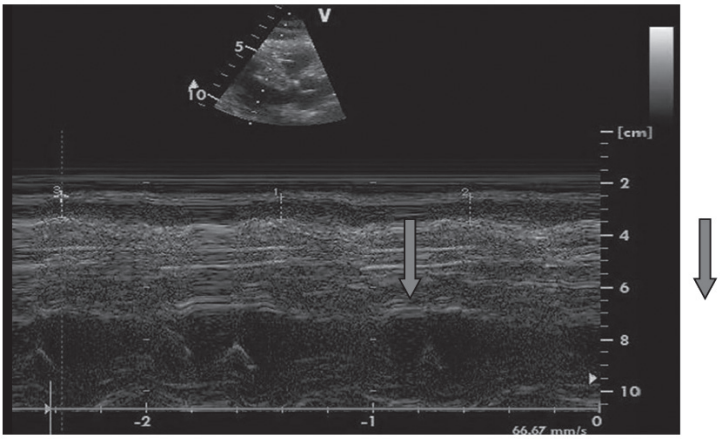

Figure 2. Measurement of epicardial adipose tissue at the parasternal long-axis view. Arrow heads show wpicardial adipose tissue.

EAT measurement by echocardiography was first defined in 2003 by Iacobellis et al (Icobellis & et al, 2003)17. They stated that the reason for them to prefer this point was the highest EAT thickness in that area and optimal cursor beam orientation in each view. Measurement of EAT by this method is significantly correlated with the MRI measurements and confirmed the accuracy of measurements by echocardiography17.

CLINICAL ASPECT:

Cytokines produced by EAT have important physiological and clinical effect on the heart. These cytokines contribute to the regulation of vascular flow, func-

tioning as an immuno- mechanical barrier to the coronary arteries, and producing thermogenic effects (Bertaso & et al 2013)18. EAT also serves as a fatty acid depot during excessive exercises. The quantity of EAT increases in a state of positive energy balance, which shares similar pathophysiological mechanisms with visceral adipose tissue accumulation during the progression of metabolic syndrome. Close relationship between EAT and insulin resistance attracts attention to the effect of antidiabetic drugs regulating insulin resistance on EAT. Yagi et al mentioned that, canagliflozin treatment decreased EAT which may have effect in preventing cardiovascular events (Yagi & et al, 2017)19. Iacobellis et al showed that, liraglutide causes rapid EAT reduction (Icobellis & et al, 2017)20.

Due to the close anatomical contact of EAT and coronary arteries, which is described above, local effects of cytokines might accelerate coronary atherosclerosis through pro-inflammatory effect on endothelium (Hirata & et al, 2011)21. They may also contribute to plaque instability, that results in acute coronary syndromes (Rajsheker & et al, 2010)22. There is considerable evidence that the quantity of EAT is related to the presence and severity of coronary artery disease (Greif & et al, 2009)23. Furthermore, aside from the effects on atherosclerosis, fatty infiltration in the myocardium may also interfere with diastolic relaxation and the cardiac conduction system (Ng & et al, 2018)24.

In this brief review we tried the summarize different aspects of EAT. As visceral adipose tissue became a type of endocrine organ, it would attract more attention in future.

REFERENCES:

1. Kershaw EE, Flier JS (2004). Adipose tissue as an endocrine organ. The Journal of Clinical Endocrinology and Metabolism**.** 89 (6): 2548–56.
2. Montague CT, O'Rahilly S (2000). The perils of portliness: causes and consequences of visceral adiposity. *Diabetes*. 49 (6): 883–88.
3. Kern PA, Ranganathan S, Li C, Wood L, Ranganathan G (2001). Adipose tissue tumor necrosis factor and interleukin-6 expression in human obesity and insulin resistance. American Journal of Physiology. Endocrinology and Metabolism. 280 (5): E745–51.
4. Marette A (2004). Molecular mechanisms of inflammation in obesity-linked insulin resistance. International Journal of Obesity and Related Metabolic Disorders. 27 Suppl 3: S46–48.
5. Talman AH, Psaltis PJ, Cameron JD, Meredith IT, Seneviratne SK, Wong DT (2014). Epicardial adipose tissue: far more than a fat depot. Cardiovasc Diagn Ther. (4):416–429.
6. Nitesh Nerlekar, Adam J. Brown, Rahul G. Muthalaly, Andrew Talman, Thushan Hettige, James D. Cameron, Dennis T. L. Wong. Association of Epicardial Adipose Tissue and High-Risk Plaque Characteristics: A Systematic Review and Meta-Analysis (2017). J Am Heart Assoc. (6):e006379. DOI: 10.1161/JAHA.117.006379.

7. Edwards WD (1984). Anatomy of the cardiovascular system: Clinical Medicine. Vol. 6 Philadelphia: Harper&Row. 1-24
8. Iacobellis G, Corradi D, Sharma AM (2005). Epicardial adipose tissue: anatomic, biomolecular and clinical relationships with the heart. Nat Clin Pract Cardiovasc Med; (2):536–543
9. Edwards WD (1995). Cardiac anatomy and examination of cardiac specimens. In: Emmanouilides G, Riemenschneider T, Allen H, Gutgesell H, eds. Adams' Heart Dİsease in Infants, Children, and Adolescent. 5th ed. Baltimore: Williams & Wilkins; 70-105
10 Jornet A, Reig J, Ruiz C, Uson M, Petit M (1990). The intervenous tubercle (or lower): Morphological characteristics and changes in relation to age. Arch Anat Histol Embryol 73:21–32
11. Virágh S, Challice CE (1981). The origin of the epicardium and the embryonic myocardial circulation in the mouse. Anat Rec 201(1):157–168.
12. Sucov HM, Gu Y, Thomas S, Li P, Pashmforoush M (2009) Epicardial control of myocardial proliferation and morphogenesis. Pediatr Cardiol 30(5):617–62
13. Riley PR (2012). An epicardial floor plan for building and rebuilding the mammalian heart. Curr Top Dev Biol 100:233–251.
14. Acharya A, Baek ST, Huang G, Eskiocak B, Goetsch S, Sung CY, Banfi S, Sauer MF, Olsen GS, Duffield JS, Olson EN Tallguist MD. (2012) The bHLH transcription factor Tcf21 is required for lineage-specific EMT of cardiac fibroblast progenitors. Development 139(12):2139–2149
15. Yukiko Yamaguchia, Susana Cavalleroa, Michaela Pattersona, Hua Shena, Jian Xub, S. Ram Kumarc, and Henry M. Sucova (2015) Adipogenesis and epicardial adipose tissue: A novel fate of the epicardium induced by mesenchymal transformation and PPARγ activation. PNAS : (7) ;2070-2075
16. S. Lucas, C. Verwaerde, and I. Wolowczuk (2009). Is the adipose tissue the key road to inflammation? Immunology and Immunogenetics Insights, (1);3–14
17. Iacobellis G, Assael F, Ribaudo MC, Zappaterreno A, Alessi G, Di Mario U (2003). Epicardial fat from echocardiography: a new method for visceral adipose tissue prediction. Obes Res, (11): 304e310.
18. Bertaso AG, Bertol D, Duncan BB, Foppa M (2013). Epicardial fat: definition, measurements and systematic review of main outcomes. Arq Bras Cardiol;101:e18–28.
19. Yagi S, Hirata Y, Ise T, Kusunose K, Yamada H, Fukuda D, Salim HM, Maimaituxun G, Nishio S, Takagawa Y, Hama S, Matsuura T, Yamaguchi K, Tobiume T, Soeki T, Wakatsuki T, Aihara KI, Akaike M, Shimabukuro M, Sata M (2017). Canagliflozin reduces epicardial fat in patients with type 2 diabetes mellitus. Diabetol Metab Syndr. (4);9:78. doi: 10.1186/s13098-017-0275-4
20. Iacobellis G, Mohseni M, Bianco SD, Banga PK (2017). Liraglutide causes large and rapid epicardial fat reduction. Obesity;(2):311-316. doi: 10.1002/oby.21718.
21. Hirata Y, Kurobe H, Akaike M, Chikugo F, Hori T, Bando Y (2011). Enhanced inflammation in epicardial fat in patients with coronary artery disease. Int Heart J;52:139–42.
22. Rajsheker S, Manka D, Blomkalns AL, Chatterjee TK, Stoll LL, Weintraub NL (2010). Crosstalk between perivascular adipose tissue and blood vessels. Curr Opin Pharmacol;(10):191–6.
23. Greif M, Becker A, von Ziegler F, Lebherz C, Lehrke M, Broedl UC (2009). Pericardial adipose tissue determined by dual source CT is a risk factor for coronary atherosclerosis. Arterioscler Thromb Vasc Biol;29:781–6.
24. Ng ACT, Strudwick M, van der Geest RJ, Ng ACC, Gillinder L, Goo SY, Cowin G, Delgado V, Wang WYS, Bax JJ (2018). Impact of Epicardial Adipose Tissue, Left Ventricular Myocardial Fat Content, and Interstitial Fibrosis on Myocardial Contractile Function. Circ Cardiovasc Imaging. 11(8):e007372. doi: 10.1161/CIRCIMAGING.117.007372