Clinical and Experimental Health Sciences

Oral Administration of Aronia Melanocarpa Extract Promotes Palatal Secondary Wound Healing in Diabetic Rats

Esra Tunç[1], Berkay Göler[1], Sibel Demirci Delipınar[2], Leyla Kuru[1], Hatice Selin Güngörmek[1]

[1] Department of Periodontology, Faculty of Dentistry, Marmara University, Istanbul, Türkiye.
[2] Department of Histology and Embryology, Faculty of Medicine, Biruni University, Istanbul, Türkiye.

Correspondence Author: Hatice Selin Güngörmek
E-mail: selin.yildirim@marmara.edu.tr

Received: January 23, 2026 **Accepted:** March 4, 2026

ABSTRACT

Objective: This study aimed to examine the clinical outcome of orally administered Aronia melanocarpa extract in the healing of secondary palatal wounds in healthy (H) and diabetic (D) rats.

Methods: A total of 50 male Wistar albino rats were randomly allocated to two primary groups: H group and D group. Diabetes was produced in 25 randomly selected rats by injecting 110 mg/kg of nicotinamide intraperitoneally, followed 15 minutes later by an intraperitoneal injection of 65 mg/kg of streptozotocin solution. In the center of the palate, 4 mm excisional incisions were created. Then, 5 animals per group were euthanized. Thereafter, each main group was further divided into two subgroups: H with the aronia (HA) group, H with the saline (HS) group; D with the aronia (DA) group, D with the saline (DS) group (n = 10 per group). On days 7 and 21, five rats from each group were euthanized, and wound areas (WA) were quantified from standardized photographs using ImageJ software.

Results: In the within-group comparison, significant decrease in WA over time was observed in each group ($p < .05$). The WA of the HA and DA groups were smaller compared to that of the DS group on days 7 and 21 ($p < .05$). Nevertheless, WA did not differ significantly between the HS and HA groups on days 7 and 21 ($p > .05$).

Conclusion: The oral administration of Aronia melanocarpa extract effectively enhanced secondary wound healing and decreased WA in D rats.

Keywords: Wound healing, diabetes mellitus, Aronia melanocarpa, rat, palate

1. INTRODUCTION

A wound is defined as a loss of tissue integrity and functional continuity caused by physical trauma, chemical injury, or surgical procedures. The physiological repair response can be described as a sequence of overlapping phases that begin immediately after tissue damage and proceed through hemostasis, inflammation, proliferation, and remodelling (1). This process involves coordinated events such as clot development, inflammatory cell recruitment, re-epithelialization, neovascularization, granulation tissue formation, wound contraction, scar formation, and subsequent tissue maturation. Disruptions affecting any of these stages may aggravate tissue injury and extend the duration of repair. Moreover, various local and systemic conditions may interfere with one or more phases of healing, leading to delayed or compromised wound closure (2). Diabetes mellitus (DM) is one of the systemic factors known to adversely influence wound healing. DM is a multifaceted chronic condition characterized by glucose dysregulation, problems in insulin secretion, autoimmune-mediated destruction of beta cells, or insufficient insulin secretion compensating for insulin resistance. Diabetic (D) patients frequently have complications, including macrovascular and microvascular disorders, neuropathy, and delayed wound healing (3). Although the causes of delayed wound healing are not completely understood, several pathophysiological factors have been implicated. These include impaired epithelialization and glucose metabolism, decreased angiogenesis, fibroblast and endothelial cell dysfunction, elevated oxidative stress, and delayed collagen synthesis (4).

Numerous plant extracts with potent antioxidant properties have been widely utilized in wound management and have also demonstrated wound healing effects. *Aronia melanocarpa* is a fruit abundant in polyphenolic compounds, including anthocyanins, proanthocyanidins, and phenolic acids. This fruit contains high levels of vitamin C, vitamin E, B complex vitamins, minerals, and various other bioactive compounds, which provide potent antioxidant effects (5).

How to cite this article: Tunç E, Göler B, Demirci Delipınar S, Kuru L, Güngörmek HS. Oral Administration of Aronia Melanocarpa Extract Promotes Platal Secondary Wound Healing in Diabetic Rats. Clin Exp Health Sci 2026; 16: 174-180. https://doi.org/10.33808/clinexphealthsci.1870571

Copyright © 2026 Marmara University Press

Content of this journal is licensed under a Creative Commons Attribution-NonCommercial 4.0 International License.

Aronia melanocarpa supplementation has been found to enhance cardiovascular health, reduce blood pressure, and assist in managing hypertension (8). Moreover, the capacity to enhance the lipid profile indicates that *Aronia melanocarpa* may serve a preventive function against hyperlipidemia (9). Furthermore, it has advantageous effects on the gastrointestinal system owing to its bacteriostatic qualities (10). Additionally, recent studies indicates that *Aronia melanocarpa* is distinguished by its antioxidant, antiviral, anticancer, and anti-inflammatory characteristics (11, 12). Along with this, positive effects have been seen in the management of DM (13). The diverse benefits of *Aronia melanocarpa* are contributing to its growing popularity as a dietary supplement. This study aimed to examine the clinical outcome of orally administered *Aronia melanocarpa* extract in the healing of secondary palatal wounds in healthy (H) and D rats.

2. METHODS

Ethical approval was obtained from the Acıbadem Mehmet Ali Aydınlar University Animal Experiments Local Ethics Committee (February 22, 2024; Approval No: 06/2024). All experimental procedures were carried out in accordance with the ARRIVE guidelines and the Guide for the Care and Use of Laboratory Animals.

2.1. Experimental animal

All animals were obtained from the Acıbadem Mehmet Ali Aydınlar University Experimental Animal Research and Application Center (Istanbul, Türkiye). Pathogen-free H Wistar albino rats were housed in the institutional animal facility under standardized environmental conditions (26 ± 2°C, 44–56% relative humidity, 10 h/14 h light–dark cycle) for 1 week before and throughout the experimental period. Rats were given a standard rat pellet diet and water ad libitum. Humane termination criteria were defined as a body weight reduction exceeding 20%, prolonged immobility, severe wound related infection, or clear evidence of suffering. No animal reached the predefined humane endpoints during the experimental period, and all animals completed the study (14).

2.2. Induction of Diabetes

Following a 12-hour fasting period, experimental type 2 DM was induced via intraperitoneal administration of nicotinamide at a dosage of 110 mg/kg (Acros Organics BV, Geel, Belgium), succeeded 15 minutes later by a singular intraperitoneal injection of 65 mg/kg streptozotocin (ChemCruz, Santa Cruz Biotechnology, Dallas, TX), freshly prepared in distilled water. To counteract the hypoglycemia induced by streptozotocin, the rats consumed a 5% glucose solution during the night. Three days later, blood glucose was measured with a glucometer (eBsensor Blood Glucose Monitoring System, Visgeneer Inc., Taiwan) to confirm diabetes induction. Rats with glucose concentrations exceeding 200 mg/dL were classified as D and selected for the study (15).

2.3. Wound Creation

Intraperitoneal anesthesia was induced using ketamine hydrochloride 100 mg/kg (Ketalar, Eczacıbaşı, Türkiye) combined with xylazine hydrochloride 10 mg/kg (Rompun, Bayer, Germany). All surgical interventions were performed by the same experienced researcher (ET). Following general anesthesia, each rat was stabilized, and the oral cavity was accessed using a retractor. A circular excisional wound 4 mm in diameter was created at the center of the palatal mucosa using a disposable punch biopsy instrument (Kai Medical, Kai Industries Co., Ltd., Seki, Japan). After hemostasis, the wounds were allowed to heal by secondary intention. Five rats from the H and D groups were euthanized immediately after wound induction on day 0. The H and D groups were subsequently subdivided based on a computer-generated randomization table as follows: H with aronia (HA) group, H with saline (HS) group; D with aronia (DA) group, and D with saline (DS) group (n=10 per group). Five animals per group were euthanized via decapitation on postoperative days 7 and 21.

2.4. Aronia melanocarpa and Saline Administration

Standardized *Aronia melanocarpa* extract (Alixir Protect 400®; Pharmanova, Belgrade, Serbia) is a commercial product. The extraction procedure was performed by EU-Chem Company (Belgrade, Serbia). In each 30 mL of the oral solution, the standardized aronia extract contains polyphenols (431 mg) and anthocyanins (120 mg), as well as potassium sorbate (35.1 mg), with a minimal ethanol content (0.04% v/v) (16).

Subsequent to the formation of a surgical wound on the palate, the rats in the HA and DA groups were administered a total of 10 mL/kg of *Aronia melanocarpa* extract daily, divided into two doses over a period of 21 days, whereas the rats in the HS and DS groups received 10 mL/kg of saline solution (1 mL of 0.9% NaCl) (Polifarma, Tekirdag, Türkiye) via orogastric gavage.

2.5. Measurement of Wound Area

Wound areas (WA) were photographed on day 0 (immediately post-surgical wound formation) and on days 7 and 21 after maxillary dissection. For calibration purposes, all images were obtained at a consistent distance and magnification, utilizing a UNC-15 periodontal probe (University of North Carolina, Hu-Friedy Manufacturing Inc., Chicago, IL, USA) as a reference scale, alongside a digital camera (Canon EOS 5D, Tokyo, Japan). Following imaging, the images were uploaded to a computer, and the average WA for each group was measured utilizing ImageJ software (National Institutes of Health, Bethesda, MD, USA). All measurements were conducted by the calibrated blinded investigator (BG). Intra-examiner reliability was confirmed by re-measuring 12

randomly selected images (≈20% of all wound images) after one week using intraclass correlation coefficient (ICC = 0.85). Wound photographs were coded prior to analysis to ensure blinding by other investigator (ET).

2.6. Statistical Analysis

The required sample size was calculated using G Power software (version 3.1.9.2, 2014; University of Kiel, Kiel, Germany). Based on a previous study (4), the required sample size was calculated as 5 rats per group (effect size = 0.85, α = 0.05, power = 0.90), resulting in a total of 50 rats.

Statistical analyses were performed using IBM SPSS Statistics (version 24; Chicago, IL, USA). The Shapiro–Wilk test was applied to evaluate distribution patterns. Since the variables were not normally distributed, nonparametric methods were used. Data were summarized as median values with the corresponding minimum and maximum. The Kruskal Wallis test was used for multiple-group comparisons, followed by the Bonferroni corrected Mann Whitney U test for pairwise analyses when appropriate. The Friedman test was used for within-group comparisons over time, if a significant difference was observed, post hoc pairwise analyses were performed with the Bonferroni corrected Wilcoxon test. Statistical significance was set at $p < .05$.

3. RESULTS

Figure 1 shows clinical images of the WA for all groups on days 0, 7, and 21. Healing was uneventful, and no complications were observed. Clinical examination showed gradual wound healing over time in all groups.

The median WA measurements of all groups on postoperative days 0, 7, and 21 are shown in Table 1. When the median WA values of all groups were compared within groups, it was found that all groups were similar on day 7 compared to baseline ($p > .05$). On day 21, WA was significantly lower than baseline in all groups ($p < .05$). In the DS group, there was a statistically significant reduction on day 21 compared to day 7 ($p < .05$).

In the intergroup comparison, the median WA did not differ between the H and D groups at day 0. (13.93 mm^2 and 14.59 mm^2, respectively) ($p > .05$). The lowest WA on days 7 and 21 was recorded in the HA group, whereas the highest WA was observed in the DS group. On day 7, WA was significantly lower in the HA and DA groups than in the DS group ($p < .05$). On day 21, WA was significantly lower in the HA, DA, and HS groups compared with the DS group ($p < .05$). WA was found to be similar between the HS and HA groups on days 7 and 21 ($p > .05$).

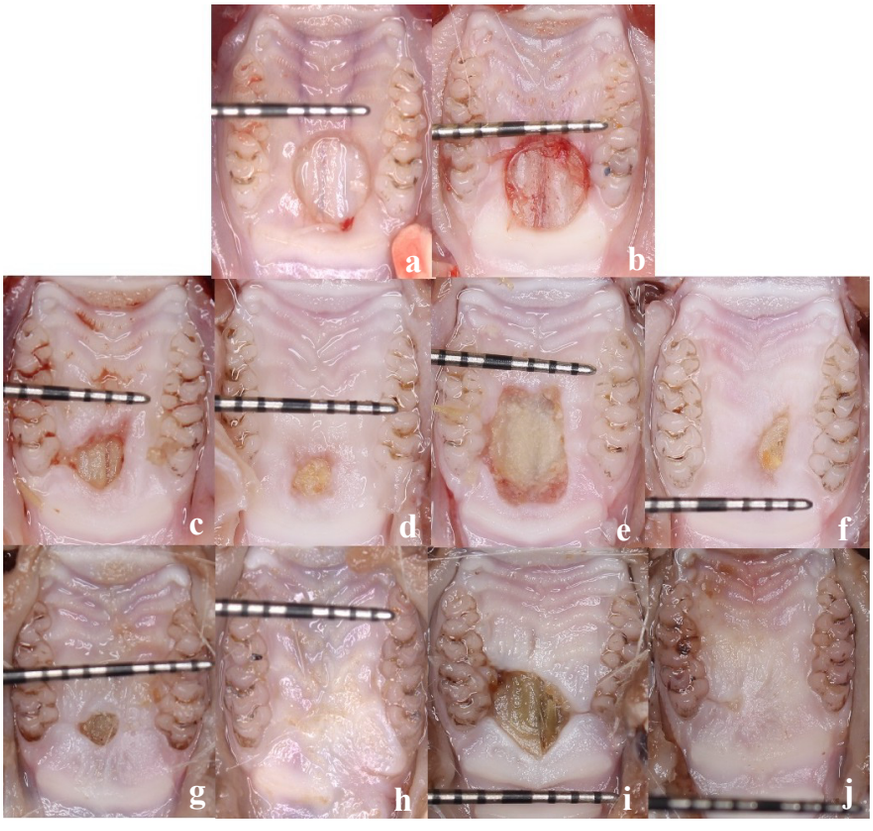

Figure 1. *Representative clinical images of the palatal wound area in (a) healthy group and (b) diabetic group at day 0, (c) healthy saline group, (d) healthy aronia group, (e) diabetic saline group and (f) diabetic aronia group at day 7, (g) healthy saline group, (h) healthy aronia group, (i) diabetic saline group and (j) diabetic aronia group at day 21 after surgery*

Table 1. *Inter and intra group comparison of wound area (mm^2)*

	Groups													
	H (a) (n=5) Median (Min-Max)	**D (b) n=5 Median (Min-Max)**	**HS (c) n=10 Median (Min-Max)**	**HA (d) n=10 Median (Min-Max)**	**DS (e) n=10 Median (Min-Max)**	**DA (f) n=10 Median (Min-Max)**	**p*(a-b)**	**p#(c-d-e-f)**	**p*(c-d)**	**p*(c-e)**	**p*(c-f)**	**p*(d-e)**	**p*(d-f)**	**p*(e-f)**
Day 0	13.93 12.26-14.93	14.59 12.88-15.79					.347							
Day 7			6.54 5.24-11.73	4.22 2.03-6.18	14.21 10.20-16.16	6.05 2.93-8.41		.005	.069	.109	.336	.001	.392	.010
Day 21			1.19 0.00-4.55	1.03 0.00-2.36	5.28 3.84-11.34	2.40 0.00-3.14		.009	.788	.005	.419	.002	.281	.046
p†			.007	.007	.022	.015								
p‡(0-7)			.114	.114	.752	.058								
p‡(0-21)			.002	.002	.011	.004								
p‡(7-21)			.114	.114	.027	.343								

*H; Healthy, D; Diabetic, HS; Healthy Saline, HA; Healthy Aronia, DS; Diabetic Saline, DA; Diabetic Aronia, Min; Minimum, Max; Maximum, * Bonferroni corrected Mann Whitney U test, # Kruskal Wallis test, † Friedman test, ‡Bonferroni corrected Wilcoxon test, p < .05.*

4. DISCUSSION

D wounds are among the most common and serious complications in patients with DM, as impaired wound healing may progress to chronic, non-healing wounds. Moreover, the prevalence of chronic wounds in D patients has been increasing in recent years. The main factors influencing D wound healing include poor glycemic control, insulin resistance, and elevated levels of oxidative stress. In D patients, wound healing is compromised due to an impaired inflammatory response, poor circulation, reduced angiogenesis, and insufficient fibroblast migration. In addition, D wound sites exhibit a marked increase in apoptotic cells, along with increased expression of pro-inflammatory cytokines and decreased expression of anti-inflammatory cytokines, which further disrupts the wound healing process (17, 18).

In wound healing studies, the use of male rats is often preferred to reduce variability associated with hormonal fluctuations. Female rats undergo cyclical hormonal changes related to the estrous cycle, which may influence the wound healing process and introduce biological variability. Male rats, lacking such cyclical hormonal variation, allow for more consistent and reproducible outcomes. In addition, male rats are generally larger and more resilient, making them suitable for surgical procedures and experimental wound models. This approach has been shown to improve the reliability and reproducibility of experimental findings (19). Accordingly, consistent with similar experimental models of secondary wound healing, only male rats were used in this study (20, 21).

In a previous study, oral doses of 5, 10, and 20 mL/kg of *Aronia melanocarpa* were administered to rats in a gastric mucosal injury model (10). Considering also previous reports indicating that *Aronia melanocarpa* may affect platelet aggregation, and given that the present study involved a secondary wound healing model in which adequate hemostasis is important, higher dose levels were avoided to minimize any potential interference with clot formation (22, 23). An unpublished preliminary study was therefore conducted in healthy rats prior to our study. Two different doses (5 and 10 mL/kg) were tested, and the 10 mL/kg dose was selected for the current study as it resulted in enhanced wound closure and epithelialization without evidence of antiplatelet effects.

Aronia melanocarpa has shown efficacy in the treatment of DM, cardiovascular disease, hypercholesterolemia, hyperlipidemia, and hypertension, attributed to its therapeutic constituents, including polyphenols. *Aronia melanocarpa* demonstrates antioxidant properties by decreasing reactive oxygen species generation, obstructing pro-oxidant enzymes, and modulating antioxidant enzymes, as well as anti-inflammatory actions by diminishing pro-inflammatory cytokines (6, 24, 25). Nevertheless, the benefits of *Aronia melanocarpa* remain contentious, and there is an absence of data about the oral administration of *Aronia melanocarpa* in D secondary wound healing. Accordingly, the purpose of this study was to assess the clinical impact of orally administered *Aronia melanocarpa* extract on WA in D rats.

Wound healing is a complex, phased process beginning with hemostasis and inflammation (days 1–3), followed by proliferation (days 4–7), and concluding with remodelling

(days 14–21). These stages involve tightly regulated cellular and molecular events, including clot formation, immune cell infiltration, fibroblast activation, collagen synthesis, and angiogenesis, ultimately leading to granulation tissue formation and tissue maturation (26). Day 7 marks the peak of the proliferative phase, characterized by active fibroblast proliferation, intense collagen deposition, epithelial migration, and neovascularization, while macrophages orchestrate the transition from inflammation to tissue regeneration. On day 21, remodelling-related changes are evident, such as collagen maturation and cross-linking, reduced vascular density, and increased tensile strength (27, 28). Thus, clinical healing becomes more apparent. For this reason, WA was evaluated on days 7 and 21 in this study.

According to our study, the WA on day 7 was found to be smaller than the DS group in the HA and DA groups, and on day 21 was found to be smaller than the DS group in the HA, DA, and HS groups. In this study, *Aronia melanocarpa* significantly accelerated the clinical healing of wounds in D rats. To our knowledge, there are no studies examining the effects of orally administered antioxidant extracts on palatal secondary wound healing; however, there are studies on cutaneous wound models in D rats (15, 29, 30, 31, 32). Hyun et al. (29) indicated that systemic administration of 100 mg/kg of flavonoid-rich *Aster koraiensis* extract resulted in a decreased WA in the D group on day 8, compared to the DS group. Parmar et al. (15) demonstrated that the oral administration of 100 and 200 mg/kg of phenolic-rich *Solanum xanthocarpum* extract led to reduced WA in the DM groups on day 7, in contrast to the DS group. Ahmad et al. (30) show that oral administration of pomelo peel extract, abundant in flavonoids and vitamin C, at doses of 400 and 600 mg/kg, led to a greater percentage of wound size reduction in the D groups in comparison to the DS group on days 7 and 21. Li et al. (31) indicated that hesperidin, a plant-derived flavonoid, enhanced the wound healing rate on day 21, in the DS group exhibiting a poorer closure rate compared to the hesperidin groups. Chen et al. (32) reported that 100 mg/kg of the antioxidant rutin decreased WA in D rats during the initial phases, and on day 21, the WA in the DS group was greater than in the H and rutin-treated groups. This is the first study to evaluate the efficacy of orally administration of *Aronia melanocarpa* extract on secondary palatal wound healing in D rats through clinical evaluation of wound closure. Our findings on days 7 and 21 were consistent with previous studies reporting favorable outcomes. It has been suggested that the oral administered polyphenol-rich *Aronia melanocarpa* extract reduces WA and accelerates wound healing in secondary palatal wounds of streptozotocin-nicotinamide induced D rats, and the primary constituents responsible for these effects are reported to be flavonoids present in the extract. The effects of *Aronia melanocarpa* may be explained by its ability to suppress the formation of reactive oxygen species and reactive nitrogen species, inhibit pro-oxidant enzymes, and regulate antioxidant enzymes (6, 17).

This study has several limitations, including the absence of H and D groups in which the natural progression of wound healing was observed without any intervention, aside from the saline administration group, and the lack of a 14-day assessment corresponding to the extended inflammatory and/or proliferative phases. In addition, wound healing was evaluated solely through clinical wound area measurements, and the absence of histological, biochemical, or molecular analyses restricts a more detailed biological interpretation of the findings. Continuous monitoring of blood glucose levels was not performed during the experimental period. Furthermore, only a single dose of the extract was evaluated in this study. Therefore, the findings of our research have limited implications and require validation through more comprehensive investigations.

5. CONCLUSION

The oral administration of *Aronia melanocarpa* extract enhanced secondary wound healing and decreased WA in D rats. Therefore, oral administration of *Aronia melanocarpa* extract may be used as a dietary supplement to support wound healing in D patients, particularly after surgical procedures managed by secondary intention.

Funding: *The author(s) received no financial support for the research.*

Conflicts of interest: *The authors declare that they have no conflict of interest.*

Ethics Committee Approval: *This study was approved by Ethics Committee of Acibadem Mehmet Ali Aydinlar University, Animal Experiments Local Ethics Committee (Approval date:22.02.2024; Number: 06/2024)*

Peer-review: *Externally peer-reviewed.*

Author Contributions:

Research idea: ET, HSG
Design of the study: ET, HSG
Acquisition of data for the study: ET, BG
Analysis of data for the study: ET, BG, SDD, HSG
Interpretation of data for the study: ET, HSG
Drafting the manuscript: ET, HSG
Revising it critically for important intellectual content: BG, SDD, LK
Final approval of the version to be published: ET, BG, SDD, LK, HSG

REFERENCES

[1] Dunnill C, Patton T, Brennan J, Barrett J, Dryden M, Cooke J, Leaper D, Georgopoulos NT. Reactive oxygen species (ROS) and wound healing: the functional role of ROS and emerging ROS-modulating technologies for augmentation of the healing process. Int Wound J. 2017;14(1):89-96. https://doi.org/10.1111/iwj.12557

[2] Ibrahim N, Wong SK, Mohamed IN, Mohamed N, Chin KY, Ima-Nirwana S, Shuid AN. Wound healing properties of selected natural products. Int J Environ Res Public Health. 2018;15(11):2360. https://doi.org/10.3390/ijerph15112360

[3] Ekmektzoglou KA, Zografos GC. A concomitant review of the effects of diabetes mellitus and hypothyroidism in wound healing. World J Gastroenterol. 2006;12(17):2721-2729. https://doi.org/10.3748/wjg.v12.i17.2721

[4] Adil M, Khan RA, Kalam A, Venkata SK, Kandhare AD, Ghosh P, Sharma M. Effect of anti-diabetic drugs on bone metabolism: Evidence from preclinical and clinical studies. Pharmacol Rep. 2017;69(6):1328-1340. https://doi.org/10.1016/j.pharep.2017.05.008

[5] Shi D, Xu J, Sheng L, Song K. Comprehensive utilization technology of Aronia melanocarpa. Molecules. 2024;29(6):1388. https://doi.org/10.3390/molecules29061388

[6] Denev PN, Kratchanov CG, Ciz M, Lojek A, Kratchanova MG. Bioavailability and antioxidant activity of black chokeberry (Aronia melanocarpa) polyphenols: in vitro and in vivo evidences and possible mechanisms of action: a review. Compr Rev Food Sci Food Saf. 2012;11(5):471-489. https://doi.org/10.1111/j.1541-4337.2012.00198.x

[7] Kokotkiewicz A, Jaremicz Z, Luczkiewicz M. Aronia plants: a review of traditional use, biological activities, and perspectives for modern medicine. J Med Food. 2010;13(2):255-269. https://doi.org/10.1089/jmf.2009.0062

[8] Broncel M, Kozirog M, Duchnowicz P, Koter-Michalak M, Sikora J, Chojnowska-Jezierska J. Aronia melanocarpa extract reduces blood pressure, serum endothelin, lipid, and oxidative stress marker levels in patients with metabolic syndrome. Med Sci Monit. 2010;16(1):CR28-34.

[9] Kondeva-Burdina M, Valcheva-Kuzmanova S, Markova T, Mitcheva M, Belcheva A. Effects of Aronia melanocarpa fruit juice on isolated rat hepatocytes. Pharmacogn Mag. 2015;11(Suppl 4):S592-597. https://doi.org/10.4103/0973-1296.172971

[10] Valcheva-Kuzmanova S, Marazova K, Krasnaliev I, Galunska B, Borisova P, Belcheva A. Effect of Aronia melanocarpa fruit juice on indomethacin-induced gastric mucosal damage and oxidative stress in rats. Exp Toxicol Pathol. 2005;56(6):385-392. https://doi.org/10.1016/j.etp.2005.01.003

[11] Borowska S, Brzoska MM. Chokeberries (Aronia melanocarpa) and their products as a possible means for the prevention and treatment of noncommunicable diseases and unfavorable health effects due to exposure to xenobiotics. Compr Rev Food Sci Food Saf. 2016;15(6):982-1017. https://doi.org/10.1111/1541-4337.12214

[12] Ren Y, Frank T, Meyer G, Lei J, Grebenc JR, Slaughter R, Gao YG, Kinghorn AD. Potential benefits of black chokeberry (Aronia melanocarpa) fruits and their constituents in improving human health. Molecules. 2022;27(22):7823. https://doi.org/10.3390/molecules27227823

[13] Christiansen CB, Jeppesen PB, Hermansen K, Gregersen S. Aronia in the type 2 diabetes treatment regimen. Nutrients. 2023;15(19):4188. https://doi.org/10.3390/nu15194188

[14] National Research Council (US) Committee for the Update of the Guide for the Care and Use of Laboratory Animals. Animal care and use program. Guide for the care and use of laboratory animals. 8th ed. Washington (DC): National Academies Press; 2011.p.12-35.

[15] Parmar KM, Shende PR, Katare N, Dhobi M, Prasad SK. Wound healing potential of Solanum xanthocarpum in streptozotocin-induced diabetic rats. J Pharm Pharmacol. 2018;70(10):1389-1400. https://doi.org/10.1111/jphp.12975

[16] Tasic N, Jakovljevic VLJ, Mitrovic M, Djindjic B, Tasic D, Dragisic D, Citakovic Z, Kovacevic Z, Radoman K, Zivkovic V, Bolevich S, Turnic TN. Black chokeberry Aronia melanocarpa extract reduces blood pressure, glycemia and lipid profile in patients with metabolic syndrome: a prospective controlled trial. Mol Cell Biochem. 2021;476(7):2663-2673. https://doi.org/10.1007/s11010.021.04106-4

[17] Huysman F, Mathieu C. Diabetes and peripheral vascular disease. Acta Chir Belg. 2009;109(5):587-594. https://doi.org/10.1080/00015.458.2009.11680493

[18] Khanna S, Biswas S, Shang Y, Collard E, Azad A, Kauh C, Bhasker V, Gordillo GM, Sen CK, Roy S. Macrophage dysfunction impairs resolution of inflammation in the wounds of diabetic mice. PLoS One. 2010;5(3):e9539. https://doi.org/10.1371/journal.pone.0009539

[19] Dorsett-Martin WA. Rat models of skin wound healing: A review. Wound Repair Regen. 2004;12(6):591-599. https://doi.org/10.1111/j.1067-1927.2004.12601.x

[20] Zhang Z, Zhao M, Wang J, Ding Y, Dai X, Li Y. Oral administration of skin gelatin isolated from chum salmon (Oncorhynchus keta) enhances wound healing in diabetic rats. Mar Drugs. 2011;9(5):696-711. https://doi.org/10.3390/md9050696

[21] Ahmad M, Ansari MN, Alam A, Khan TH. Oral dose of citrus peel extracts promotes wound repair in diabetic rats. Pak J Biol Sci. 2013;16(20):1086-1094. https://doi.org/10.3923/pjbs.2013.1086.1094

[22] Olas B, Wachowicz B, Tomczak A, Erler J, Stochmal A, Oleszek W. Comparative anti-platelet and antioxidant properties of polyphenol-rich extracts from berries of Aronia melanocarpa, seeds of grape and bark of Yucca schidigera in vitro. Platelets. 2008;19(1):70-77. https://doi.org/10.1080/095.371.00701708506

[23] Sikora J, Broncel M, Markowicz M, Chałubiński M, Wojdan K, Mikiciuk-Olasik E. Short-term supplementation with Aronia melanocarpa extract improves platelet aggregation, clotting, and fibrinolysis in patients with metabolic syndrome. Eur J Nutr. 2012;51(5):549-556. https://doi.org/10.1007/s00394.011.0238-8

[24] Kim JH, Choi MS, Auger C, Lee KW, Schini-Kerth VB. Polyphenol-rich Aronia melanocarpa juice sustains eNOS activation through phosphorylation and expression via redox-sensitive pathways in endothelial cells. Food Sci Biotechnol. 2024;33(12):2865-2875. https://doi.org/10.1007/s10068.024.01546-8

[25] Kong Y, Yan T, Tong Y, Deng H, Tan C, Wan M, Wang M, Meng X, Wang Y. Gut microbiota modulation by polyphenols from Aronia melanocarpa of LPS-induced liver diseases in rats. J Agric Food Chem. 2021;69(11):3312-3325. https://doi.org/10.1021/acs.jafc.0c08006

[26] Chhabra S, Chhabra N, Kaur A, Gupta N. Wound healing concepts in clinical practice of OMFS. J Maxillofac Oral Surg. 2017;16(4):403-423. https://doi.org/10.1007/s12663.016.0880-z

[27] Gosain A, DiPietro LA. Aging and wound healing. World J Surg. 2004;28(3):321-326. https://doi.org/10.1007/s00268.003.7397-6

[28] Spielman AF, Griffin MF, Parker J, Cotterell AC, Wan DC, Longaker MT. Beyond the scar: A basic science review of wound remodeling. Adv Wound Care (New Rochelle). 2023;12(2):57-67. https://doi.org/10.1089/wound.2022.0049

[29] Hyun SW, Kim J, Jo K, Kim JS, Kim CS. Aster koraiensis extract improves impaired skin wound healing during hyperglycemia. Integr Med Res. 2018;7(4):351-357. https://doi.org/10.1016/j.imr.2018.09.001

[30] Ahmad AA, Al Khalifa II, Abudayeh ZH. The role of pomelo peel extract for experimentally induced wound in diabetic rats.

Pharmacognosy Journal. 2018;10(5):885-891. https://doi.org/10.5530/pj.2018.5.149

[31] Li W, Kandhare AD, Mukherjee AA, Bodhankar SL. Hesperidin, a plant flavonoid accelerated the cutaneous wound healing in streptozotocin-induced diabetic rats: Role of TGF – β/Smads and Ang-1/Tie-2 signaling pathways. EXCLI J. 2018;17:399-419. https://doi.org/10.17179/excli2018-1036

[32] Chen L, Huang C, Liao C, Chang H, Kuan Y, Tseng T. Effects of rutin on wound healing in hyperglycemic rats. Antioxidants (Basel). 2020;9(11):1122. https://doi.org/10.3390/antiox9111122