Original Article

Does Alt-RAMEC protocol and facemask treatment affect dentoalveolar structures?
A 3-dimensional study

Elvan Önem Özbilen[a]; Hanife Nuray Yılmaz[a]; Yasemin Bahar Acar[a]

ABSTRACT

Objectives: To evaluate dentoalveolar changes immediately after the alternate rapid maxillary expansion and constriction (Alt-RAMEC) protocol and facemask (FM) treatment using cone-beam computed tomography images.

Materials and Methods: Cone-beam computed tomography images of 20 patients (mean age = 9.64 ± 1.3 years) who received the Alt-RAMEC protocol before FM treatment were retrieved in this retrospective study. Dental and alveolar inclinations, buccal and palatal alveolar bone thickness, and buccal and palatal alveolar bone height changes were measured before treatment (T0), after the Alt-RAMEC protocol (T1), and after FM treatment (T2). Measurements for right and left molars were performed separately. The Shapiro-Wilks test was used to assess the conformity of the parameters to the normal distribution. The paired *t*-test and repeated measures analysis of variance were used for normally distributed data. The Wilcoxon signed-rank test and Friedman test were used for non-normally distributed data. The Bonferroni correction was used to reduce the chances of obtaining false-positive results. Statistical significance was set at $P < .05$.

Results: Buccal alveolar bone thickness and alveolar bone inclinations decreased significantly from T1 to T0 and showed no significant change from T2 to T1. The total reduction T2-T0 was statistically significant. The change in palatal alveolar bone thickness was not significant T1-T0 but increased significantly for T2-T1 and T2-T0. Buccal alveolar bone height, palatal alveolar bone height, and molar inclinations increased significantly T1-T0, but there was no significant change T2-T1. The total reduction at T2-T0 was statistically significant.

Conclusions: The results of this study revealed that the effects of the Alt-RAMEC protocol on dentoalveolar tissues were similar to the changes reported in the literature after rapid palatal expansion. (*Angle Orthod.* 0000;00:000–000.)

KEY WORDS: Alt-Ramec; Cone-beam CT; Dentoalveolar; Maxillary expansion; Maxillary hypoplasia; Angle Class III

INTRODUCTION

Transverse maxillary deficiency is a common orthodontic malocclusion that is often accompanied by posterior crossbite (unilateral/bilateral) or crowding. Rapid palatal expansion (RPE) uses heavy, intermittent forces,[1] creating hyalinization of the periodontal ligament of the anchor teeth, thus transferring all the exerted forces to the midpalatal suture to achieve a more orthopedic and less orthodontic effect.[2] Growing patients can benefit from RPE, which corrects transverse maxillary deficiency by separating not only the midpalatal suture but also the circummaxillary and circumzygomatic sutures.[3] However, unfavorable dentoalveolar changes, such as buccal crown tipping, decrease in alveolar bone thickness, bone height, and cortical fenestrations, and increase in palatal bone thickness, may occur in the anchor teeth after RPE.[4–13]

The alternate rapid maxillary expansion and constriction (Alt-RAMEC) protocol was proposed by Liou and Tsai[14] to facilitate maxillary protraction in growing

[a] Assistant Professor, Department of Orthodontics, School of Dentistry, Marmara University, İstanbul, Turkey.

Corresponding author: Dr Yasemin Bahar Acar, Department of Orthodontics, School of Dentistry, Marmara University, Marmara Üniversitesi Başıbüyük Health Campus 9/3, 34854 Başıbüyük Maltepe, İstanbul, Turkey
(e-mail: yaseminbaharciftci@gmail.com)

Accepted: January 2021. Submitted: November 2020.
Published Online: April 12, 2021

© 0000 by The EH Angle Education and Research Foundation, Inc.

Downloaded from http://meridian.allenpress.com/angle-orthodontist/article-pdf/doi/10.2319/111620-940.1/2808366/10.2319_111620-940.1.pdf by Marmara Univ user on 15 August 2021

Table 1. Descriptive Statistics (Mean ± SD) for Patient Age and Treatment Time

Age of Patients, Years					
T0	T1	T2	T1-T0, Months	T2-T1, Months	T2-T0, Months
9.74 ± 1.46	9.91 ± 1.46	10.82 ± 1.5	2.22 ± 0.07	10.9 ± 3.01	13.13 ± 3.01

patients with maxillary hypoplasia by increasing the disarticulation of circummaxillary sutures. Since a tooth-borne expander is used for this protocol, the anchor teeth and alveolar bone will inevitably be affected. In the literature, two studies have evaluated the effects of Alt-RAMEC on the anchor teeth and alveolar bone. Gandedkar and Liou[15] reported a statistically significant reduction in buccal alveolar bone thickness (BABT) and an increase in palatal alveolar bone thickness (PABT) at the cervical region of first molars. Rinaldi et al.[7] found significant alveolar bone resorption and loss of attachment after RPE with the Alt-RAMEC protocol compared with the other groups in their study.

In the present study, the null hypothesis was that the Alt-RAMEC protocol would not cause any immediate dentoalveolar changes. The aim of the study was to measure and compare dental and alveolar inclinations, buccal and palatal alveolar bone thicknesses, and buccal and palatal alveolar bone heights at three time points: before treatment, immediately after the Alt-RAMEC protocol, and after subsequent facemask (FM) treatment using cone-beam computed tomography (CBCT) images.

MATERIALS AND METHODS

This retrospective study was approved by the Ethical Committee of Marmara University, Faculty of Dentistry (30.06.2020, 2020/52; Istanbul, Turkey). G*Power (version 3.1.7, Heinrich-Heine-Universität, Düsseldorf, Germany) software was used for calculating sample size based on a previous study.[9] The calculation indicated that a minimum of 19 patients was required for a power of 0.80 and an alpha of 0.05 to obtain a difference of 0.6 mm for detecting bone loss of the first molars after RPE. Records of 20 patients (10 boys, 10 girls; mean age = 9.64 ± 1.3 years) who received the Alt-RAMEC protocol before FM treatment were collected from the archive of Marmara University, Department of Orthodontics (Istanbul, Turkey). Inclusion criteria were: transverse maxillary deficiency, Class III malocclusion due to maxillary hypoplasia, no previous orthodontic treatment, no systemic or genetic disease and complete records. An acrylic cap with a double-hinged expansion screw (US Patent No. 6334771B1) was used for the expansion protocol. The screw was activated at a rate of 1 mm/day for the first week and closed at a rate of 1 mm/day the next week, as described in the routine protocol of Alt-RAMEC.[14] This sequence was followed for nine weeks. The ninth week corresponded to the activation (opening) set. Therefore, all patients had 1 week of rapid expansion (1 mm/day; 7 mm of expansion in total) before the FM treatment. Then, patients were instructed to wear the FM for a minimum of 16 hours/day with the same appliance.

CBCT images were taken before treatment (T0), after Alt-RAMEC (T1), and after FM treatment (T2) (Table 1), using an Iluma Imtec Imaging Machine (3M, Ardmore, Okla; X-ray tube voltage: 120 kV; X-ray tube current: 1–4 mA; scanning time: 40 seconds maximum and 7.8 seconds minimum; field of view: 14.2 × 21.1 cm; voxel size: 0.0936 mm; grey scale: 14 bit) while patients were sitting in an upright position with their Frankfurt horizontal plane (FHP) parallel to the floor. The dentoalveolar changes were analyzed using MIMICs version 24.0 software (Materialise Europe, Leuven, Belgium) by the same examiner (Dr Özbilen) who was blinded to the time point. Images were oriented with the reslicing function to ensure that the FHP was parallel to the floor and the midsagittal plane and coronal plane were perpendicular to the FHP. Four axial planes were created parallel to the FHP for the right and left maxillary first molar based on a previous study (Table 2).[15] Buccal alveolar bone thickness (BABT) and palatal alveolar bone thickness (PABT) were measured from the most external border of the alveolar bone to the outermost aspect of the distobuccal, mesiobuccal, and palatal roots of both first molars in the four axial planes (Table 2; Figures 1 and 2). For both the right and left molars, dental and alveolar inclinations, buccal alveolar height (BAH), and palatal alveolar height (PAH) were measured on the coronal slice, which was the first anterior slice showing the entire palatal root and the crown of the maxillary first molar (Table 2; Figure 3).[11,13]

Statistical Analysis

IBM SPSS Statistics (version 22.0, IBM Corp, Armonk, NY) was used for statistical analyses. The conformity of parameters to the normal distribution was assessed using the Shapiro-Wilks test. To compare the mean values between time points, paired *t*-tests and Wilcoxon signed-rank tests were used for normally and non-normally distributed data, respectively. For statistical evaluation of T0, T1, and T2 differences, repeated measure analysis of variance was used for normally

Downloaded from http://meridian.allenpress.com/angle-orthodontist/article-pdf/doi/10.2319/111620-940.1/2808366/10.2319_111620-940.1.pdf by Marmara Univ user on 15 August 2021

Table 2. Definitions of the Planes and Measurements

	Definition
Planes	
Frankfurt horizontal plane (FHP)	A plane passing through right and left porion and right infraorbital points
Coronal plane	A plane passing through right and left porion points perpendicular to FHP
Midsagittal plane	A plane passing through nasion point perpendicular to FHP and coronal plane
Right cervical	A plane passing 1 mm cervical from the right molar furcation parallel to FHP
Right furcation	A plane passing from the right molar furcation parallel to FHP
Right 1	A plane passing 1 mm apical from the right molar furcation parallel to FHP
Right 2	A plane passing 2 mm apical from the right molar furcation parallel to FHP
Left cervical	A plane passing 1 mm cervical from the left molar furcation parallel to FHP
Left furcation	A plane passing from the left molar furcation parallel to FHP
Left 1	A plane passing 1 mm apical from the left molar furcation parallel to FHP
Left 2	A plane passing 2 mm apical from the left molar furcation parallel to FHP
Measurements	
Buccal alveolar bone thickness	Linear distance measured from the most external border of the buccal alveolar bone to the outermost aspect of the distobuccal and mesiobuccal roots of the first molars
Palatal alveolar bone thickness	Linear distance measured from the most external border of the palatal alveolar bone to the outermost aspect of the palatal roots of the first molars
Buccal alveolar height	Linear distance from the buccal cusp tip to the buccal alveolar bone crest
Palatal alveolar height	Linear distance from the palatal cusp tip to the palatal alveolar bone crest
Dental inclination	Angle between the line passing through the molar palatal root apex and palatal cusp and the vertical line parallel to the midsagittal plane
Buccal alveolar inclination	Angle between the line parallel to the long axis of buccal alveolar bone and the vertical line parallel to the midsagittal plane
Palatal alveolar inclination	Angle between the line parallel to the long axis of palatal alveolar bone and the vertical line parallel to the midsagittal plane

distributed data, and the Friedman test was used for non-normally distributed data. The Bonferroni correction was used to reduce the chances of obtaining false-positive results. Statistical significance was set at $P < .05$.

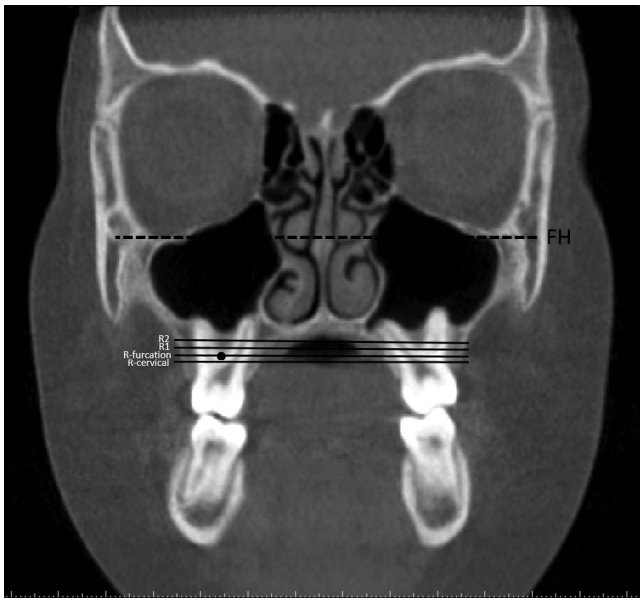

Figure 1. Four axial planes for measurement of buccal alveolar bone thickness and palatal alveolar bone thickness.

RESULTS

All measurements were repeated at a 1-week interval. Intraclass correlation coefficients for each variable ranged from 0.855 to 0.998, showing a high level of agreement.

Alveolar Bone Thickness

For both the right and left first molars, a significant decrease in BABT was measured at the mesiobuccal root in all four axial planes T1-T0. While there was no significant change T2-T1, the total reduction T2-T0 was statistically significant (Table 3).

On the distobuccal root, there was a statistically significant decrease in BABT for both molars T1-T0 except for the L-cervical plane. There was no significant change T2-T0 (Table 3).

The change in PABT at T1-T0 was not significant. The increase on both sides T2-T1 and T2-T0 was significant except for the cervical plane (Table 3).

Alveolar Bone Height

The BAH increased significantly (meaning the bone crest moved apically) by a mean of 0.43 $\pm$ 0.75 mm and 0.46 $\pm$ 0.67 mm for the right and left first molars, respectively, T1-T0 ($P < .05$). Although, there was no significant change T2-T1, the increase T2-T0 was

Downloaded from http://meridian.allenpress.com/angle-orthodontist/article-pdf/doi/10.2319/111620-940.1/2808366/10.2319_111620-940.1.pdf by Marmara Univ user on 15 August 2021



Figure 2. Measurement of buccal alveolar bone thickness and palatal alveolar bone thickness at the mesiobuccal, distobuccal, and palatal roots

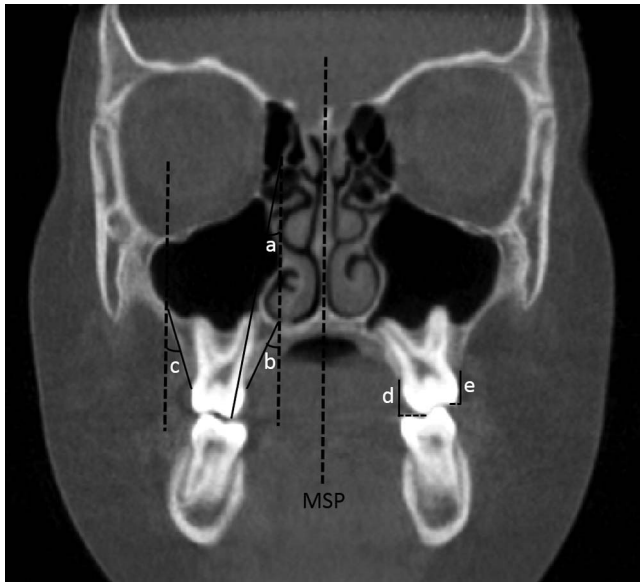

Figure 3. Measurement of dental and alveolar inclinations and buccal and palatal alveolar heights

Table 3. Evaluation of the Changes for Buccal and Palatal Alveolar Bone Thickness at T0, T1, and T2

Alveolar Bone Thickness, mm	T0, Mean ± SD	T1, Mean ± SD	T2, Mean ± SD	*P*	T1-T0 (*P*)	T2-T1 (*P*)	T2-T0 (*P*)
Buccal							
Mesiobuccal root							
Right cervical	2.46 ± 0.8	2.23 ± 0.8	2.3 ± 0.83	**[a]	–0.24 ± 0.48**[b]	0.08 ± 0.38	–0.16 ± 0.21*[b]
Right furcation	2.72 ± 0.98	2.3 ± 0.9	2.41 ± 0.97	**[a]	–0.42 ± 0.49**[b]	0.11 ± 0.51	–0.31 ± 0.28**[b]
Right 1	2.87 ± 1.1	2.46 ± 1.18	2.47 ± 1.12	**[a]	–0.4 ± 0.56**[b]	0 ± 0.45	–0.39 ± 0.36**[b]
Right 2	3.21 ± 1.29	2.78 ± 1.41	2.61 ± 1.29	**[a]	–0.43 ± 0.65**[b]	–0.16 ± 0.55	–0.59 ± 0.54**[b]
Left cervical	2.28 ± 0.68	2.1 ± 0.71	2.18 ± 0.7	**[a]	–0.18 ± 0.37*[b]	0.08 ± 0.41	–0.11 ± 0.2*[b]
Left furcation	2.41 ± 0.85	2.16 ± 0.81	2.25 ± 0.84	**[a]	–0.25 ± 0.21**[b]	0.08 ± 0.31	–0.16 ± 0.2*[b]
Left 1	2.64 ± 0.92	2.33 ± 0.99	2.36 ± 0.99	**[c]	–0.31 ± 0.21**[d]	0.3 ± 0.26	–0.28 ± 0.28**[d]
Left 2	2.98 ± 1.1	2.69 ± 1.03	2.59 ± 1.2	**[a]	–0.29 ± 0.54**[b]	–0.1 ± 0.69	–0.39 ± 0.36**[b]
Distobuccal root							
Right cervical	2.76 ± 0.62	2.5 ± 0.71	2.75 ± 0.52	**[a]	–0.26 ± 0.26**[b]	0.26 ± 0.49	0 ± 0.35
Right furcation	3.01 ± 0.61	2.76 ± 0.68	2.99 ± 0.64	**[a]	–0.26 ± 0.37**[b]	0.23 ± 0.52	–0.03 ± 0.35
Right 1	3.22 ± 0.73	2.97 ± 0.71	3.06 ± 0.67	*[a]	–0.25 ± 0.46*[b]	0.08 ± 0.43	–0.16 ± 0.4
Right 2	3.42 ± 0.87	3.14 ± 0.9	3.25 ± 0.85	*[a]	–0.28 ± 0.47*[b]	0.11 ± 0.48	–0.17 ± 0.44
Left cervical	2.8 ± 0.61	2.65 ± 0.65	2.81 ± 0.61	NS[c]	–0.14 ± 0.43	0.15 ± 0.38	0.01 ± 0.31
Left furcation	3.12 ± 0.74	2.87 ± 0.63	2.98 ± 0.6	*[a]	–0.25 ± 0.45*[b]	0.11 ± 0.35	–0.14 ± 0.29
Left 1	3.32 ± 0.62	3.06 ± 0.61	3.15 ± 0.69	**[c]	–0.26 ± 0.37*[d]	0.1 ± 0.34	–0.16 ± 0.27
Left 2	3.51 ± 0.74	3.31 ± 0.69	3.31 ± 0.81	*[c]	–0.2 ± 0.26*[d]	0 ± 0.37	–0.2 ± 0.43
Palatal							
Right cervical	2.23 ± 0.59	2.34 ± 0.59	2.43 ± 0.6	NS[a]	0.11 ± 0.36	0.09 ± 0.24	0.2 ± 0.44
Right furcation	2.09 ± 0.56	2.31 ± 0.6	2.46 ± 0.68	**[a]	0.21 ± 0.27	0.15 ± 0.35*[b]	0.37 ± 0.45**[b]
Right 1	2 ± 0.48	2.21 ± 0.57	2.41 ± 0.63	**[c]	0.21 ± 0.39	0.2 ± 0.34*[d]	0.41 ± 0.43**[d]
Right 2	1.95 ± 0.56	2.05 ± 0.59	2.32 ± 0.61	**[c]	0.09 ± 0.59	0.27 ± 0.42*[d]	0.37 ± 0.54*[d]
Left cervical	2.18 ± 0.39	2.29 ± 0.53	2.4 ± 0.48	NS[c]	0.11 ± 0.45	0.1 ± 0.32	0.22 ± 0.44
Left furcation	2.17 ± 0.45	2.2 ± 0.46	2.44 ± 0.54	**[c]	0.03 ± 0.39	0.24 ± 0.35*[d]	0.27 ± 0.44*[d]
Left 1	2.04 ± 0.58	2.16 ± 0.48	2.4 ± 0.47	**[a]	0.12 ± 0.47	0.25 ± 0.31**[b]	0.37 ± 0.59*[b]
L ft 2	2.01 ± 0.5	2.09 ± 0.43	2.35 ± 0.46	**[c]	0.08 ± 0.47	0.26 ± 0.28**[d]	0.33 ± 0.44*[d]

[a] Friedman test.
[b] Wilcoxon test.
[c] Repeated measures analysis of variance.
[d] Paired samples *t*-test.
* $P < .05$; ** $P < .01$; NS indicates not significant.

Downloaded from http://meridian.allenpress.com/angle-orthodontist/article-pdf/doi/10.2319/111620-940.1/2808366/10.2319_111620-940.1.pdf by Marmara Univ user on 15 August 2021

Table 4. Evaluation of the Buccal and Palatal Alveolar Bone Height Changes During Treatment Period

Alveolar Bone Height, mm	T0, Mean ± SD	T1, Mean ± SD	T2, Mean ± SD	*P*	T1-T0 (*P*)	T2-T1 (*P*)	T2-T0 (*P*)
Buccal							
Right	7.24 ± 0.9	7.67 ± 1.14	7.62 ± 0.78	*[a]	0.43 ± 0.75*[b]	–0.05 ± 0.74	0.38 ± 0.57*[b]
Left	7.34 ± 1.19	7.8 ± 0.94	7.8 ± 0.78	**[c]	0.46 ± 0.67*[d]	0 ± 0.62	0.46 ± 0.84*[d]
Palatal							
Right	7.23 ± 1.02	7.66 ± 1.09	7.7 ± 0.85	**[c]	0.43 ± 0.49**[d]	0.05 ± 0.55	0.48 ± 0.44**[d]
Left	7.37 ± 1.11	8.05 ± 1.04	7.66 ± 1.47	**[a]	0.68 ± 0.65**[b]	–0.39 ± 1.21	0.29 ± 1.3**[b]

[a] Friedman test.
[b] Wilcoxon test.
[c] Repeated measures analysis of variance.
[d] Paired samples *t*-test.
* $P < .05$; ** $P < .01$.

significant (0.38 ± 0.57 mm and 0.46 ± 0.84 mm, respectively) (Table 4).

PAH increased significantly (meaning the bone crest moved apically) by a mean of 0.43 ± 0.49 mm and 0.68 ± 0.65 mm for the right and left molars, respectively, T1-T0 ($P < .01$). There was no significant change T2-T1. However, when the total treatment was evaluated (T2-T0), the increases were significant, with a mean value of 0.48 ± 0.44 mm and 0.29 ± 1.3 mm for the right and left first molars, respectively ($P < .01$) (Table 4).

Dental and Alveolar Bone Inclinations

The inclination of both the right and left first molars increased significantly T1-T0 (2.2 ± 1.63° and 2.44 ± 1.18°, respectively; $P < .01$). Although the dental inclinations decreased during FM treatment (T2-T1), the changes were not significant. The increase in dental inclination was significant for both molars T2-T0 (Table 5).

A significant decrease in buccal alveolar bone inclination and increase in palatal alveolar bone inclination were seen for both molars T1-T0 (Table 5). Similar to dental inclinations, there were no significant changes in alveolar inclination T2-T1, while the overall changes T2-T0 were significant (Table 5).

DISCUSSION

Orthopedic expansion is the most desired effect of RPE. However, dentoalveolar changes such as decreases in BABT and BAH, increase in PABT, increases in buccal dental and alveolar inclinations are reported to occur after expansion.[4–13] While the effects of RPE have been the subject of many studies in the literature, only two studies have evaluated dentoalveolar changes after the Alt-RAMEC protocol.[7,15] The aim of the current study was to define and document the dentoalveolar changes due to the expansion and constriction sets immediately after the Alt-RAMEC protocol (T1-T0) and subsequent FM treatment (T2-T1).

The decrease in BABT was significant for all axial planes on the mesiobuccal root and the distobuccal root except the L-cervical plane for both molars T1-T0. Gandedkar and Liou[15] reported a significant decrease in BABT only in the two cervical planes for both the mesiobuccal and distobuccal roots. The difference between the two studies might be related to appliance design and the number of expansion and constriction sets. In the present study, an acrylic cap double-hinged expander was used for a 9-week Alt-RAMEC protocol, while Gandedkar and Liou[15] used a banded expander for a 7-week protocol, which may explain the bone reduction observed at all levels in the present study. In another study, by Rinaldi et al.,[7] a significant decrease

Table 5. Evaluation of Dental and Alveolar Bone Inclinations

Inclination, °	T0, Mean ± SD	T1, Mean ± SD	T2, Mean ± SD	*P*	T1-T0 (*P*)	T2-T1 (*P*)	T2-T0 (*P*)
Dental							
Right	14.51 ± 4.14	16.51 ± 4.42	16.12 ± 4.27	**[a]	2 ± 2.1.63**[b]	–0.39 ± 0.34	1.6 ± 1.65**[b]
Left	16.06 ± 3.4	18.5 ± 3.39	18.2 ± 3.42	**[a]	2.44 ± 1.18**[b]	–0.3 ± 0.61	2.14 ± 1.17**[b]
Alveolar							
Right buccal	17.59 ± 3.21	16.67 ± 4.03	16.35 ± 3.46	**[a]	–0.92 ± 2.53*[b]	–0.32 ± 2.3	–1.24 ± 1.26**[b]
Left buccal	18.78 ± 4.7	16.81 ± 5.12	16.95 ± 5.02	**[a]	–1.97 ± 1.6**[b]	0.14 ± 0.65	–1.83 ± 1.46**[b]
Right palatal	23.49 ± 4.99	26.32 ± 5.93	25.93 ± 5.16	**[a]	2.83 ± 3.96**[b]	–0.39 ± 2.48	2.44 ± 2.91**[b]
Left palatal	23.1 ± 5.91	26.47 ± 6.67	26.21 ± 6.05	**[a]	3.37 ± 2.49**[b]	-0.26 ± 2.67	3.11 ± 1.73**[b]

[a] Friedman test.
[b] Wilcoxon test.
* $P < .05$; ** $P < .01$.

Downloaded from http://meridian.allenpress.com/angle-orthodontist/article-pdf/doi/10.2319/111620-940.1/2808366/10.2319_111620-940.1.pdf by Marmara Univ user on 15 August 2021

in BABT on the mesiobuccal root was measured after expansion in all groups. However, the Alt-RAMEC group had more fenestrations and dehiscences compared with other expansion methods. The results of this study agreed with most of the previous literature and showed a significant reduction in BABT immediately after expansion. However, the amount of reduction in previous studies generally ranged from 0.6 mm to 1.25 mm, which was greater than that observed in the present study.[5,8,9,12,13,16] These differences can be attributed to the differences between the expansion protocols, appliance designs, patient ages, and timing of the records. In addition, the consecutive expansion and constriction sets in the Alt-RAMEC protocol in the present study may have relieved the pressure that accumulated in the alveolar bones, thus resulting in less reduction in BABT.

During FM treatment, there was no significant change in BABT. Overall (T2-T0), however, there was a significant decrease in thickness on the mesiobuccal root for all axial planes, while there was no significant change on the distobuccal root. Baysal et al.[4] also found that the buccal alveolar bone generally continued to decrease after the retention period. The reduction in BABT on the mesiobuccal root might have been due to residual loads and relapse forces that caused compression of the buccal alveolar bone of anchor teeth that were held rigidly by the appliance.[17] Also, due to the position of the upper first molars, the mesiobuccal root was more directly related to the buccal alveolar bone plate and was bulkier than the distobuccal root, which made the mesiobuccal root more prone to alveolar resorption.[7] Significant recovery was shown by long-term studies of alveolar bone reduction in the literature.[8,12,18] However, most of those studies evaluated the alveolar changes after fixed treatment, which included longer follow-up periods than the present study, and a subsequent increase in buccal bone width due to uprighting of the molars after appliance removal was reported.[12,18] The records in the current study were taken with the appliance in place; therefore, no molar uprighting was anticipated. On the other hand, Rungcharassaeng et al.[5] argued that retention time had no significant association with buccal bone changes.

There was no statistically significant change in PABT immediately after Alt-RAMEC, while significant increases were found T2-T1 and T2-T0, except for the cervical plane of both molars. In contrast, Gandedkar and Liou[15] found PABT thickening at the cervical level of first molars after Alt-RAMEC. As with the BABT, these differences in results between the two studies may be attributed to the appliance design (acrylic cap or banded), the number of expansion and constriction sets, and the retention period. The increases in PABT with time were in agreement with other studies that evaluated alveolar bone changes after RPE.[4,9,13] However, Baysal et al.[4] reported that, although an increase was observed in PABT after the active phase of RPE, there was a decrease during the retention period, and that decrease was explained as being due to compensatory resorption under the periosteum.

Significant increases in dental inclination were seen T1-T0 due to buccal crown tipping of the molars, which was similar to that found in the study of Rinaldi et al.,[7] where greater buccal crown inclinations were observed in the Alt-RAMEC group. Additionally, although Gandedkar and Liou[15] did not measure dental inclinations specifically, they observed buccal crown tipping of the posterior anchor teeth. During FM treatment (T2-T1), there were no significant changes in dental inclination because the appliance held the teeth rigidly. For increases in buccal inclination of the molars overall T2-T0, the results of the present study were compatible not only with the Alt-RAMEC studies[7,15] but also with the RPE studies in the literature.[5,9,13,18] In contrast, Kartalian et al.[6] reported no significant dental tipping, but significant alveolar tipping, after RPE. In the current study, an increase in palatal alveolar bone inclination and a decrease in buccal alveolar bone inclination were observed, resulting in buccal tipping of both alveolar bone plates. There was no available study in the literature with which to compare alveolar tipping after the Alt-RAMEC protocol. However, the current results regarding alveolar bone were similar to that observed in studies using an RPE protocol.[5,6,10,13] Similar to dental inclination, no significant change was observed in alveolar inclination during FN treatment, whereas there were significant changes overall T2-T0. As no previous studies evaluated alveolar bone inclination long term, the results could not be compared.

Dental and alveolar tipping were reported to lead to resorption of the alveolar crest, thus creating an increase in the distance between the alveolar crest and the molar cusp tip.[4,5,9,16] While significant increases were found for both BAH and PAH immediately after Alt-RAMEC in the present study, Rinaldi et al. [7] only evaluated BAH and reported a significant increase in the Alt-RAMEC group compared with other groups. All the previous studies only evaluated the BAH and found that the level of alveolar crest was lowered by different amounts after RPE,[4,5,9,16] which was in agreement with the present study. A long-term study by Nguyen et al.[12] showed that BAH recovered back to its initial values after removal of RPE appliances. In contrast, Baysal et al.[4] reported that BAH did not change after the retention period. In the current study, BAH and PAH remained the same during FM treatment. However, after FM treatment, measurements for BAH and PAH

Downloaded from http://meridian.allenpress.com/angle-orthodontist/article-pdf/doi/10.2319/111620-940.1/2808366/10.2319_111620-940.1.pdf by Marmara Univ user on 15 August 2021

were significantly greater than the initial values (meaning loss of vertical bone height).

The authors of the present study advocate that individuals should not receive extra doses of radiation beyond that needed for diagnosis and treatment. No new records were taken for experimental purposes in this study due to its retrospective design. Therefore, the study was set in accordance with the principle of ALARA (as low as reasonably achievable). CBCT scanning provides reliable and accurate three-dimensional information of the tissues, especially bony changes, without the superimposition of anatomical structures that make it otherwise difficult to obtain accurate measurements in two-dimensional images.[19] Leung et al.[19] reported that the correlation coefficient with direct and CBCT measurements was 0.870 for bone margin measurements. However, the detection of fenestrations and dehiscences was more prone to error. For dehiscences, both sensitivity and specificity were about 0.80.[19] Wood et al. [20] concluded that, for 0.4-mm voxel-size scans, measurements were generally within 1 mm from the physical truth, with a 10% frequency of obtaining clinically inaccurate measurements ($\geq$1 mm). Some authors have observed that decreasing the voxel size improved the accuracy of alveolar bone linear measurements and recommended that a voxel size $<$0.30 mm could provide better average spatial resolution for adequately visualizing alveolar bone.[20–22] In the current study, the voxel size was set at 0.0936 mm to obtain accurate bone measurements.

The limitations of this study were its small sample size and that the magnitude of the dentoalveolar measurements were on an extremely small scale. To overcome these limitations, the same operator measured all parameters, with a reportedly high reliability, and repeated measure analysis of variance was used to prevent the underestimation of *P*-values.[4] BABT and PABT were measured in four axial planes to evaluate the effects of the Alt-RAMEC protocol on the entire alveolar bone,[16] and measures were taken to prevent position-related errors between the time points.[11,13] Nonetheless, the scoring of these thicknesses may have been another possible limitation of the current study due to CBCT-related factors. In future studies, it would be beneficial to evaluate dentoalveolar changes after comprehensive treatment with fixed appliances, with a larger sample size and longer follow-up period.

Detrimental dentoalveolar effects can be expected due to repetitive expansion and constriction sets with a rigid appliance in the Alt-RAMEC protocol. Nevertheless, the results of this study revealed that the amount of dentoalveolar changes were similar to those found after RPE, demonstrating that the impacts of Alt-RAMEC on the dentoalveolar tissues were comparable. Additionally, clinical significance of the results should also be considered. There was vertical bone loss and a decrease in bone thickness on the anchor teeth due to a lack of orthopedic response. Therefore, it is essential to start treatment of maxillary constriction as early as possible, regardless of the protocol.

CONCLUSIONS

- A significant reduction in BABT was found on the mesiobuccal root of both right and left molars T1-T0 and T2-T0.
- A significant reduction in BABT was found on the distobuccal root of both molars, except for the L-cervical plane, T1-T0. However, bone thickness approached regaining its initial level at T2.
- While a nonsignificant increase was found in PABT T1-T0, a significant increase was found T2-T0.
- Significant buccal tipping was observed for buccal and palatal alveolar bones and molars T1-T0, and significant buccal tipping remained for alveolar bone and molars overall T2-T0.
- There was significant vertical bone loss on the buccal and palatal aspects of molars T1-T0, and significant bone loss remained overall T2-T0.

ACKNOWLEDGMENTS

The authors thank Dr. Nazan Küçükkeleş, Dr. Berza Yılmaz, Dr. Vasiliki Sitaropoulou for their contribution to the archive.

REFERENCES

1. Isaacson RJ, Ingram AH. Forces produced by rapid maxillary expansion: II. Forces present during treatment. *Angle Orthod*. 1964;34:261–270.
2. Haas AJ. Palatal expansion: just the beginning of dentofacial orthopedics. *Am J Orthod Dentofacial Orthop*. 1970;57:219–255.
3. Melsen B, Melsen F. The postnatal development of the palatomaxillary region studied on human autopsy material. *Am J Orthod*. 1982;82:329–342.
4. Baysal A, Uysal T, Veli I, Ozer T, Karadede I, Hekimoglu S. Evaluation of alveolar bone loss following rapid maxillary expansion using cone-beam computed tomography. *Korean J Orthod*. 2013;43:83–95.
5. Rungcharassaeng K, Caruso JM, Kan JY, Kim J, Taylor G. Factors affecting buccal bone changes of maxillary posterior teeth after rapid maxillary expansion. *Am J Orthod Dentofacial Orthop*. 2007;132:428.e421–428.e428.
6. Kartalian A, Gohl E, Adamian M, Enciso R. Cone-beam computerized tomography evaluation of the maxillary dentoskeletal complex after rapid palatal expansion. *Am J Orthod Dentofacial Orthop*. 2010;138:486–492.
7. Rinaldi MRL, Azeredo F, de Lima EM, Rizzatto SMD, Sameshima G, de Menezes LM. Cone-beam computed tomography evaluation of bone plate and root length after maxillary expansion using tooth-borne and tooth-tissue-

Downloaded from http://meridian.allenpress.com/angle-orthodontist/article-pdf/doi/10.2319/111620-940.1/2808366/10.2319_111620-940.1.pdf by Marmara Univ user on 15 August 2021

borne banded expanders. *Am J Orthod Dentofacial Orthop*. 2018;154:504–516.
8. Ballanti F, Lione R, Fanucci E, Franchi L, Baccetti T, Cozza P. Immediate and post-retention effects of rapid maxillary expansion investigated by computed tomography in growing patients. *Angle Orthod*. 2009;79:24–29.
9. Garib DG, Henriques JFC, Janson G, de Freitas MR, Fernandes AY. Periodontal effects of rapid maxillary expansion with tooth-tissue-borne and tooth-borne expanders: a computed tomography evaluation. *Am J Orthod Dentofacial Orthop*. 2006;129:749–758.
10. Garib DG, Henriques JFC, Janson G, Freitas MR, Coelho RA. Rapid maxillary expansion—tooth tissue-borne versus tooth-borne expanders: a computed tomography evaluation of dentoskeletal effects. *Angle Orthod*. 2005;75:548–557.
11. Podesser B, Williams S, Crismani AG, Bantleon H-P. Evaluation of the effects of rapid maxillary expansion in growing children using computer tomography scanning: a pilot study. *Eur J Orthod*. 2007;29:37–44.
12. Nguyen B, Kadioglu O, Currier GF, Olsen J. Cone beam computed tomography evaluation after palatal expansion and orthodontics. *J World Fed Orthod*. 2013;2:e9–e13.
13. Toklu MG, Germec-Cakan D, Tozlu M. Periodontal, dentoalveolar, and skeletal effects of tooth-borne and tooth-bone-borne expansion appliances. *Am J Orthod Dentofacial Orthop*. 2015;148:97–109.
14. Liou EJ-W, Tsai W-C. A new protocol for maxillary protraction in cleft patients: repetitive weekly protocol of alternate rapid maxillary expansions and constrictions. *Cleft Palate Craniofac J*. 2005;42:121–127.
15. Gandedkar NH, Liou EJ-W. The immediate effect of alternate rapid maxillary expansions and constrictions on the alveolus: a retrospective cone beam computed tomography study. *Prog Orthod*. 2018;19:40.
16. Pangrazio-Kulbersh V, Jezdimir B, de Deus Haughey M, Kulbersh R, Wine P, Kaczynski R. CBCT assessment of alveolar buccal bone level after RME. *Angle Orthod*. 2013; 83:110–116.
17. Barber AF, Sims M. Rapid maxillary expansion and external root resorption in man: a scanning electron microscope study. *Am J Orthod*. 1981;79:630–652.
18. Akyalcin S, Schaefer JS, English JD, Stephens CR, Winkelmann S. A cone-beam computed tomography evaluation of buccal bone thickness following maxillary expansion. *Imaging Sci Dent*. 2013;43:85–90.
19. Leung CC, Palomo L, Griffith R, Hans MG. Accuracy and reliability of cone-beam computed tomography for measuring alveolar bone height and detecting bony dehiscences and fenestrations. *Am J Orthod Dentofacial Orthop*. 2010; 137:S109–S119.
20. Wood R, Sun Z, Chaudhry J, et al. Factors affecting the accuracy of buccal alveolar bone height measurements from cone-beam computed tomography images. *Am J Orthod Dentofacial Orthop*. 2013;143(3):353–363.
21. Sun Z, Smith T, Kortam S, Kim DG, Tee BC, Fields H. Effect of bone thickness on alveolar bone-height measurements from cone-beam computed tomography images. *Am J Orthod Dentofacial Orthop*. 2011;139:e117–e127.
22. Molen AD. Considerations in the use of cone-beam computed tomography for buccal bone measurements. *Am J Orthod Dentofacial Orthop*. 2010;137:130–135.

Downloaded from http://meridian.allenpress.com/angle-orthodontist/article-pdf/doi/10.2319/111620-940.1/2808366/10.2319_111620-940.1.pdf by Marmara Univ user on 15 August 2021