doi:10.1510/icvts.2008.198598

INTERACTIVE CARDIOVASCULAR AND THORACIC SURGERY

Interactive CardioVascular and Thoracic Surgery 8 (2009) 498–500

www.icvts.org

Case report - Cardiac general

Right ventricular mural endocarditis presenting as an isolated apical mass in a non-addict patient with congenital deafness and aphasia

Koray Ak, Taylan Adademir, Selim İsbir, Sinan Arsan*

Department of Cardiovascular Surgery, Marmara University School of Medicine, Istanbul, Turkey

Received 14 November 2008; received in revised form 19 December 2008; accepted 22 December 2008

Abstract

Right heart infective endocarditis presenting as an isolated apical mural mass is an extremely uncommon finding. A 24-year-old woman with congenital deafness and aphasia was admitted with recurrent attacks of fever and lobar pneumonia. Her past medical history was significant for an open operation for left nephrolithiasis five months before admission. She had no history of congenital heart defect, intravenous drug use or central venous line insertion. Diagnostic workup revealed a large pedunculated solid mass attached to the apex of the right ventricle and multiple septic foci in both lungs. Repeated blood cultures were negative. In spite of aggressive antibiotic therapy, she had progressively worsening respiratory distress. She was successfully operated for the mass and the pathologic findings were consistent with endocarditis. To our knowledge, the anatomical location of the mural endocarditis (apex of right ventricle) is a pretty uncommon condition.

© 2009 Published by European Association for Cardio-Thoracic Surgery. All rights reserved.

Keywords: Mural endocarditis; Mass; Right ventricle

1. Case

A 24-year-old woman with congenital deafness and aphasia was admitted with productive cough, recurrent high fever and chills. In her past medical history, she had an open operation for left nephrolithiasis five months before admission and the early postoperative course was totally uneventful. Her symptoms had begun one month after this operation. The patient had been hospitalized and empirically treated with intravenous broad-spectrum antibiotics for suspected pneumonia before admission. She was unresponsive to the treatment and her general clinical status had progressively worsened. Her social history was not significant. On physical examination, she was febrile (39.1 °C) and dyspneic (respiratory rate of 22 per min). Blood pressure was 145/80 mmHg and pulse was 96/min. She had jugular venous distension. Chest auscultation revealed course respiratory sounds at the basal zones of both lungs. Abdominal examination revealed hepatomegaly (3.5 cm below the costal cartilage in the midclavicular line). Examination of the heart and extremities were unremarkable. Radiography of the chest showed a patchy infiltrate of the right lower lobe. The electrocardiogram did not demonstrate any specific changes. Complete blood count revealed a hematocrit of 28.6% and a leukocyte count of 19,300/μl with 90% neutrophiles. Biochemical tests, including electrolytes, liver function tests, creatinine, and blood urea were all within normal limits. Erythrocyte sedimentation rate (ESR) was 96 mm/h and C-reactive protein (CRP) level was 164.4 mg/l. Urine analysis revealed pyuria and bacteriuria. Urine culture was positive for Escherichia coli that was highly sensitive to Imipenem. Sputum cultures and repeated blood cultures withdrawn during the fever spikes were all negative. Additionally, the diagnostic tests for tuberculosis, including tuberculin test, acid-resistant bacillus (ARB) in sputum, polymerase chain reaction and blood culture were not significant.

Transthoracic echocardiography (TTE) showed a large (32$\times$27 mm), slightly mobile and solid mass attached to the apical part of the right ventricular septum with a short stalk. Tricuspid and pulmonary valves were morphologically normal. There was a moderate tricuspid valve insufficiency. There was no evidence of a congenital defect or other cardiac pathology. The patient did not have a central venous line during her nephrolithiasis operation. Cardiac magnetic resonance imaging (MRI) findings were consistent with those seen on the TTE (approximately 35$\times$30 mm in size, almost circular, strongly echo-contrast and solid mass extending to the right ventricular outflow tract) (Fig. 1a,b). Computed tomography of the chest revealed bilateral and multiple patchy pulmonary infiltrates. Computed tomography of the abdomen and pelvis was unremarkable. Differential diagnosis of the mass included mural vegetation related to infective endocarditis or solid cardiac tumor. An empiric intravenous antibiotic regimen was started (vancomycin + imipenem). Urine culture taken after one week of the treatment was negative. Despite intravenous anti-

*Corresponding author. Marmara Universitesi Hastanesi, Kalp ve Damar Cerrahisi AD, Tophanelioglu cad. No: 13-15, 34640, Altunizade, Istanbul, Turkey.

E-mail address: sinanarsan@superonline.com, akkoray@hotmail.com (S. Arsan).

© 2009 Published by European Association for Cardio-Thoracic Surgery

Downloaded from https://academic.oup.com/icvts/article-abstract/8/4/498/811929 by guest on 02 April 2020

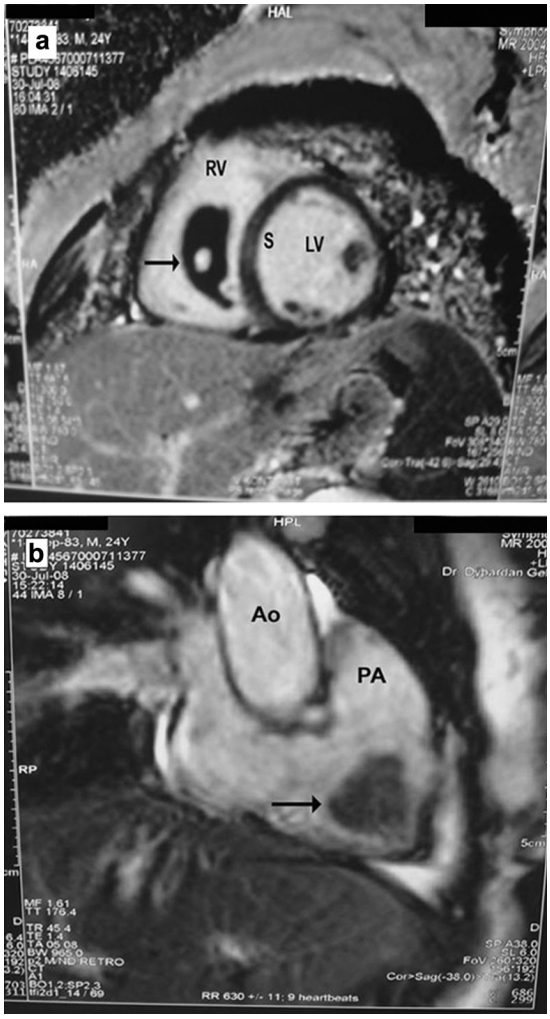

Fig. 1. Cardiac magnetic resonance images (a and b) show right ventricular apical mass related to mural endocarditis. Arrows indicate mural mass (RV, right ventricle; S, septum; LV, left ventricle; Ao, ascending aorta; PA, pulmonary artery).

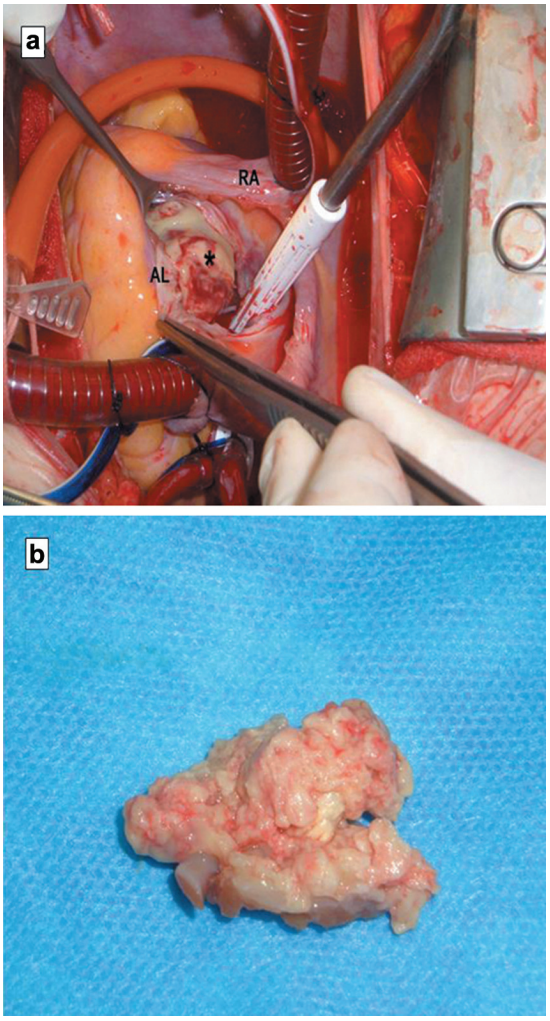

Fig. 2. (a) Intraoperative view of right ventricular mass (*) through a standard right atriotomy (RA) and tricuspid valve (AL, anterolateral leaflet of tricuspid valve), (b) Macroscopic view of the mass after excision.

biotics for two weeks, the patient continued to have fevers, elevated ESR, CRP and WBC. Additionally, her pulmonary status worsened and nasal oxygen requirement was increased (from 1 to 3–4 l/min). A repeat TTE revealed no change in the mass.

The patient underwent surgery. After median sternotomy, aorto-bicaval cannulation and cardiopulmonary bypass (CPB), the patient was cooled to 30 °C. After aortic cross-clamping and antegrade cold-blood cardioplegia, a standard right atriotomy was performed. A pedunculated mass originating from the apex of the right ventricle was exposed and excised with a substantial portion of the normal myocardium (Fig. 2). The tricuspid and pulmonary valves appeared normal. Aortic cross-clamping and CPB times were 29 and 55 min, respectively.

Pathologic examination of the mass revealed acute inflammatory changes involving endocardium and myocardium and an organized thrombus along with fibrous tissue with no evidence of infective organisms. After the operation, the patient was treated for four weeks with intravenous antibiotics and had an excellent clinical response. Culture of the pathologic specimen was also negative. Control TTE at discharge from hospital revealed completely normal right ventricular cavity and a trivial to mild tricuspid valve insufficiency.

2. Comment

In the modern antibiotic era, infective endocarditis still continues to result in considerable morbidity and mortality. It is characterized by invasion or colonization of endocardial surfaces, either valvular or non-valvular, by a microbiologic agent. Non-valvular mural endocarditis is an extremely uncommon condition and may be seen in all cardiac chambers. It develops secondary to several predisposing conditions like high velocity intracardiac regurgitant jets, congenital shunts, ventricular aneurysms or pseudoaneurysms, idiopathic hypertrophic subaortic stenosis, systemic immunosuppression, and pacemakers [1]. Alternatively, mural endocarditis may result as an extension of infection from underlying myocardial abscesses in critically ill patients [2].

Downloaded from https://academic.oup.com/icvts/article-abstract/8/4/498/811929 by guest on 02 April 2020

Hematogenous infection of normal mural endocardium without an anatomic substrate or systemic immunosuppression has been reported to be exceptional. Uppal and associates [3] reported isolated right ventricular outflow tract vegetation in a 34-year-old man with no history of congenital heart defect or intravenous drug abuse. Ahmed and associates [4] reported a case of biventricular mural vegetations in a 40-year-old patient with no known predisposing conditions. They claimed that bacteremia related to previous central venous catheterization was the main reason for the development of mural vegetations in their patient. Similarly, other investigators have stressed the potential risks of mural thrombi and non-bacterial thrombotic endocarditis in right heart chambers after central venous catheterization [5]. Our patient had no history of drug use and central venous catheterization. Also, there were no evidence of underlying cardiac abnormality and systemic immunosuppression. We presume that silent bacteremia after renal operation played a role in initiating the development of the apical mural mass.

We could not reveal any microbial agent in our case. The most common pathogens associated with mural endocarditis are staphylococci, viridans streptococci, Enterococcus spp., Salmonella spp., Bacteroides fragilis, Candida spp., and Aspergillus spp. [1–3]. In patients with fungal mural endocarditis, blood cultures are infrequently positive (7–16%) and there is often an associated myocardial abscess. The most common presenting symptoms are fever and chills. Peripheral embolization (to lungs or systemic circulation) is not infrequent in such patients. As in our case, in patients with a right heart mural endocarditic mass, productive cough or hemoptysis related to continued septic pulmonary embolization might be the initial presenting findings [3]. Differential diagnosis of the mass included thrombus, cardiac tumors like myxoma, lipoma, angiosarcomas, metastases, mural endocarditis and myocardial abscess. Currently, TTE and cardiac MRI are commonly used diagnostic tools in the initial evaluation of a non-valvular mural mass. Furthermore, for apical endocarditic masses, TTE is regarded to be superior to transesophageal echocardiography (TEE). This is because apical regions of both ventricles are often foreshortened on TEE [4].

Prognosis in mural endocarditis has been reported to be dismal. Meticulous monitoring with aggressive medical management is the initial way of treatment for these cases. Surgery is promptly regarded in patients with worsening oxygenation and hemodynamics or unresponsiveness to medical therapy.

References

[1] Kearney RA, Eisen HJ, Wolf JE. Non-valvular infections of the cardiovascular system. Ann Intern Med 1994;121:219–230.
[2] Buchbinder NA, Roberts WC. Active infective endocarditis confined to mural endocardium. A study of six necropsy patients. Arch Pathol 1972; 93:435–440.
[3] Uppal KM, Nuño IN, Schwartz DS, Ashton KA, Starnes VA. Isolated right ventricular outflow tract mass presenting as hemoptysis. Ann Thorac Surg 2000;70:2158–2159.
[4] Ahmed I, Katz DH, Crooke GA, Li M, Doddamani S, Haramati LB, Ostfeld RJ, Gordon GM, Spevack DM. Biventricular mural vegetations in a patient without valvular pathology. J Am Soc Echocardiogr 2006;19: 938.e5–e7.
[5] Raad II, Luna M, Khalil SA, Costerton JW, Lam C, Bodey GP. The relationship between the thrombotic and infectious complications of central venous catheters. J Am Med Assoc 1994;271:1014–1016.

Downloaded from https://academic.oup.com/icvts/article-abstract/8/4/498/811929 by guest on 02 April 2020