Expansion of the phenotypic spectrum of *SCM1A* nonsense variants: a patient with cerebellar atrophy and review of the literature

Ayberk Türkyılmaz[a], Dilşad Türkdoğan[b], Zeliha Görmez[c] and Gazanfer Ekinci[d]

Clinical Dysmorphology 2020, **XXX**:000–000

Departments of [a]Medical Genetics, [b]Pediatric Neurology, Marmara University School of Medicine, Pendik, İstanbul, Turkey, [c]Bioinformatics, Private Practice and [d]Department of Neuroradiology, Marmara University School of Medicine, Pendik, İstanbul, Turkey

Correspondence to Ayberk Turkyilmaz, MD, Department of Medical Genetics, Marmara University School of Medicine, Pendik, Istanbul, Turkey
Tel: +905058120334; fax; +902166254545; e-mail: ayberkturkyilmaz@gmail.com

Received 18 February 2019 **Accepted** 27 April 2020

List of key features

Epilepsy
SMC1A nonsense mutation
Long eyelashes
Coarse facies

Case report

The proband, aged 7 years, born at 39 weeks and 3150 g birth weight as the second child of nonconsanguineous Turkish parents with an unremarkable family history. The antenatal and perinatal period was uneventful. She presented with multiple focal motor seizures with secondary generalization evolving to status epilepticus in the same day at 8 months of age.

The family noticed neurodevelopmental delay at 5 months of age characterized by lack of head control, voluntary hand functions and eye tracking. She gained head control and mild social smile at 7 months of age. Clusters of intractable seizures caused regression of previously achieved milestones. Neurological examination currently shows severely delayed motor functions with diffuse severe hypotonia, lack of sitting without assistance, voluntary hand functions, visual contact, social jests or vocalization. Physical examination demonstrates a height of 107 cm (−2.76 SD), weight of 15 kg (−2.86 SD) and head circumference of 48 cm (−2.78 SD), scoliosis with the following dysmorphic features; coarse facies, long and prominent eyelashes, anteverted nares, widely spaced teeth, hirsutismus on forehead and neck, tapering fingers, proximally placed thumbs and hammer toes, but no congenital malformations (Fig. 1).

Investigations

All experimental procedures were conducted in accordance with recommendations of Ethics Committee of Marmara University and informed consent was obtained from parents.

Consequent electroencephalographys revealed simultaneous or sequential independent focal electrographic

Fig. 1



Photograph of the patient. Notice the coarse facies, long and prominent eyelashes, anteverted nares and sparse teeth.

0962-8827 Copyright © 2020 Wolters Kluwer Health, Inc. All rights reserved.

DOI: 10.1097/MCD.0000000000000326

Copyright © 2020 Wolters Kluwer Health, Inc. Unauthorized reproduction of this article is prohibited.

Fig. 2

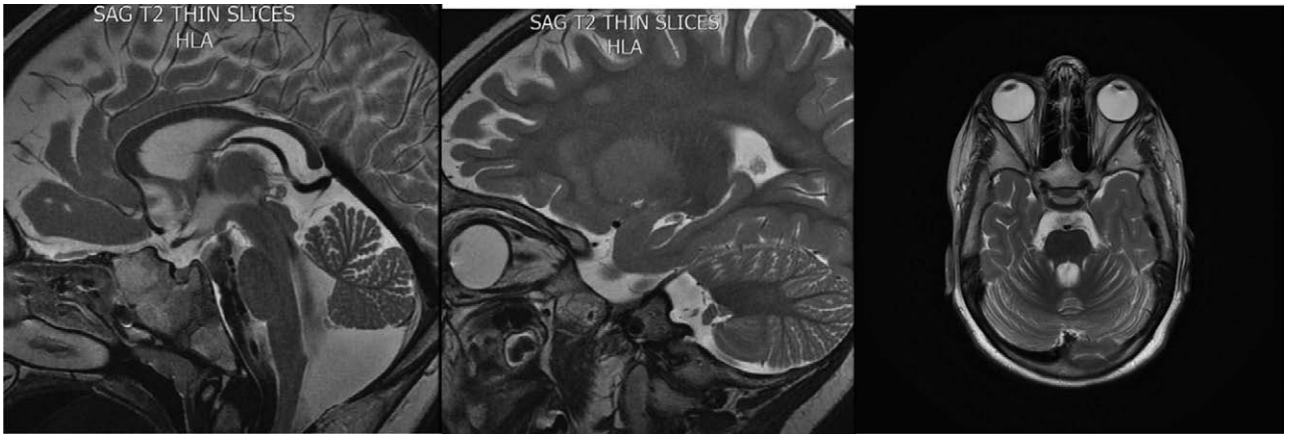

Prominent cerebellar atrophy characterized by deepened sulci and folia of vermis and the hemispheres. Sagittal T2 weighted images of the patient shows atrophy of cerebellum and vermis evidenced by prominent cerebellar foliae.

seizures or status epilepticus originating from different regions and generalized background slowing.

Ophthalmologic examination is normal. Flash VEP demonstrates prolonged latency of P100 wave representing optic nerve conduction deficiency. Hearing examination, echocardiography, abdomen ultrasonography and skeletal surveys are normal.

Cranial MRI done at 9 months of age was unremarkable, whereas at 6.5 years, MRI showed prominent cerebellar atrophy characterized by deepened sulci and folia of vermis and the hemispheres (Fig. 2).

Metabolic screening including cerebrospinal fluid examinations, karyotype and chromosomal microarray were inconclusive. She was analyzed by whole exome sequencing as a part of a project aimed at genetic analysis of early onset epilepsy patients.

A previously reported de-novo heterozygous nonsense variant (Chr X: 53421748C>T GRCh37/hg19; NM_006306: c.2923C>T; NP_006297: p.Arg975*) in exon 19 of *SMC1A* was detected (Symonds *et al.*, 2017). The present variant was confirmed by Sanger sequencing. Her unaffected parents were normal for this variant.

Discussion

Pathogenic missense variants and small in-frame deletions in *SMC1A* have previously been identified in individuals with Cornelia De Lange syndrome. However, truncating variants produce a different condition characterized by severe epilepsy or intellectual disability (de Ligt *et al.*, 2012; Hansen *et al.*, 2013; Gilissen *et al.*, 2014; Jang *et al.*, 2015; Tzschach *et al.*, 2015; Lebrun *et al.*, 2015; Jansen *et al.*, 2016; Goldstein *et al.*, 2015; Fieremans *et al.*, 2016; Wenger *et al.*, 2017).

The phenotype of refractory seizures seems to be related with the type of *SMC1A* mutations. Loss of function or splice mutations cause early onset epilepsy (Hansen *et al.*, 2013) and sometimes epileptic encephalopathy (Lebrun *et al.*, 2015) (Table 1). The present case with the identical mutation reported by Symonds *et al.* (2017) as case 6, has some similar clinical features like facial dysmorphic findings, type of the seizure and severe developmental regression and acquired microcephaly (Table 1).

In the literature, patients that have SMC1A nonsense mutations have microcephaly, severe intellectuel disability, unrecognizable facial features and no gross structural brain abnormalities except mild cerebral atrophy or vermis hypoplasia (Deardorff *et al.*, 2007; Pavlidis *et al.*, 2014; Jansen *et al.*, 2016; Symonds *et al.*, 2017) (Table 1). Our case has progressive atrophy of cerebellar hemispheres and vermis which has not been reported in previous cases.

The present mutation leads to a premature stop codon and is predicted to result in a truncation of *SMC1A* protein. Symonds *et al.* (2017) speculated that truncated *SMC1A* escapes nonsense-mediated decay, and exerts a dominant negative effect. *SMC1A* is a component of the cohesion complex, which regulates transcription of a large number of other genes. To understand molecular mechanism, further functional studies should be done.

The present patient with a novel radiological finding was reported to contribute to genotype-phenotype correlations, and to clarify and expand phenotypic features in *SMC1A* truncation mutation patients.

Acknowledgements

The authors disclosed receipt of the following financial support for the research of this article: Whole-exome sequencing in the index patient and Sanger validations in three cases was included in the project,

Copyright © 2020 Wolters Kluwer Health, Inc. Unauthorized reproduction of this article is prohibited.

titled 'Investigation of genetic etiology in patients with Epileptic Encephalopathies using Whole- Exome Sequencing'. D. Turkdogan executed this project with a grant provided by the Marmara University Scientific Research Committee (Project No. SAG-B-120516-0209).

Conflicts of interest

There are no conflicts of interest.

References

Deardorff MA, Kaur M, Yaeger D, Rampuria A, Korolev S, Pie J, *et al.* (2007). Mutations in cohesin complex members SMC3 and SMC1A cause a mild variant of Cornelia de Lange syndrome with predominant mental retardation. *Am J Hum Genet* **80**:485–494.

de Ligt J, Willemsen MH, van Bon BW, Kleefstra T, Yntema HG, Kroes T, *et al.* (2012). Diagnostic exome sequencing in persons with severe intellectual disability. *N ENGL J MED* **367**:1921–1929.

Fieremans N, Van Esch H, Holvoet M, Van Goethem G, Devriendt K, Rosello M, *et al.* (2016). Identification of intellectual disability genes in female patients with a skewed X-inactivation pattern. *Hum Mutat* **37**:804–811.

Gilissen C, Hehir-Kwa JY, Thung DT, van de Vorst M, van Bon BW, Willemsen MH, *et al.* (2014). Genome sequencing identifies major causes of severe intellectual disability. *Nature* **511**:344–347.

Goldstein JH, Tim-Aroon T, Shieh J, Merrill M, Deeb KK, Zhang S, *et al.* (2015). Novel SMC1A frameshift mutations in children with developmental delay and epilepsy. *Eur J Med Genet* **58**:562–568.

Gorman KM, Forman E, Conroy J, Allen NM, Shahwan A, Lynch SA, *et al.* (2017). Novel SMC1A variant and epilepsy of infancy with migrating focal seizures: expansion of the phenotype. *Epilepsia* **58**:1301–1302.

Hansen J, Mohr J, Bürki S, Lemke JR. (2013). A case of cohesinopathy with a novel de-novo SMC1A splice site mutation. *Clin Dysmorphol* **22**:143–145.

Huisman S, Mulder PA, Redeker E, Bader I, Bisgaard AM, Brooks A, *et al.* (2017). Phenotypes and genotypes in individuals with SMC1A variants. *AM J MED GENET A* **173**:2108–2125.

Jang MA, Lee CW, Kim JK, Ki CS. (2015). Novel pathogenic variant (c.3178G>A) in the SMC1A gene in a family with Cornelia de Lange syndrome identified by exome sequencing. *Ann Lab Med* **35**:639–642.

Jansen S, Kleefstra T, Willemsen MH, de Vries P, Pfundt R, Hehir-Kwa JY, *et al.* (2016). De novo loss-of-function mutations in X-linked SMC1A cause severe ID and therapy-resistant epilepsy in females: expanding the phenotypic spectrum. *Clin Genet* **90**:413–419.

Lebrun N, Lebon S, Jeannet PY, Jacquemont S, Billuart P, Bienvenu T. (2015). Early-onset encephalopathy with epilepsy associated with a novel splice site mutation in SMC1A. *Am J Med Genet A* **167A**:3076–3081.

Pavlidis E, Cantalupo G, Bianchi S, Piccolo B, Pisani F. (2014). Epileptic features in Cornelia de Lange syndrome: case report and literature review. *BRAIN DEV* **36**:837–843.

Symonds JD, Joss S, Metcalfe KA, Somarathi S, Cruden J, Devlin AM, *et al.*; DDD Study. (2017). Heterozygous truncation mutations of the SMC1A gene cause a severe early onset epilepsy with cluster seizures in females: detailed phenotyping of 10 new cases. *Epilepsia* **58**:565–575.

Tzschach A, Grasshoff U, Beck-Woedl S, Dufke C, Bauer C, Kehrer M, *et al.* (2015). Next-generation sequencing in X-linked intellectual disability. *Eur J Hum Genet* **23**:1513–1518.

Wenger TL, Chow P, Randle SC, Rosen A, Birgfeld C, Wrede J, *et al.* (2017). Novel findings of left ventricular non-compaction cardiomyopathy, microform cleft lip and poor vision in patient with SMC1A-associated Cornelia de Lange syndrome. *Am J Med Genet A* **173**:414–420.

Table 1 Summary of the phenotypic features of patients with mutation in SMC1A in this report and in the literature

	The present case	Case 1 (Symonds *et al.*, 2017)	Case 2 (Symonds *et al.*, 2017)	Case 3 (Symonds *et al.*, 2017)
Gender	F	F	F	F
Age	4 years 8 months	5 years	6 years	6 years
Mutation	Heterozygous c.2923C>T (p.Arg975*)	Heterozygous c.2923C>T (p.Arg975*)	Heterozygous c.1591C>T (p.Gln531*)	Heterozygous c.3145C>T (p.Arg1049*)
Inheritance	*De novo*	*De novo*	*De novo*	*De novo*
Facial dysmorphisms	Coarse facies; long and prominent eyelashes; widely spaced teeth; hirsutismus on forehead and neck; tapering fingers; proximally placed thumbs and hammer toes	Puffy eyes; right nasal deviation; small over- folded right pinna; short, slightly upturned nose; thin upper lip; shallow philtrum; clinodactyly of the middle toes of both feet; central incisor	Mild facial asymmetry with the right side of the face appearing fuller than the left; mild left ptosis; short, slightly up-turned nose; thin upper lip; shallow philtrum; small hands and feet	Bitemporal narrowing; upslanting palpebral fissures; thin, straight eyebrows; mildly posteriorly rotated ears; tapering of digits; short 5th fingers; short broad halluces; overlapping 2nd and 3rd toes
Prenatal growth retardation/ Short stature/Microcephaly	–/+/+	Unknown/+/+	Unknown/–/–	Unknown/+/+
Developmental delay	+	+	+	+
Speech	None	Lost speech aged 3 years following SE	None. Smiles and makes hand gestures	None
Motor development		Walking from 30 months	Can run with unsteady gait	Unable to sit without support
Stereotypic behaviour	–	Unknown	Unkmown	Unknown
Epilepsy (age at first seizure and seizure types)	8 months; focal motor seizures with frequent secondary generalizaiton	5 months; Focal, bilateral tonic	15 months; GTCS, hemiclonic, drop attacks, atypical absence	5–6 weeks; focal
Hypotonia	+++	+	+	+
EEG	Focal sharp waves at rolandic regions initially, progressed to multifocal sharp waves with backgrouns slowing	High voltage slow background	Independent left and right sided epileptiform abnormalities	Diffusely slow with sharp transients seen over both temporal regions
Treatment (drugs)	PH, OXB, folinic acid, LEV, CLB	CBZ, VPA, TPM, phenobarbitone, LEV, ketogenic diet	PHT, VPA, LEV, LMT, CLB, TPM, CBZ	CBZ, VPA, TPM, CLB, RUF, LEV, GBP ketogenic diet, VNS
CNS anomalies	Cerebellar atrophy	Normal	Normal	Cerebral volume loss

Copyright © 2020 Wolters Kluwer Health, Inc. Unauthorized reproduction of this article is prohibited.

(Continued)

	Case 4 (Symonds *et al*., 2017)	Case 5 (Symonds *et al*., 2017)	Case 6 (Symonds *et al*., 2017)	Case 7 (Symonds *et al*., 2017)
Gender	F	F	F	F
Age	3 years	8 years	10 years	4 years
Mutation	Heterozygous c.549G>A (p.Glu183Glu)	Heterozygous c.2197G>T (p.Glu733*)	Heterozygous c.3326_3330delATGGCinsC (p.Asp1109Alafs*102)	Heterozygous c.511C>T (p.Arg171*)
Inheritance	*De novo*	*De novo*	*De novo*	*De novo*
Facial dysmorphisms	Hirsutism of the forehead, back, arms and upper lip; bitemporal narrowing with low anterior hairline; long eyelashes; downturned corner of mouth with midline groove of the lower lip	Small widely spaced teeth; deep-set eyes; downward sloping palpebral fissures; short, slightly up-turned nose; shallow philtrum; low-set posteriorly rotated ears; syndactyly of the first and second toes	Deviation of both halluces at the metatarsophalangeal joint; left third finger camptodactyly; left fifth finger clinodactyly	None
Prenatal growth retardation/Short stature/Microcephaly	Unknown/–/–	Unknown/+/+	Unknown/–/–	Unknown/+/+
Developmental delay	+	+	+	+
Speech	None	None	None	None. Coos, laughs, cries appropriately
Motor development	Unable to sit without support	No independent mobility	Unable to sit without support	Can take a couple of steps with support
Stereotypic behaviour	Unknown	Unknown	Unknown	Unknown
Epilepsy (age at first seizure and seizure types)	4 months; FS, CSE, focal, myoclonic, spasms, tonic, atypical absence	5 months; Focal, generalized tonic	6 months; GTCS, myoclonic, atypical absence, tonic, spasms, NCSE, reflex sensory	4 weeks; GTCS, hemiclonic
Hypotonia	+	+	+	+
EEG	High amplitude background activity with epileptiform discharges over left and occasionally right hemisphere	Multifocal epileptic activity	Continuous high-voltage waves without epileptiform discharges	Frequent multispike and slow right centrotemporal region
Treatment (drugs)	GBP, AZA, CZP, LZP, VPA, LEV, pyridoxine	VPA, LMT, CBZ, TPM, LEV, PHT, CLB, phenobarbitone	Phenobarbitone, CBZ, CLB, VPA, LMT, TPM, LEV, pyridoxine, ketogenic diet	TPM, VPA, LEV, CBZ
CNS anomalies	Small hemorrhage along the posterior falx and tentorium	Normal	Small cavum septum vergae	Normal

	Case 8 (Symonds *et al*., 2017)	Case 9 (Symonds *et al*., 2017)	Case 10 (Symonds *et al*., 2017)	Case 11 (Jansen *et al*., 2016)
Gender	F	F	F	F
Age	14 years	Died at age 11 months	Died at age 9 years 2 months	46 years
Mutation	Heterozygous c.2477delA	Heterozygous c.2477delA	Heterozygous c.3115C>T (p.Gln1039*)	Heterozygous c.2364del (p.Asn788Lysfs* 10)
Inheritance	*De novo*	*De novo*	*De novo*	*De novo*
Facial dysmorphisms	Hirsutism of the forehead, back, arms and upper lip; bitemporal narrowing with low anterior hairline; long eyelashes; downturned corner of mouth with midline groove of the lower lip	Hypotelorism; small low-set posteriorly rotated ears; bilateral fifth finger clinodactyly; overlapping fourth and fifth fingers; left rockerbottom foot; hypoplastic nails of the fourth and fifth toes	Expressionless face, straight eyebrows; short, upturned nose; flattened midface; short philtrum; downturned corners of the mouth; small hands with tapering fingers	Straight eyebrows, deep set eyes, short philtrum and everted lower lip, disorganized teeth
Prenatal growth retardation/Short stature/Microcephaly	Unknown/–/–	Unknown/unknown/unknown	–/–/–	–/+/+
Developmental delay	+	+	+	+
Speech	None	None.	None.	None.
Motor development	Walking from 2.5 years. Unsteady on feet with frequent falls, aged 7	None	Unable to sit	Never crawled or walked
Stereotypic behaviour	Unknown	Unknown	Unknown	–
Epilepsy (age at first seizure and seizure types)	28 months; GTCS	<1 month; Unknown	2 months; GTCS, myoclonic, CSE	9 months; GTCS
Hypotonia	Unknown	Unknown	+	+

(continue)

Copyright © 2020 Wolters Kluwer Health, Inc. Unauthorized reproduction of this article is prohibited.

(Continued)

EEG	Right-sided spike and slow wave abnormalities	Unknown	Multifocal epileptogenic activity, more often over the right Hemisphere	'Centrencephalic' epilepsy
Treatment (drugs)	Phenobarbitone, LEV, TPM, LMT, CBZ, CLB, VNS	Unknown	TPM, VPA, LEV, RUF	PTY, phenobarbitone, CBZ, VPA, VGB, CZP
CNS anomalies	Normal	Semilobar holoprosencephaly	Thin abnormally shaped carpus callosum and minimal cerebral atrophy	Slightly enlarged ventricles, hypotrophy cerebellar vermis
	Case 12 (Jansen *et al.*, 2016)	Case 13 (Lebrun *et al.*, 2015)	Case 14 (Goldstein *et al.*, 2015)	Case 15 (Goldstein *et al.*, 2015)
Gender	F	F	F	F
Age	14 years	7 years	4 years	3 years
Mutation	Heterozygous 2.1 kb deletion of exon 16	Heterozygous c.1911 + 1G>T (p.T638Vfs*48)	Heterozygous c.2853_2856delTCAG (p.Ser951Argfs*1)	Heterozygous c.3549_3552dupGGCC (p.Ile1185Glyfs*23)
Inheritance	*De novo*	*De novo*	*De novo*	*De novo*
Facial dysmorphisms	Hirsutism of the forehead, back, arms and upper lip; bitemporal narrowing with low anterior hairline; long eyelashes; downturned corner of mouth with midline groove of the lower lip	Synophris, thin upper lip	Long eyelashes, short nose	None
Prenatal growth retardation/Short stature/Microcephaly	+/±	+/+/+	–/–/–	–/–/–
Developmental delay	+	+	+	+
Speech	None	None	None	None. Coos, interacts
Motor development	Walked at 2 year; suddenly stopped walking at 5 years	Delayed	Non ambulant	Walked at 12 months
Stereotypic behaviour	Unknown	Unknown	Unknown	Unknown
Epilepsy (age at first seizure and seizure types)	2 years; GTCS	<1 month; Focal, spasms	4 months; Tonic, focal bilateral clonic, CSE	17 months; Focal/atypical absence, GTCS
Hypotonia	Normal	+	+	Unknown
EEG	Unknown	Hypsarrhythmia	Multifocal epileptiform discharges	Generalized epileptiform activity or occipital abnormalities
Treatment (drugs)	LMT, TPM, CBZ, CLB, LEV, CZP, OXC, carnitine, pyridoxine, ketogenic diet, Estrogen	Unknown	Phenobarbitone, LEV, CLB, TPM, CZP, VPA, ketogenic diet	LEV, TPM, OXC, VPA, phenobarbitone
CNS anomalies	Mild periventricular white matter abnormalities	Thin corpus callosum	Mild symmetric T2 hyperintensities in the periatrial white matter on FLAIR sequencing with possible thickening of the insular cortex	Mild enlargement of extra-axial spaces; slight thinning of the corpus callosum. Temporal lobes prominent sulci and hippocampi round and somewhat smaller

(continue)

Copyright © 2020 Wolters Kluwer Health, Inc. Unauthorized reproduction of this article is prohibited.

(Continued)

	Case 16 (Gorman *et al.*, 2017)	Case 16 (Gorman *et al.*, 2017)	Case 15 (Huisman *et al.*, 2017)	Case 15 (Huisman *et al.*, 2017)
Gender	F	F	F	F
Age	died at age 9 months	died at age 3 years	Unknown	Unknown
Mutation	Heterozygous c.1114delG (p.Val372*)	g.10734G>A	Heterozygous c.31A>T (p. Asn11Tyr)	Heterozygous c.157dup (p.Thr53Asnfs*34)
Inheritance	*De novo*	*De novo*	Unknown	Unknown
Facial dysmorphisms	None	small hands andfeet, incomplete single palmar creases, big hallux bilater-ally extended	Synophrys, long eyelashes, Downturned corners mouth	Synophrys, long eyelashes, Downturned corners mouth
Prenatal growth retarda-tion/ Short stature/ Microcephaly	–/+/+	–/–/+	–/–/–	–/–/–
Developmental delay	+	+	+	+
Speech	None	None	Unknown	Unknown
Motor development	At 8 months, she had no head control	Unknown	Unknown	Unknown
Stereotypic behaviour	Unknown	–	+	+
Epilepsy (age at first sei-zure and seizure types)	7 weeks; focal	7 weeks; focal, tonic, infantile spasms, GTCS	2.5 months; generalized epilepsy	5 months; generalized epilepsy
Hypotonia	+	+	Unknown	Unknown
EEG	Multifocal spike and poly-spikebursts and persistent background slowing	A slow backgroundwith frequent epileptiform discharges, maximally left temporal	Unknown	Unknown
Treatment (drugs)	CBZ, VPA, TPM, pyri-doxal-5-phos-phate, phenytoin, and ketogenic diet	Multiplesantiepileptic drugs and ketogenic diet	Unknown	Unknown
CNS anomalies	Unknown	Unknown	Unknown	Unknown

(continue)

Copyright © 2020 Wolters Kluwer Health, Inc. Unauthorized reproduction of this article is prohibited.

(Continued)

	Case 20 (Huisman *et al.*, 2017)	Case 21 (Huisman *et al.*, 2017)
Gender	F	F
Age	Unknown	Unknown
Mutation	Heterozygous c.694G>T (p.Glu232*)	Heterozygous c.2364del (p.Asn788Lysfs*10)
Inheritance	Unknown	Unknown
Facial dysmorphisms	Long eyelashes, long philtrum, Downturned corners mouth	Downturned corners mouth
Prenatal growth retardation/Short stature/Microcephaly	–/–/+	–/–/+
Developmental delay	+	+
Speech	Unknown	Unknown
Motor development	Unknown	Unknown
Stereotypic behaviour	+	+
Epilepsy (age at first seizure and seizure types)	4 months; generalized epilepsy	9 months; generalized epilepsy
Hypotonia	Unknown	Unknown
EEG	Unknown	Unknown
Treatment (drugs)	Unknown	Unknown
CNS anomalies	Unknown	Unknown

CBZ, carbamazepine; CLB, clobazam; CZP, clonazepam; EEG, electroencephalography; GBP, gabapentin; LEV, levetiracetam; LMT, lamotrigine; OXC, oxcarbazepine; PHT, phenytoin; RUF, rufinamide; TPM, topiramate; VGB, vigabatrin; VNS, vagus nerve stimulation; VPA, sodium valproate.

Copyright © 2020 Wolters Kluwer Health, Inc. Unauthorized reproduction of this article is prohibited.