ACTA ORTHOPAEDICA et TRAUMATOLOGICA TURCICA
www.aott.org.tr

Research Article

Challenging aggressive surgical strategies in extraabdominal desmoid tumors: is tumor volume the missing key?

Evrim Şirin[1], Erdem Koç[1], Okan Yiğit[2], Yavuz Şahbat[3], Ömer Sofulu[1]

[1]Department of Orthopaedics Surgery and Traumatology, Marmara University School of Medicine, İstanbul, Türkiyes
[2]Department of Orthopaedics Surgery and Traumatology, Kartal Lütfi Kırdar Research and Training Hospital, İstanbul, Türkiye
[3]Department of Orthopaedics Surgery and Traumatology, Erzurum Mareşal Çakmak Research and Training Hospital, Erzurum, Türkiye

ARTICLE INFO

Article history:
Submitted May 19, 2024
Received in revised form
August 15, 2024
Last revision received form
October 22, 2025
Accepted October 22, 2025
Publication Date
February 23, 2026

Keywords:
Extraabdominal desmoid tumor Estimated tumor volume Recurrence Radiotherapy Wide resection

ORCID iDs of the authors:
E.Ş. 0000-0002-4752-2725;
E.K. 0000-0003-4893-3988;
O.Y. 0000-0001-9708-5351;
Y.Ş. 0000-0002-9963-5334;
Ö.S. 0000-0002-5210-224X.

ABSTRACT

Objective: Desmoid tumors are fibroblast-derived rare soft tissue neoplasms with unclear borders that invade the surrounding structures. Despite the non-metastasizing nature, these tumors often relapse due to strong local aggressive behavior. The aim of this study was to analyze the demographic and clinical characteristics of patients with extraabdominal desmoid tumor, who underwent surgery between 2012 and 2022 and to determine the risk factors affecting recurrence.

Methods: Thirty-five patients (14 males, 21 females; mean age 41.2 years (range: 11-80) underwent operation between the years 2012 and 2022 and followed up for a mean of 52 months. The diagnosis was confirmed with biopsy, and the plan for surgery and adjuvant radiotherapy was decided by the multidisciplinary tumor council. Demographic, radiologic, and management data of the patients were collected. Potential effects of surgical margin status, estimated tumor volume (ETV), and radiotherapy on recurrence were investigated. Estimated tumor volume was calculated from dimensions on pathologic specimens.

Results: While wide surgical resection was aimed for all patients, R0 margins were achieved only in 40%, whereas R1 and R2 margins were obtained in 22.9% and 37.1% of these patients respectively. The local recurrence rate was 40%. No significant correlation was observed between surgical margin positivity and the recurrence or progression of the tumor, when patients with R0 margin are statistically compared with the rest (P=.067). On the other hand, when R0 and R1 margins were compared with each other in terms of recurrence or progression, there was a statistically significant difference (P=.006). While the impact of radiotherapy on recurrence or progression could not be determined due to inadequate sample size, the recurrence rate increased significantly with increasing ETV (P=.01).

Conclusion: Extraabdominal desmoid tumors are ill-defined locally aggressive neoplasms with an unpredictable and challenging clinical course. When the disease-free and recurring patients were compared, the recurrence rate increased significantly as the ETV increased. Achieving negative margins is still the benchmark for surgery; however, the risks and benefits of an aggressive surgery should always be reevaluated when there is a high possibility of a complex reconstructive surgery that has the capability to affect the functional outcome adversely.

Introduction

Extraabdominal desmoid tumor (EDT) is a rare neoplasm, characterized by monoclonal fibroblast proliferation arising in various tissues like muscles, tendons, and ligaments.[1] Despite their non-metastasizing benign nature, their local aggressive character makes it one of the most challenging issues among surgeons dealing with orthopedic oncology.[2] It involves mainly the extremities, trunk, and shoulder girdle; however, it may also occur in many other locations.[3] Wide surgical resection has been recommended as the primary treatment over the years, but the lesion may recur even after surgery with free resection margins.[4] The reported recurrence rate after surgery alone is approximately 25%-45%.[5,6]

In EDT, histological examination reveals a monoclonal fibroblastic proliferation originating from the fascial and musculoaponeurotic planes.[4] Despite the low mitotic activity, the matrix of the tumor cells is ill defined and they have a strong infiltrative growth pattern along tissue planes and tend to invade the surrounding anatomical structures.[7-9]

Several risk factors have been associated with local recurrence in patients with EDT.[10] Positive surgical margins have traditionally been considered a potential risk factor, although recent studies present conflicting evidence regarding their prognostic value.[1] Besides, extremity-based desmoid tumors tend to have more aggressive behavior and higher recurrence rates compared to abdominal lesions. Genetic mutations, particularly CTNNB1 mutations such as S45F, have been shown to correlate with this increased recurrence risk.[11]

The main purpose of the current study is to present the clinical and demographic features of patients with EDT, who underwent surgery between the years 2012 and 2022, and to discuss the results of this aggressive surgery considering the high recurrence rate and also to determine the risk factors for local recurrence. Because of the rarity of the disease, most publications were performed as multicenter studies; so far, this is one of the largest single-center series in the literature. Besides, the estimated tumor volume (ETV), which was calculated from dimensions obtained directly from pathology specimens, has not been studied as a risk parameter for recurrence to date.

Corresponding author:
Evrim Şirin
evrimsirin@yahoo.com

Content of this journal is licensed under a Creative Commons Attribution-NonCommercial 4.0 International License.

Cite this article as: *Şirin E, Koç E, Yiğit O, Şahbat Y, Sofulu Ö. Challenging aggressive surgical strategies in extraabdominal desmoid tumors: is tumor volume the missing key? Acta Orthop Traumatol Turc., 2026, 60(1), 0103, doi: 10.5152/j.aott.2026.24103.*

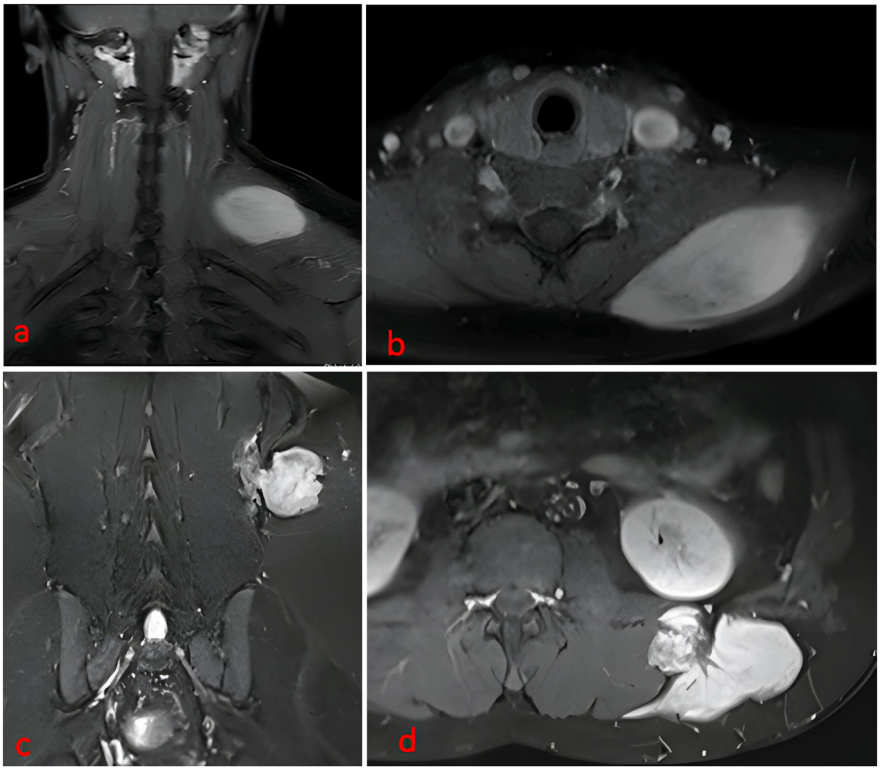

Figure 1. (a-d) Preoperative T2-weighted coronal (a) and axial (b) MRI sections of a 30-year-old female patient, demonstrating a desmoid tumor on the left upper shoulder area. T2-weighted coronal (c) and axial (d) MRI sections of a 17-year-old male patient with desmoid tumor, located on the lumbar area.

Materials and methods

The study was approved by Clinical Research Ethics Committee of Marmara University School of Medicine on October 6, 2023 (90.2023.1215). Informed consent was obtained from the patients before surgery and no funding was received for the study. Data on patients' tumors and treatment methods, imaging modalities, and outcomes were obtained from a retrospective review of medical records using the hospital's software program (Origo). Patients who were diagnosed with EDT and scheduled for wide resection surgery between 2012 and 2022 were retrospectively analyzed. Magnetic resonance imaging (MRI) was performed for each patient. Characteristically, lesions are usually iso-intense in T1-weighted images with respect to muscle signal, whereas on T2-weighted images, lesions are hyperintense and intermediate between muscles and fat, and on both T1 and T2 images, zones of low signal intensity reflect hypocalularity and collagen formation.[12] According to this typical image, EDT was considered in the differential diagnosis (Figure 1a-d).

All patients underwent a biopsy procedure, and the diagnosis of EDT was confirmed before the definitive management protocol. Biopsy was performed with a Tru-Cut needle under local anesthesia under appropriate sterile conditions in patients who had a superficial tumor location. Patients with deeply localized tumors, bone involvement, and tumors in neurovascular neighborhoods were biopsied under general anesthesia in the operating room. Either a Tru-Cut biopsy with a Jamshidi needle or a mini-open procedure was preferred for deeply localized masses. Biopsy incisions were determined in accordance with the final surgical plan.

Patients with abdominal, neck, or head localization; those with less than 12 months of follow-up; those referred from another center after undergoing surgery; and patients who were not eligible for surgery and opted for conservative management were excluded. All the evaluations were discussed in the multidisciplinary orthopedic oncology council, and a treatment protocol was determined for each patient. An adjuvant radiotherapy protocol was decided for selected patients. Generally, the surgical margin positivity, tumor location, the size of the excised tumor, and the general condition of the patient played a role in this decision. Adjuvant radiotherapy was also administered in certain patients with R0 resection margins and high tumor volume according to the decision of the multidisciplinary council. Once decided, it was started after soft tissue healing, on average, in the third week postoperatively. The patients were thoroughly informed about the treatment scheme decided specifically for them in the multidisciplinary council, and the treatment options and possible complications were explained.

To evaluate the surgical margin, the R classification system was used. According to the R classification,[13] residual tumors are referred to as R0, R1, and R2. Namely, R0: no residual tumor cells with a margin ≥1 mm, R1: microscopic residual tumor with a margin ≤1 mm, and R2: macroscopic residual tumor.

HIGHLIGHTS

- Desmoid tumors are locally aggressive tumors of fibroblast origin with an unpredictable recurrence rate.
- This high rate of recurrence is independent of the demographic characteristics of the patients and also the surgical margins obtained in the pathology records.
- The present study demonstrates that the recurrence rate increases significantly as the pathological volume of the tumor increases.
- In patients where a morbid surgery would result in great functional impairment or amputation, a wait-and-see policy should always be considered.

After excision, large gaps in the soft tissue and bone were reconstructed with appropriate methods such as muscle flaps or endoprostheses. The excised tumor specimens were then placed in 10% formaldehyde solution, in accordance with the standard procedure. Thereafter, the specimens were transferred to the pathology department, where the size of the specimen and the macroscopic tumor tissue in the specimen were documented separately. The ETV was then determined using the measurements documented by the pathology department. With the data obtained from the pathology reports, the ETV was calculated directly from pathology specimens by using a hemi-ellipsoid forming formula, which follows as volume=π/6×length×width×height.[14]

Patients were called for follow-up visits at the postoperative first month, third month, and then every 3 months after that for the first 3 years. Follow-up MRI was performed once a year after the first control imaging at the sixth month postoperatively. Once a recurrence was suspected, a control MRI was ordered as soon as possible. The follow-up and treatment process of patients with recurrence was again discussed, and decisions were made in the multidisciplinary council.

Statistical analysis

The data collected in the research were statistically analyzed using SPSS, version 22.0 (IBM SPSS Corp.; Armonk, NY, USA). Categorical variables were compared using either the chi-square or Fisher's exact test, while the Kruskal–Wallis test was utilized to analyze the ETV of the patients. A value of $P < .05$ was considered statistically significant.

Results

Patient demographics are presented in Table 1. Out of these 60 patients, who had the diagnosis of EDT, 35 patients were included in the study. Twenty patients were excluded due to abdominal, neck, or head localization; 3 patients were excluded because they had previously undergone surgery at another center and were referred afterwards; and 2 patients were excluded because they were deemed unsuitable for surgery and were managed conservatively (Figure 2).

According to gender, 21 patients were female (60%) and 14 were male (40%). The mean age at the time of diagnosis was 41.2 years (range: 11-80). Considering the tumor location, 16 patients (45.7%) had upper extremity, 10 patients (28.5%) had lower extremity, and 9 patients (25.7%) had truncal involvement. The mean follow-up period of the patients included in the study was 52 months (range: 13-141). The median duration for follow-up was 55 months (SD ± 36 months). Regarding the involvement of soft tissue and bone, 24 patients had only soft tissue involvement, whereas in 11 patients, the tumor was invading both soft tissue and bone simultaneously. For these patients with bone involvement, endoprosthetic reconstruction was performed in 3 patients, and biological reconstruction with vascularized fibula graft was preferred for 1 patient (Figure 3a-e). None of these reconstruction methods was required for 7 patients. Final pathology reports indicated that R0 surgical margins could only be achieved in 14 patients, whereas R1 and R2 margins were obtained in 8 and 13 of these patients, respectively. Although a wide resection was aimed for every patient, performing an R2 resection was partially due to the tumor's infiltrative nature but mainly due to a deliberate intraoperative decision to preserve vital anatomical structures. Looking at the recurrence or progression, there was a total of 14 patients with recurrence or progression (R0=3, R1=7, R2=4), whereas no recurrence or progression was detected in 21 patients (R0=11, R1=1, R2=9). Despite the fact that wide surgical margins could not be achieved in 60% of patients, no significant correlation was observed between this surgical margin positivity and the recurrence or progression of the tumor, when patients with R0 margins are statistically compared with the rest ($P=.067$, Pearson chi-square test). On the other hand, when R0 and R1 margins were compared with each other in terms of recurrence or progression, there was a statistically significant difference ($P=.006$, Fisher's exact test).

Table 1. Characteristics of the study population

Charasteristic	Frequency	%
Gender		
Male	14	40
Female	21	60
Mean age (years)	41.2	
Location of tumor		
Upper extremity	16	45.7
Lower extremity	10	28.5
Trunk	9	25.7
Tumor involvement		
Soft tissue only	24	68.5
Soft tissue and bone	11	31.5

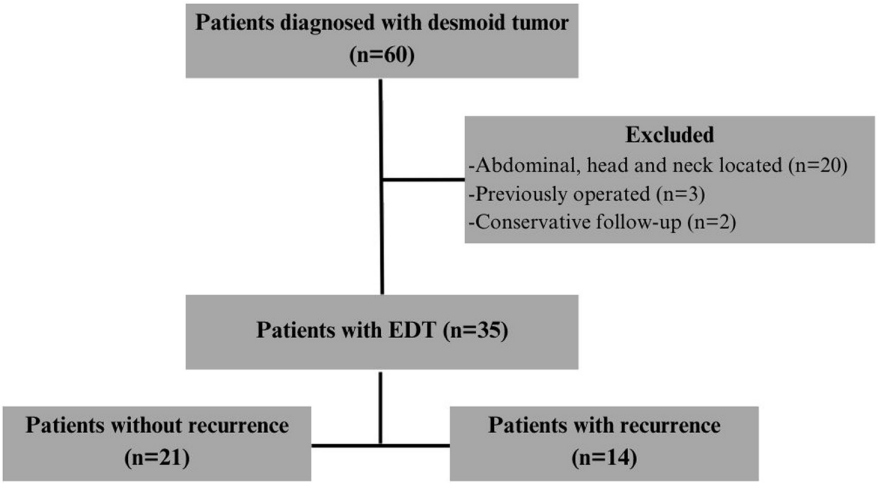

Figure 2. Flowchart description of the study.



Figure 3. (a-e) Radiography and MRI of a 13-year-old male patient with a desmoid tumor on the right distal forearm (a-b). After the wide resection (c), the distal radius was reconstructed with a free vascularized fibula graft. The follow-up radiographs at the postoperative fifth and sixth years are demonstrated in d and e.

Ten patients with recurrence were left to a "wait and see" policy; however, in the remaining 4 patients, due to enlarging tumor size and increasing patients' complaints over time, a re-resection surgery was planned. In patients with recurrence, the average time interval was determined to be 14 months (range: 5-24 months) (Figure 4). Although imatinib was not included in the routine treatment protocol of EDT patients, 1 patient with a very early local recurrence received oral imatinib upon the council's decision.

Twenty-one patients without recurrence or progression were classified as group 1, whereas the remaining 14 patients with recurrence or tumor progression were classified as group 2 (Table 2). When the epidemiologic characteristics of the groups were analyzed, no significant

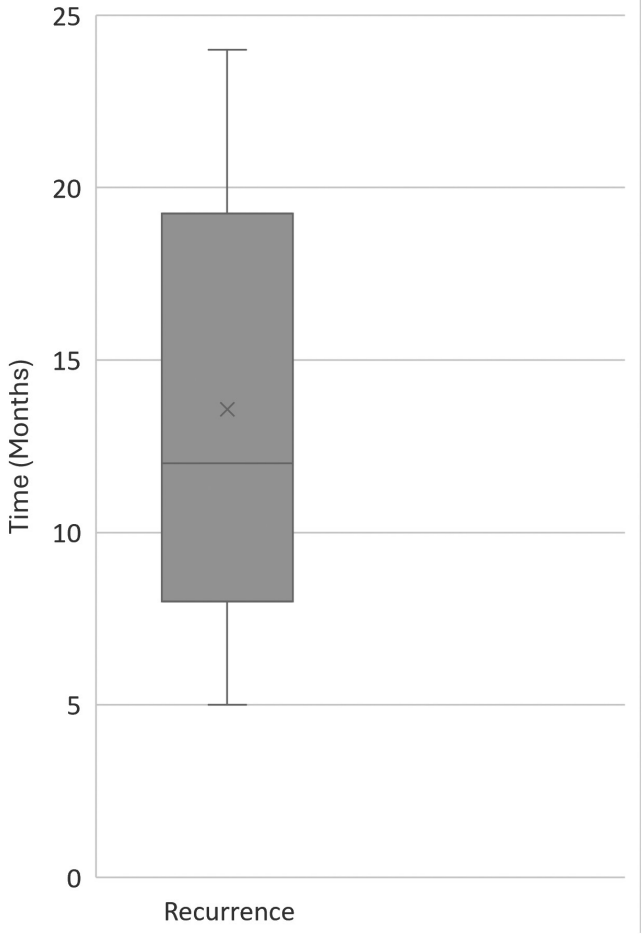

Figure 4. The time of recurrence after surgery (in months) is demonstrated. The shortest duration until recurrence was 5 months, whereas the longest duration was 24 months, with a mean of 14 months.

difference was detected between the groups in terms of age (P=.737, Mann–Whitney U-test) and gender (P=.637, Pearson chi-square test). There was also no statistically significant difference in the location and site of the tumor either, whether in the upper, lower extremity, or the trunk (P=.582, Pearson chi-square test). According to the pathology reports, the mean ETV was 209.7 cm^3 (range: 10.47-1105 cm^3), which was calculated using the hemi-ellipsoid formula. In patients with free surgical margins (R0), the mean ETV was 144.19 (SD ± 283.55) cm^3, whereas in patients with positive margins (R1+R2), the mean ETV was 253.39 (SD ± 157.69) cm^3. Considering these surgical margins, the ETV was significantly lower in R0 patients compared to the R1/R2 group (P=.016, Mann–Whitney U-test).

Out of these 14 patients with recurrence or tumor progression, it was observed that 3 patients had R0 margins (ETV=176.30 cm^3 SD ± 135.46), whereas 11 patients had R1/R2 surgical margins (ETV=341.84 cm^3 SD ± 158.03) according to pathology files. On the other hand, 21 patients had no recurrence or progression, where 11 patients had R0 margins (ETV=135.43 cm^3 SD ± 322.58) and 10 patients had R1/R2 (ETV=178.18 cm^3 SD ± 132.97) surgical margins. When the ETV values were analyzed between these subgroups, it was observed that the recurrence rate increased significantly with increasing ETV (P=.01, Kruskal–Wallis test).

A detailed analysis was conducted on the data of 24 patients who received radiotherapy regarding surgical margin status R0 (n=7), R1 (n=8), and R2 (n=9) (Table 3). When each group was analyzed separately, the impact of radiotherapy did fail to reach true statistical significance regarding recurrence or progression (P=.258, P=.998, P=.999 for R0, R1, and R2 respectively (Fisher's exact test), probably due to a lack of adequate sample size, because when the sample size was hypothetically increased while maintaining the same proportions, the P-value for the R0 group decreased to 0.062 and 0.016 (after making double and triple) respectively, indicating statistical significance at higher sample sizes. These findings suggest that studies conducted with a larger cohort would demonstrate the meaningful effect of radiotherapy for particularly R0 patients; however, it has still to be determined whether it is due to the toxic effect of radiation on tumor cells or solely due to clear surgical margins with a safe reactive zone.

Discussion

There are no generally determined rules for the management of EDT available, based on studies in large cohorts of patients.[15] Although spontaneous regression has been observed in certain patients, surgery has been generally accepted as the primary treatment modality for years.[16,17] The characteristic variable, and often unpredictable clinical course, make it one of the most challenging issues among surgeons dealing with orthopedic oncology. This specific aggressive growth pattern makes the surgery more difficult; hence, the need to achieve negative margins in EDT could often be larger than for a same-sized soft tissue sarcoma, leading to potential impairment of function and cosmetic concerns in patients affected by a benign disease.[6,18]

In a comparative study performed by Leithner et al,[19] the rate of total recurrence was significantly high (72%) after R1 and R2 resections, in contrast to the rate after wide or radical resection (27%). Naturally, the benchmark of surgical treatment is to reach negative surgical margins and finally achieve the best possible functional and cosmetic results.[20] In the current study, however, only 40% of patients had R0 margins. The remarkable finding of the current study was that the correlation between surgical margins and relapse was found to be significant only when R0 and R1 surgical results were compared, a fact which is very hard to explain and might be attributed to the inadequate sample size. Besides, the unexpectedly low progression rate of R2 patients was also remarkable. This may be due to the small sample size, short follow-up duration, or the inherently unpredictable biological behavior of the tumor. Another explanation could be that EDT exhibits this unpredictable course of progression not just from the beginning but also after any surgical intervention. However, Pakos et al[12] emphasized that most of the studies performed in the field do not have the necessary power to analyze the impact of R0 surgical margins on disease-free survival rates.

In another study performed by Peng et al,[21] it was observed that patients over a certain age had a longer recurrence-free survival time with regard to their age; however, the impact of age on outcome following surgical resection of EDT is still not very clearly defined.[5,22,23] While several studies have reported that younger age was associated with a quicker time to recurrence, many other studies failed to find such an association. In this study, no significant relation was observed between the recurrence and non-recurrence groups in terms of age and gender.

Table 2. Preoperative and postoperative data, divided into 2 groups, disease-free patients and relapsed patients. Categorical variables were compared using either the chi-square or Fisher's exact test, while the Kruskal–Wallis test was utilized to analyze the extraabdominal desmoid tumor of the patients. A value of $P < .05$ was considered statistically significant

		Study groups		
		Recurrence/Progression (–) patients (n = 21)	**Recurrence/Progression (+) patients (n = 14)**	***P***
Mean age (years)		42	39.8	.737
Tumor size (cm^3)		155.78	290.59	.01
Location	Upper ext	11	7	.582
	Lower ext	6	5	
	Axial	4	2	
Residual tumor	R0	11	3	.067
	R1	1	7	
	R2	9	4	
Adjuv radiotherapy		13	11	

Adj, adjuvant; Ext, extremity.

On the other hand, systemic therapies such as oral tyrosine kinase inhibitors (TKI) like sorafenib, imatinib, pazopanib, etc., and chemotherapy have also been used in patients exhibiting rapid progression of the disease and also in inoperable conditions. Although the current literature shows a 1-year progression-free survival rate of 66%-86% in patients using TKIs, there is no consensus on certain parameters such as effective dose selection and timing of this treatment.[24-26] In this series, only a single patient with very early local recurrence exhibiting a rapid progression in tumor size received oral TKI therapy, where this rapid progression could only be held to some extent.

An important fact in the current study exhibited that the average time for recurrence was 14 months (range: 5-24), where the first MRI in the follow-up schedule was ordered at the sixth month postoperatively. In order to detect these recurrences earlier, the control imaging could be performed more frequently in the first year.

Another controversial fact is the use of radiotherapy in EDT. Although the role of radiotherapy is very well recognized in the management of mesenchymal sarcomas, it is not as clear in EDT.[27] Particularly, margin status is a debatable prognostic factor which is interfering strongly with radiation data. Shin et al[28] and Houdek et al[29] reported that adjuvant radiotherapy delayed the time of recurrence of the tumor; however, it had no effect on the ultimate relapse rate. Although most meta-analytic studies emphasize that adjuvant radiotherapy should be considered, especially in those patients with R1 or R2 resection margins, its exact role is still controversial, since the indication for its use in EDT is debated due to its side effects and toxicity, particularly in the younger population.[30,31]

In the current study, the decision for adjuvant radiotherapy was made by the multidisciplinary tumor council on a case-by-case basis according to the final surgical margin of the excised specimen, tumor size, age, and general medical status of the patient. The importance of this council is very critical; hence, some patients with even clear surgical margins received adjuvant radiotherapy. The recurrence or progression of 10 patients was left to observation only, considering the impact of morbidity from surgery or the unwillingness of these patients to undergo re-operation.

Recent studies emphasize the impact of this "wait and see" policy. Rastrelli et al[32] demonstrated that about half the patients did not experience any tumor progression, while surgery was reserved as a first-line approach for only selected patients.

The first notable finding of the current study was that adjuvant radiotherapy did not play a significant role in local recurrence, except for patients with R0 surgical margins. This finding is supported by many studies performed in the field,[33] where no significant differences were reported for patients undergoing surgery alone, compared to the combination of surgery and adjuvant radiotherapy in terms of local control.[34] On the other hand, radiotherapy can also be delivered at a moderate dose (i.e., 50 Gy) as a definitive treatment modality in certain patients who are considered not eligible for surgery or in patients with tumors close to vital anatomical structures.[35]

Overall, the most remarkable finding of the present study was the relation of ETV with the rate of recurrence. This correlation between the recurrence rate and tumor volume can be attributed to larger tumor load; however, there might be several other parameters. Exploring factors such as tumor biology, growth patterns, and challenges of achieving complete resection in larger tumors would strengthen the future analysis.

Naturally, there are certain limiting aspects of the present study. It has a retrospective structure, and the location, size, and most importantly, variable surgical margins in the final pathology reports make it somewhat heterogeneous. Since patients managed without surgery with primarily a "wait and see" protocol were excluded from the study, a control group was lacking. Another limiting aspect is the short follow-up period of patients with R1 and R2 surgical margins, which limits the time interval for evaluation of disease progression.

On the other hand, the decision for adjuvant radiotherapy was made on a case-by-case basis, and there was no strict rationale; while most

Table 3. The effect of radiotherapy on recurrence/progression for R0 and R1/2 groups

	RT (+) (n = 24)	**RT (–) (n = 11)**
R0	7	7
R1+R2	17 (8+9)	4
	RT (+) no recurrence/progression (n = 13)	**RT (+) recurrence/progression (n = 11)**
R0 (total 7)	6	1
R1+R2 (total 17)	7	10

All data were retrieved from patient records.

patients with R1 and R2 margins received adjuvant radiotherapy, some did not due to the general condition of these patients, whereas some R0 patients were still scheduled on the radiotherapy protocol.

Finally, tumor volume measurements were directly obtained from tissue specimens, where the shrinkage effect of formalin was overlooked to some extent,[36] although these measurements were done in a timely manner, unlike similar studies where these sizes were usually calculated from sections on MRI.

Besides, the number of cases is not adequate to warrant a uniform approach; however, it is one of the largest single-center series. That is why large randomized trials comparing the efficacy of various treatment methods and their prognostic significance should be carefully studied for the future.

In conclusion, EDTs are rarely encountered neoplasms with local aggressive behavior; however, they do not have the potential for distant metastasis. The spicular spread and infiltrative type of growth, and particularly large tumor volume, often result in local recurrences regardless of the choice of treatment. Today, surgical resection with wide and clear borders still seems to be the primary management option; however, the risks and benefits of an aggressive surgery should always be reevaluated when there is a high possibility of a complex reconstructive surgery that has the capability to affect the functional outcome adversely.

Data Availability Statement: The data that support the findings of this study are available on request from the corresponding author.

Ethics Committee Approval: Ethical committee approval was received from the Clinical Research Ethics Committee of Marmara University School of Medicine (Approval No.: 90.2023.1215; Date: 06.10.2023).

Informed Consent: Written informed consent was obtained from the patients who agreed to take part in the study.

Peer-review: Externally peer-reviewed.

Author Contributions: Concept – E.K.; Design – E.Ş., E.K.; Supervision – E.Ş.; Resources – E.Ş.; Materials – E.Ş., Ö.S., E.K.; Data Collection and/or Processing – E.K., Y.Ş.; Analysis and/or Interpretation – E.K., Y.Ş.; Literature Search – O.Y.; Writing – E.Ş., E.K.; Critical Review – E.Ş., Ö.S.

Declaration of Interests: The authors have no conflict of interest to declare.

Funding: The authors declared that this studyhas received no financial support.

References

1. Nishida Y, Hamada S, Kawai A, et al. Risk factors of local recurrence after surgery in extraabdominal desmoid-type fibromatosis: a multicenter study in japan. *Cancer Sci*. 2020;111(8):2935-2942. [CrossRef]
2. Subhawong TK, Feister K, Sweet K, et al. Mri volumetrics and image texture analysis in assessing systemic treatment response in extra-abdominal desmoid fibromatosis. *Radiol Imaging Cancer*. 2021;3(4):e210016. [CrossRef]
3. Ozger H, Eralp L, Toker B, Ağaoğlu F, Dizdar Y. Ekstra-abdominal desmoid tümörlerde nüks ve hastaliksiz sağkalimi etkileyen prognostik faktörlerin değerlendirilmesi [Evaluation of prognostic factors affecting recurrences and disease-free survival in extra-abdominal desmoid tumors]. *Acta Orthop Traumatol Turc*. 2007;41(4):291-294.
4. Plukker JT, Van Oort I, Vermey A, et al. Aggressive fibromatosis (non-familial desmoid tumour): therapeutic problems and the role of adjuvant radiotherapy. *Br J Surg*. 1995;82(4):510-514. [CrossRef]
5. Ballo MT, Zagars GK, Pollack A, Pisters PW, Pollack RA. Desmoid tumor: prognostic factors and outcome after surgery, radiation therapy, or combined surgery and radiation therapy. *J Clin Oncol*. 1999;17(1):158-167. [CrossRef]
6. Gronchi A, Casali PG, Mariani L, et al. Quality of surgery and outcome in extra-abdominal aggressive fibromatosis: a series of patients surgically treated at a single institution. *J Clin Oncol*. 2003;21(7):1390-1397. [CrossRef]
7. Sobczuk P, Agnieszczak IM, Grycuk W, et al. What is the best front-line approach in patients with desmoid fibromatosis? – A retrospective analysis from a reference center. *Eur J Surg Oncol*. 2021;47(10):2602-2608. [CrossRef]
8. Penel N, Chibon F, Salas S. Adult desmoid tumors: biology, management and ongoing trials. *Curr Opin Oncol*. 2017;29(4):268-274. [CrossRef]
9. Jo VY, Fletcher CD. Who classification of soft tissue tumours: an update based on the 2013 (4th) edition. *Pathology*. 2014;46(2):95-104. [CrossRef]
10. Denwood H, Gonzalez MR, Sodhi A, et al. Risk factors for local recurrence of upper extremity desmoid tumors. *J Surg Oncol*. 2024;129(4):813-819. [CrossRef]
11. Spolverato G, Capelli G, Kasper B, Gounder M. Management of desmoid tumors. *Surg Oncol Clin N Am*. 2022;31(3):447-458. [CrossRef]
12. Pakos EE, Tsekeris PG, Goussia AC. Desmoid tumours of the extremities and trunk: a review of the literature. *Int Orthop*. 2005;29(4):210-213. [CrossRef]
13. Wittekind C, Compton C, Quirke P, et al. A uniform residual tumor (r) classification: integration of the r classification and the circumferential margin status. *Cancer*. 2009;115(15):3483-3488. [CrossRef]
14. Baysal Ö, Sağlam F, Akgülle AH, Baykan SE, Erol B. Prediction of soft tissue coverage following distal femur bone sarcoma resection: a preliminary report. *J Orthop Res*. 2022;40(2):468-474. [CrossRef]
15. Buitendijk S, van de Ven CP, Dumans TG, et al. Pediatric aggressive fibromatosis: a retrospective analysis of 13 patients and review of the literature. *Cancer*. 2005;104(5):1090-1099. [CrossRef]
16. Faulkner LB, Hajdu SI, Kher U, et al. Pediatric desmoid tumor: retrospective analysis of 63 cases. *J Clin Oncol*. 1995;13(11):2813-2818. [CrossRef]
17. Godzinski J, Sulka W, Rapala M. Aggressive fibromatosis: a challenge for paediatric oncological surgery. *Pediatr Blood Cancer*. 2003;41:278.
18. Kasper B, Baumgarten C, Bonvalot S, et al. Management of sporadic desmoid-type fibromatosis: a European consensus approach based on patients' and professionals' expertise–a sarcoma patients euronet and European Organisation for Research and Treatment of Cancer/soft tissue and bone sarcoma group initiative. *Eur J Cancer*. 2015;51(2):127-136. [CrossRef]
19. Leithner A, Gapp M, Leithner K, et al. Margins in extra-abdominal desmoid tumors: a comparative analysis. *J Surg Oncol*. 2004;86(3):152-156. [CrossRef]
20. Coşkun HS, Erdoğan F, Çinka H, Dabak N. Extra-abdominal desmoid fibromatosis: an evaluation of clinical factors affecting local recurrence rates. *Acta Orthop Traumatol Turc*. 2021;55(6):547-551. [CrossRef]
21. Peng PD, Hyder O, Mavros MN, et al. Management and recurrence patterns of desmoids tumors: a multi-institutional analysis of 211 patients. *Ann Surg Oncol*. 2012;19(13):4036-4042. [CrossRef]
22. Huang K, Fu H, Shi YQ, Zhou Y, Du CY. Prognostic factors for extra-abdominal and abdominal wall desmoids: a 20-year experience at a single institution. *J Surg Oncol*. 2009;100(7):563-569. [CrossRef]
23. Salas S, Dufresne A, Bui B, et al. Prognostic factors influencing progression-free survival determined from a series of sporadic desmoid tumors: a wait-and-see policy according to tumor presentation. *J Clin Oncol*. 2011;29(26):3553-3558. [CrossRef]
24. Kasper B, Gruenwald V, Reichardt P, et al. Imatinib induces sustained progression arrest in recist progressive desmoid tumours: final results of a phase ii study of the German interdisciplinary sarcoma group (gisg). *Eur J Cancer*. 2017;76:60-67. [CrossRef]
25. Garg V, Gangadharaiah BB, Rastogi S, et al. Efficacy and tolerability of sorafenib in desmoid-type fibromatosis: a need to review dose. *Eur J Cancer*. 2023;186:142-150. [CrossRef]
26. Alman B, Attia S, Baumgarten C. The management of desmoid tumours: a joint global consensus-based guideline approach for adult and paediatric patients. *Eur J Cancer*. 2020;127:96-107. [CrossRef]
27. Wirth L, Klein A, Baur-Melnyk A, et al. Desmoid tumours of the extremity and trunk. A retrospective study of 44 patients. *BMC Musculoskelet Disord*. 2018;19(1):2. [CrossRef]
28. Shin SH, Ko KR, Cho SK, Choi YL, Seo SW. Surgical outcome of desmoid tumors: adjuvant radiotherapy delayed the recurrence, but did not affect long-term outcomes. *J Surg Oncol*. 2013;108(1):28-33. [CrossRef]
29. Houdek MT, Rose PS, Kakar S. Desmoid tumors of the upper extremity. *J Hand Surg Am*. 2014;39(9):1761-1765. [CrossRef]
30. Garcia-Ortega DY, Martín-Tellez KS, Cuellar-Hubbe M, et al. Desmoid-type fibromatosis. *Cancers*. 2020;12(7):1851. [CrossRef]
31. Janssen ML, Van Broekhoven DL, Cates JM, et al. Meta-analysis of the influence of surgical margin and adjuvant radiotherapy on local recurrence after resection of sporadic desmoid-type fibromatosis. *Br J Surg*. 2017;104(4):347-357. [CrossRef]
32. Rastrelli M, Chiusole B, Cavallin F, et al. Desmoid tumors in the active surveillance era: evaluation of treatment options and pain relief in a single-center retrospective analysis. *J Pers Med*. 2023;13(12):1653. [CrossRef]
33. Seidensaal K, Harrabi SB, Weykamp F, et al. Radiotherapy in the treatment of aggressive fibromatosis: experience from a single institution. *Radiat Oncol*. 2020;15(1):143. [CrossRef]
34. Guadagnolo BA, Zagars GK, Ballo MT. Long-term outcomes for desmoid tumors treated with radiation therapy. *Int J Radiat Oncol Biol Phys*. 2008;71(2):441-447. [CrossRef]
35. Borghi A, Gronchi A. Desmoid tumours (extra-abdominal), a surgeon's nightmare. *Bone Joint J*. 2023;105-B(7):729-734. [CrossRef]. Erratum in: *Bone Joint J*. 2023;105-B(9):1030. (https://doi.org/10.1302/0301-620X.105B9.BJJ-2023-00034)
36. Docquier PL, Paul L, Cartiaux O, et al. Formalin fixation could interfere with the clinical assessment of the tumor-free margin in tumor surgery: magnetic resonance imaging-based study. *Oncology*. 2010;78(2):115-124. (doi:[CrossRef]