

Ultrastructural Pathology

ISSN: (Print) (Online) Journal homepage: https://www.tandfonline.com/loi/iusp20

Ultrastructural investigation of synaptic alterations in the rat hippocampus after irradiation and hyperthermia

Gozde Erkanli Senturk , Ozlem Tugce Cilingir-Kaya , Serap Sirvanci , Cihan Isler , Rahsan Kemerdere , Mustafa Onur Ulu , Cenk Umay , Filiz Onat , Cigdem Ozkara , Mustafa Uzan & Feriha Ercan

To cite this article: Gozde Erkanli Senturk , Ozlem Tugce Cilingir-Kaya , Serap Sirvanci , Cihan Isler , Rahsan Kemerdere , Mustafa Onur Ulu , Cenk Umay , Filiz Onat , Cigdem Ozkara , Mustafa Uzan & Feriha Ercan (2020): Ultrastructural investigation of synaptic alterations in the rat hippocampus after irradiation and hyperthermia, Ultrastructural Pathology, DOI: 10.1080/01913123.2020.1839151

To link to this article: https://doi.org/10.1080/01913123.2020.1839151

Published online: 30 Oct 2020.

Submit your article to this journal

Article views: 6

View related articles

View Crossmark data

Full Terms & Conditions of access and use can be found at
https://www.tandfonline.com/action/journalInformation?journalCode=iusp20

ULTRASTRUCTURAL PATHOLOGY
https://doi.org/10.1080/01913123.2020.1839151

Taylor & Francis
Taylor & Francis Group

Check for updates

Ultrastructural investigation of synaptic alterations in the rat hippocampus after irradiation and hyperthermia

Gozde Erkanli Senturk[a], Ozlem Tugce Cilingir-Kaya[b], Serap Sirvanci[b], Cihan Isler[c], Rahsan Kemerdere[c], Mustafa Onur Ulu[c], Cenk Umay[d], Filiz Onat[e], Cigdem Ozkara[f], Mustafa Uzan[c], and Feriha Ercan[b]

[a]Cerrahpasa Faculty of Medicine, Department of Histology and Embryology, Istanbul University-Cerrahpasa, Istanbul, Turkey; [b]Department of Histology and Embryology, School of Medicine, Marmara University, Istanbul, Turkey; [c]Cerrahpasa Faculty of Medicine, Department of Neurosurgery, Istanbul University-Cerrahpasa, Istanbul, Turkey; [d]Department of Radiation Oncology, School of Medicine, Dokuz Eylul University, Izmir, Turkey; [e]Department of Pharmacology and Clinical Pharmacology, School of Medicine, Marmara University, Istanbul, Turkey; [f]Cerrahpasa Medical Faculty, Department of Neurology, Istanbul University-Cerrahpasa, Istanbul, Turkey

ABSTRACT

This study aimed to investigate ultrastructural synaptic alterations in rat hippocampus after in utero exposure to irradiation (IR) and postnatal exposure to hyperthermia (HT). There were four groups in each of the time points (3rd and 6th months). IR group: Pregnant rats were exposed to radiation on the 17th gestational day. HT group: Hyperthermia was applied to the rat pups on the 10th day after their birth. IR+HT group: Both IR and HT were applied at the same time periods. Control group: No IR or HT was applied. Rat pups were sacrificed after 3 and 6 months. Thin sections from the dentate gyrus (DG) and the CA3 of hippocampus were evaluated for synapse numbers by electron microscopy. Synapses were counted, and statistical analysis was performed. Abnormalities in myelin sheath, mossy terminals and neuropil were observed in the CA3 and DG of all groups. The synapses in the CA3 region were significantly increased in the IR-3rd month, IR-6th month, and IR+HT-3rd month groups vs control group. Synapses were significantly increased in the DG of HT-3rd month group. A trend for an increase in synapse numbers was seen in the CA3 and DG. Increased number of synapses in the rat hippocampus may be due to mossy fiber sprouting, possibly caused by in utero irradiation and/or postnatal hyperthermia.

ARTICLE HISTORY
Received 16 July 2020
Revised 14 September 2020
Accepted 15 October 2020

KEYWORDS
Radiation; hyperthermia; hippocampus; synapse; ultrastructure

Introduction

Febrile seizure (FS) is a convulsive disorder that can be seen most frequently in early childhood period. Over 5% of population has suffered a minimum of one episode of FS.[1] Some patients with mesial temporal lobe epilepsy (MTLE) have a history of extended FS in their childhood period. A few studies showed the cellular alterations in MTLE in adults that have had FS in their childhood period.[2] However, the molecular and cellular processes of MTLE-based FS and FS have not been fully understood.[3]

An animal study showed that FS induced by hyperthermia caused an increment in the hippocampal expression of pro-apoptotic Bax and a decrement in the anti-apoptotic Bcl-2 in young rats.[4] Moreover, some other data showed that neuron loss was not the reason for prolonged FS in the hippocampus, in any case, the reason might be the ultrastructural reorganization of the hippocampus such as mossy fiber sprouting due to fever.[5] Hippocampal sclerosis is characterized by gliosis, neuronal death, and abnormal remodeling of neuronal fibers histologically.[6]

Hyperthermia has been observed to lead to brain injury in several studies, including traumatic brain injury,[6,7] hypoxia-ischemia in the immature brain,[7,8] adult brain ischemia[9–14] and kainic acid-induced seizures after ischemia in the immature rat brain.[15] It has been described that hyperthermia, at least if applied shortly after IR, enhances the response of central nervous system (CNS) tissue to IR,[16,17] and that hyperthermia dose-dependently increased the rate of IR-induced malformations in cultured mouse embryos.[18] According to previous knowledge, hyperthermia caused neuronal cell death via apoptosis and necrosis by means of harming presynaptic and postsynaptic membranes.[5]

CONTACT Gozde Erkanli Senturk gozdeerkanli@yahoo.com; gozde.erkanlisenturk@istanbul.edu.tr Cerrahpasa Faculty of Medicine, Department of Histology and Embryology, Istanbul University-Cerrahpasa, Istanbul, Turkey

© 2020 Taylor & Francis Group, LLC

Different regions of the brain have their own radiosensitive periods during embryonic development. Prenatal exposure to radiation causes remarkable histological changes in the brain. Offsprings of the irradiated mothers showed microcephaly in rats. However, there is no detailed study showing the histological changes in the hippocampus exposed to prenatal irradiation. Fukuda et al. showed the effects of hypothermia and hyperthermia by examining histological changes and the distribution of mossy fiber terminals of granule cells in the rat hippocampus in dose-related irradiation models.[17] Exposure to radiation causes toxicity to normal brain tissue; however, ultrastructural changes are not well investigated yet, as well as synaptic alterations.[19]

To our knowledge, there is no study showing the synaptic alterations after in utero radiation and postnatal hyperthermia in the rat brain tissue. The aim of the present study was to observe how synapses change in the CA3 and DG regions of the dorsal hippocampus of rats after antenatal radiation and postnatal hyperthermia.

Material and methods

Animals and experimental design

Wistar albino rats and their litters were included in the study. Rats were daily controlled by examining vaginal swabs. The day with confirmed insemination was accepted as Embryonic day 0 (E0). The day (E21 or E22) birth occurred was accepted as postnatal day 0 (P0).

Rat pups were housed with their mothers until they were weaned at P21. All animals were maintained on a 12-h light/dark cycle with an average room temperature of 21 ± 3°C and with food/water available ad libitum. This experimental study was approved by the Animal Care and Ethical Committee for Experimental Animals at Marmara University.

There were four experimental groups in each of the two time points: 3rd and 6th months. The groups were designed as follows:

1. Irradiation (IR) group (n = 8): Rats were only exposed to 100 cGy radiation on E17.
2. Hyperthermia (HT) group (n = 7): Rats were only exposed to hyperthermia on day P10.
3. Irradiation and hyperthermia (IR+HT) group (n = 7): Rats were subjected to 100 cGy irradiation on E17 and thereafter their litters were exposed to hyperthermia on day P10.
4. Sham-operated (control) group (n = 8): No irradiation and no hyperthermia was applied to age-matched control rats.

Animals were sacrificed 3 or 6 months after experimental procedures.

Exposure to IR and HT

Hyperthermia and radiation were applied in accordance with our previous study.[20] Irradiation exposure was applied as follows: the pregnant rats were anesthetized with ketamine (100 mg/kg) and placed in an irradiator device. On E17, the abdomens of the rats were exposed to 100 cGy radiation on single fraction by using a cobalt 60 teletherapy system with SSD technique. Hyperthermia application was applied as follows: the litters of the rats which were exposed to irradiation in utero and another group of litters without exposure to irradiation were subjected to hyperthermia by heating them with a heating machine (where rectal temperatures reached 40 ± 0.10°C) on day P10. The duration of the hyperthermia sessions was 10 ± 5 minutes until the rectal temperature reached 40 ± 10°C and behavioral changes started.

Transmission electron microscopic procedures

Rats were anesthetized with 10 mg/kg xylazine hydrochloride and 100 mg/kg ketamine 3 or 6 months after the irradiation and/or hyperthermia. Perfusion was done with a solution of 0.2% glutaraldehyde, 3% paraformaldehyde, and 0.1% picric acid in 0.1 M HEPES buffer (pH 7.4). After decapitation, brains were incubated in the same fixative overnight at 4°C. Afterward, tissues were rinsed in HEPES buffer and 300-µm-thick serial sections were obtained in coronal plane with a Leica VT1000R vibratome. Hippocampal tissues were dissected to separate CA1-DG and CA2-CA3 regions, subjected to routine electron microscopic procedures, and embedded into epoxy resin. Semi-thin sections (1 µm thick) were taken from epon blocks by a Leica Ultracut

R ultramicrotome for proper orientation and stained with toluidine blue. Then, thin sections (60 nm thick) were placed on copper grids, contrasted with uranyl acetate and lead citrate and examined under a transmission electron microscope (JEOL 1200 EX II, attached to an SIS Morada CCD camera system). In each section, at least five micrographs were taken randomly at x20k magnification. Synapses were counted, divided by the area of the micrograph, and statistical analysis was performed. Synapse counting was performed by two blind observers according to previous method.[21]

Statistical analysis

All data were analyzed by Graph Pad Prism 5.0. Mean±SD were evaluated by ANOVA and posthoc tests for multiple comparisons. $P < .05$ were considered significant.

Results

Morphological evaluation

Normal organization and neurons of the hippocampus was observed in semi-thin sections of the control group. Dark necrotic neurons, vacuolization of the neuropil and periglial edema in the CA3 region and dispersion of granule cell layer of DG were seen in HT, IR and IR+HT 3rd month groups. In the 6th month groups, all morphological abnormalities were more pronounced. Ectopic and degenerating neurons were seen in the CA3 and DG regions in HT, IR and IR+HT groups (Figure 1).

Ultrastructural alterations

Normal ultrastructure of neurons and mossy fiber terminals in the CA3 region and myelinated axons in the DG region were seen in the control group. Degenerated neurons and vacuoles in mossy fiber terminals in the CA3 region, and damaged myelinated axons in the DG region were observed in all of the experimental groups. Degeneration of axons and damage in the synaptic terminals was severe in IR+HT groups in 3rd and 6th months (Figure 2).

Synapse count

In the CA3 region; synaptic number was significantly increased in IR-6th month and IR+HT-3rd month groups, compared to the control group. The number of synapses was significantly increased in the HT-3rd month group, compared to the control group in the DG region. In HT-3rd month group, synapses of the CA3 were increased in number insignificantly when compared to control ($p < .01$). A tendency for an increased number of synapses was seen in the other experimental groups in the CA3 and DG regions compared to the control groups; however, the differences were not statistically significant (Figure 3). In the CA3 region, the number of synapses was increased in IR-6th month and IR+HT-3rd month groups when compared to the control group ($p < .01$).

Conclusion

According to our results, a double hit with irradiation and hyperthermia leads to neural damage which resembles hippocampal sclerosis due to synaptic alterations. We showed that the CA3 region was more sensitive to irradiation when compared to hyperthermic injury of the synapses in the 6th month groups. Moreover, hyperthermia and irradiation together increased the number of CA3 synaptic terminals 3 months after the insult. However, these changes in synaptic organization were reversible in long term, after in utero radiation and postnatal hyperthermia.

Data showed that hyperthermic stress alters neuronal cell membrane and synaptic function. Swollen synapses with damage to both pre- and post-synaptic membranes are common in the brain after hyperthermic injury.[5] According to our morphological results, hyperthermia leads to ectopic neurons as well as neuronal death. Moreover, our ultrastructural data showed that it caused an increase in synaptogenesis in DG region after 3 months.

Time-dependent hippocampal volume reduction was observed in the molecular layer and subiculum of the hippocampus, as well as in the granule cell layer, in patients with nasopharyngeal carcinoma after radiotherapy.[22]

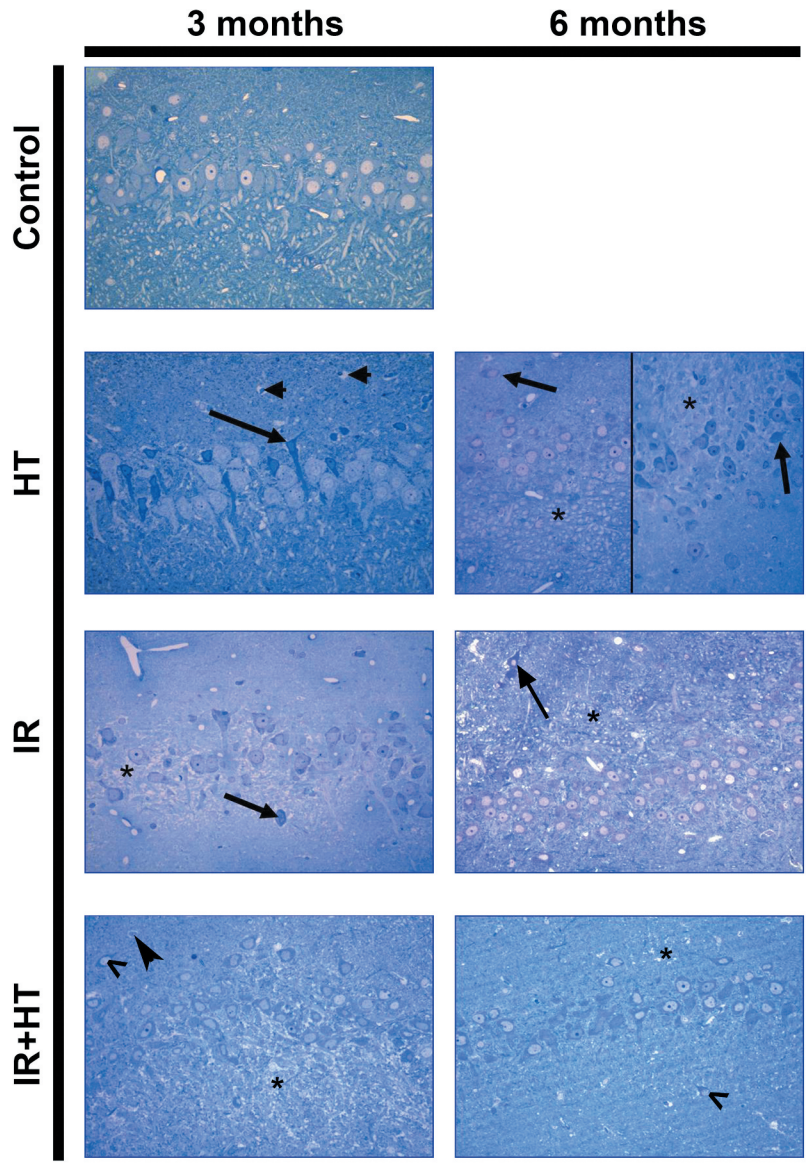

Figure 1. Representative photomicrographs of the CA3region of the hippocampus in all experimental groups. Normal morphology of the CA3 region in the control group. Dark necrotic(→), ectopic (>) neurons, vacuolization of neuropil (*) and periglial edema (▶) in the CA3 region of IR+HT, IR and HT groups after 3 and 6 months. Toluidine blue staining. Original magnification: x400.

Numerous studies have examined the effects of irradiation on the behavior or learning ability of rats exposed to radiation in utero. Around 0.27 cGy radiation caused histological abnormalities and infrapyramidal mossy fibers were detected in the stratum oriens of the CA3 region.[23] Expressions of Nr1 and GluR1 decreased in irradiated hippocampus and radiation modulated spine morphology in the DG and CA1 regions of the hippocampus.[24] In our previous study, we showed that 100 cGy radiation led to hippocampal abnormalities and decreased neuronal cell numbers in the CA3 and DG of the hippocampus.[20] Our present study showed that 100 cGy radiation caused abnormal neurons, and damage in myelin sheath as well as an increment of the synapses in CA3 region in long term.

Previous data showed that last differentiation of increased numbers of developing dentate granule cells (DGCs) parallel the time course of mossy fiber remodeling induced by prolonged seizure activity. Additionally, some parts of newly generated DGCs contribute to the atypical axonal reorganization that takes place in both CA3 and the dentate inner molecular layer after pilocarpine-induced status epilepticus.[25] These results emphasize that

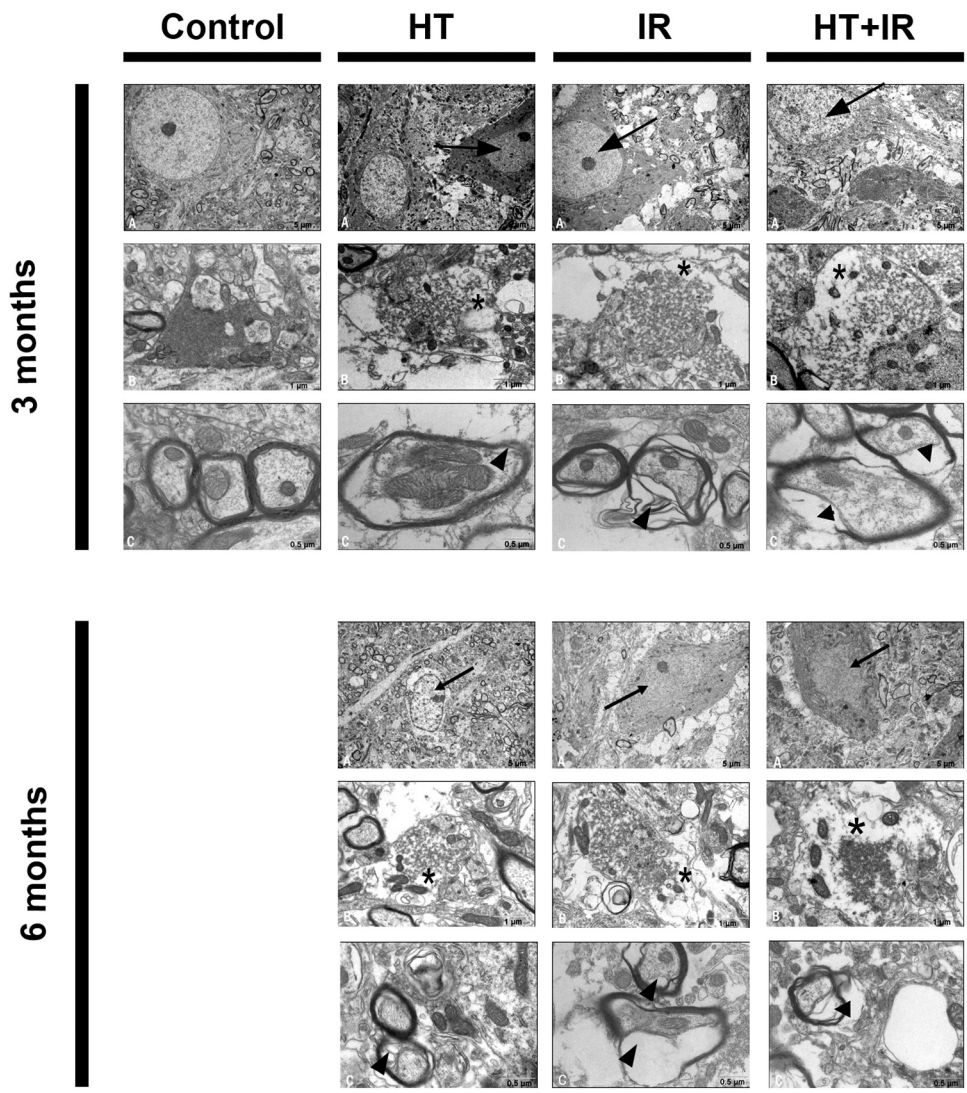

Figure 2. Representative electron micrographs of the CA3 and DG regions of hippocampus in all experimental groups. Normal morphology of (a) neuron, (b) mossy fiber terminal in the CA3 region; (c) myelinated axon in the DG region of the control group. (a) degenerated neuron (→), (b) vacuoles in mossy fiber terminal (*) in the CA3 region; C) damaged myelinated axon (▶) in the DG region of IR+HT, IR, HT groups after 3 and 6 months. Bars: (a) 5 µm, (b) 1 µm, (c) 0.5 µm.

dentate granule stem cells are sensitive to low dose irradiation and that seizure-induced mossy fiber reorganization occurs and maintains despite prolonged inhibition of neurogenesis. Furthermore, newly sprouted axon collaterals from preexisting, mature DGCs can serve as a substrate for mossy fiber remodeling after seizure-induced injury.[26] In our study synapses increased in the CA3 region of IR-6th month and IR+H-3rd month groups. This indicated that CA3 was more sensitive to radiation. Additionally, synapse count of IR+HT-6th month group was decreased compared to IR-6th month and IR+HT-3rd month groups in the CA3 region. DG synapses were significantly more in the HT-3rd month group.

The effects of mild hypothermia and hyperthermia for 4 h after IR were studied in postnatal day 9 rats.[16] One hemisphere was irradiated with a single dose of 8 Gy, and animals were randomized to normothermia, hypothermia or hyperthermia groups. Ionizing radiation induced acute cell death in the DG subgranular zone and the subventricular zone. Abnormal myelination was also observed. Cellular injury was observed to be faster when the body temperature was higher.[17] Additionally, other studies reported that hyperthermia increased the

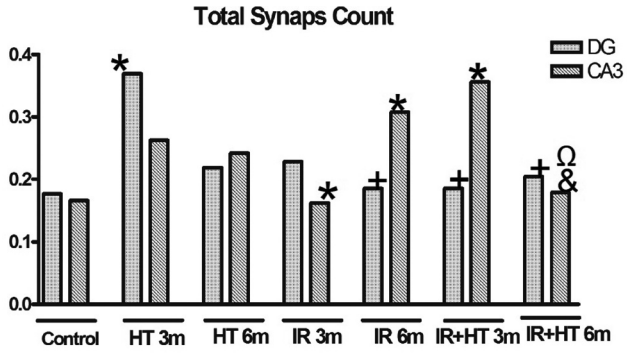

Figure 3. Total synapse count of all experimental groups in the CA3 and DG regions of the hippocampus. *: $p < .05$, **: $p < .01$, ***: $p < .001$ vs control; +: $p < .05$ vs HT-3rd month; &: $p < .05$ vs IR-6th month; Ω: $p < .05$ vs IR+HT-3rd month.

sensitivity to the radiation of the CNS in adult animals[16] and embryos.[18] Hyperthermia may accelerate the adverse side-effects after radiation therapy to the developing brain.[17]

Consequently, according to our data, synaptic degeneration increased especially in the CA3 region 6 months after irradiation. However, synaptic damage was reversed in hyperthermia and irradiation double hit group after 6 months and synaptic counts were almost similar to the control group. Therefore, we thought that application of postnatal hyperthermia caused increment of synapses in the CA3 region after in utero irradiation in long term. However, application of hyperthermia alone led to more damage in the DG compared to the CA3.

In conclusion, the present study suggests that the increased number of synapses in the rat hippocampus may be due to mossy fiber sprouting, possibly caused by antenatal irradiation and/or postnatal hyperthermia. The increase in the number of synapses which was triggered by hyperthermia can be the result of re-synaptogenesis in order to compensate the seizures or neuronal damage.

Disclosure statement

Authors declared that there is no conflict of interest.

Funding

This study was supported by Marmara University Scientific Research Commission (SAG-BGS-150107-0015).

ORCID

Gozde Erkanli Senturk http://orcid.org/0000-0002-8235-4157
Ozlem Tugce Cilingir-Kaya http://orcid.org/0000-0002-2591-9174
Cihan Isler http://orcid.org/0000-0001-8365-3338

References

1. Camfield C, Camfield P. Febrile seizures. In: Rojer EJ, Bureau M, Dravet P, Genton CA, Tassinari A, Wolf P, eds. *Epileptic Syndromes in Infancy, Childhood and Adolescence*. 4th ed. Montrouge: John Libbey Eurotext; 2005:159–169.
2. Tanabe T, Hara K, Shimakawa S, Fukui M, Tamai H. Hippocampal damage after prolonged febrile seizure: one case in a consecutive prospective series. *Epilepsia*. 2011;52:837–840. doi:10.1111/j.1528-1167.2010.02958.x.
3. Ito M, Takahashi H, Yano H, et al. High mobility group box 1 enhances hyperthermia-induced seizures and secondary epilepsy associated with prolonged hyperthermia-induced seizures in developing rats. *Metab Brain Dis*. 2017;32:2095–2104. doi:10.1007/s11011-017-0103-4.
4. M Js B, Hami J, Haghir H, Rastin M, Sazegar G. Evaluation of Bax and Bcl-2 proteins expression in the rat hippocampus due to childhood febrile seizure. *Iran J Child Neurol*. 2016;10:53–60.
5. Sendrowskia K, Sobanieca P, Poskrobkob E, Rusakc M, Sobanieca W. Unfavorable effect of levetiracetam on cultured hippocampal neurons after hyperthermic injury. *Pharmacol Rep*. 2017;69:462–468. doi:10.1016/j.pharep.2017.01.020.
6. Ding X, Wu H, Ji S, et al. The p75 neurotrophin receptor regulates cranial irradiation induced hippocampus-dependent cognitive dysfunction. *Oncotarget*. 2017 Aug:25:40544–40557. doi:10.18632/oncotarget.16492.
7. Yu CG, Jagid J, Ruenes G, W D D, A E M, Yezierski RP. Detrimental effects of systemic hyperthermia on locomotor function and histopathological outcome after traumatic spinal cord injury in the rat. *Neurosurgery*. 2001;49:152–158. discussion 158–159
8. H J T, N C T, K E S, Raghupathi R, McIntosh TK. Hyperthermia following traumatic brain injury: a critical evaluation. *Neurobiol Dis*. 2003;12:163–173. doi:10.1016/S0969-9961(02)00030-X.
9. Fukuda H, Tomimatsu T, Kanagawa T, et al. Postischemic hyperthermia induced caspase-3 activation in the newborn rat brain after hypoxia-ischemia and exacerbated the brain damage. *Biol Neonate*. 2003;84:164–171. doi:10.1159/000071952.
10. Mishima K, Ikeda T, Yoshikawa T, et al. Effects of hypothermia and hyperthermia on attentional and spatial learning deficits following neonatal hypoxia-ischemic

insult in rats. *Behav Brain Res*. 2004;151:209–217. doi:10.1016/j.bbr.2003.08.018.

11. Dietrich WD, Busto R, Valdes I, Loor Y. Effects of normothermic versus mild hyperthermic forebrain ischemia in rats. *Stroke*. 1990;21:1318–1325. doi:10.1161/01.STR.21.9.1318.
12. Minamisawa H, Mellergard P, Smith ML, Bengtsson F, et al. Preservation of brain temperature during ischemia in rats. *Stroke*. 1990;21:758–764. doi:10.1161/01.STR.21.5.758.
13. Kim Y, Busto R, Dietrich WD, Kraydieh S, Ginsberg MD. Delayed postischemic hyperthermia in awake rats worsens the histopathological outcome of transient focal cerebral ischemia. *Stroke*. 1996;27:2274–2280. discussion 2281. doi:10.1161/01.STR.27.12.2274.
14. Ginsberg MD, Busto R. Combating hyperthermia in acute stroke: a significant clinical concern. *Stroke*. 1998;29:529–534. doi:10.1161/01.STR.29.2.529.
15. Yager JY, Armstrong EA, Jaharus C, Saucier DM, Wirrell EC. Preventing hyperthermia decreases brain damage following neonatal hypoxic-ischemic seizures. *Brain Res*. 2004;1011:48–57. doi:10.1016/j.brainres.2004.02.070.
16. Sminia P, van der Zee J, Wondergem J, Haveman J. Effect of hyperthermia on the central nervous system: a review. *Int J Hyperthermia*. 1994;10:1–30. doi:10.3109/02656739409009328.
17. Fukuda A, Fukuda H, Johnsson M, et al. Progenitor cell injury after irradiation to the developing brain can be modulated by mild hypothermia or hyperthermia. *J Neurochem*. 2005;94:1604–1619. doi:10.1111/j.1471-4159.2005.03313.x.
18. Nakashima K, Kawamata A, Fujiki I, Fujiki Y. The individual and combined effects of X-irradiation and hyperthermia on early somite mouse embryos in culture. *Teratology*. 1991;44:635–639. doi:10.1002/tera.1420440606.
19. Hinzman CP, Baulch JE, Mehta KY, Gill K, Limoli CL, Cheema AK. Exposure to ionizing radiation causes endoplasmic reticulum stress in the mouse hippocampus. *Radiat Res*. 2018;190(5):483–493. doi:10.1667/RR15061.1.
20. Erkanli Senturk G, Isler C, Kemerdere R, et al. Hippocampal neuronal damage in rats exposed to a double hit: irradiation and hyperthermia. *Turk Neurosurg*. 2011;21:454–460.
21. Al-Harbi AN, K M K, Rahman A. Developmental vitamin D deficiency affects spatial learning in wistar rats. *J Nutr*. 2017;147:1795–1805.
22. Lv X, He H, Yang Y, et al. Radiation-induced hippocampal atrophy in patients with nasopharyngeal carcinoma early after radiotherapy: a longitudinal MR-based hippocampal subfield analysis. *Brain Imaging Behav*. 2019;13(4):1160–1171. doi:10.1007/s11682-018-9931-z.
23. Mikia A, Sawadab K, Sunb X, Hisanob S, Takeuchia Y, Fukui Y. Abnormal distribution of hippocampal mossy fibers in rats exposed to X-irradiation in utero. *Dev Brain Res*. 1999;112:275–280. doi:10.1016/S0165-3806(98)00177-1.
24. Carr H, Alexander TC, Groves T, et al. Early effects of 16O radiation on neuronal morphology and cognition in a murine model. *Life Sci Space Res (Amst)*. 2018;17:63–73. doi:10.1016/j.lssr.2018.03.001.
25. Parent JM, Yu TW, Leibowitz RT, Geschwind DH, Sloviter RS. Lowenstein DH Dentate granule cell neurogenesis is increased by seizures and contributes to aberrant network reorganization in the adult rat hippocampus. *J Neurosci*. 1997;17:3727–3738. doi:10.1523/JNEUROSCI.17-10-03727.1997.
26. Parent JM, Tada E, Fike JR, Lowenstein DH. Inhibition of dentate granule cell neurogenesis with brain irradiation does not prevent seizure-induced mossy fiber synaptic reorganization in the rat. *J Neurosci*. 1999;19(11):4508–4519. doi:10.1523/JNEUROSCI.19-11-04508.1999.