Clinical Case Report

Medicine®

OPEN

Arterial occlusion after total knee arthroplasty despite minimal invasive technique in aneurysm at popliteal artery

Case report

Myung Rae Cho, MD, Kyung Tae Kim, MD, Won Kee Choi, MD*

Abstract

Rationale: Arterial occlusion, a rare condition after total knee arthroplasty (TKA), may cause fatal outcomes if not treated on time. We report a case of arterial occlusion after undergoing navigated TKA with no tourniquet use, in a patient at high risk of postoperative arterial occlusion due to the patient's ipsilateral popliteal artery aneurysm.

Patients concerns: A 79-year-old man presented with several years of left knee joint pain. Nine years earlier, the patient underwent vascular graft surgery on his right knee due to occlusion in his right popliteal artery. On physical examination, the patient showed antalgic gait due to the pain in his left knee.

Diagnosis: Preoperative examination for arterial blood flow demonstrated reduced blood flow of the patient's right dorsalis pedis and right posterior tibial artery, with ankle-brachial index of 0.41 and 0.41. The blood flow of the left dorsalis pedis and left posterior tibial artery remained normal, with ankle-brachial index of 1.16 and 1.10. Femoral artery computed tomography (CT) scan revealed left popliteal artery aneurysm with mural thrombus, with occlusion of the left anterior tibial artery (ATA). The left peroneal artery and posterior tibial artery remained patent.

Intervention: Total knee arthroplasty using navigation without the use of tourniquet.

Outcomes: Occlusion of the posterior tibial artery trunk was revealed with Doppler ultrasound and femoral artery CT several hours postoperatively, and the patient underwent thromboembolectomy at the very next day.

Lessons: In patients at high risk of postoperative arterial occlusion, such as patients with arterial aneurysm with mural thrombus, arterial occlusion may occur despite surgical techniques with minimal damage to the vessels. We found out that diseases of the artery might be a contraindication for TKA, and when TKA may be performed in high-risk patients, close cooperation with a vascular surgeon is a must.

Abbreviation: CT = computed tomography.

Keywords: artery occlusion, total knee arthroplasty, tourniquet

1. Introduction

Arterial occlusion after total knee arthroplasty (TKA) is a rare but fatal condition.[1] The reported incidence of vascular complications ranges from 0.03% to 0.017%.[2–4] We report a case of postoperative arterial occlusion in a patient with arterial disease in the ipsilateral leg, after undergoing navigated TKA with no tourniquet use, for minimal damage to the vessels during surgery.

Editor: N/A.

The authors have no conflicts of interest to disclose.

Department of Orthopaedic Surgery, College of Medicine, Daegu Catholic University, Daegu, Korea.

** Correspondence: Won Kee Choi, Department of Orthopaedic Surgery, Daegu Catholic University Hospital, 3056-6, Daemyung-4-dong, Nam-gu, Daegu, Korea (e-mail: cwk1009@hanmail.net).*

Copyright © 2018 the Author(s). Published by Wolters Kluwer Health, Inc. This is an open access article distributed under the terms of the Creative Commons Attribution-Non Commercial-No Derivatives License 4.0 (CCBY-NC-ND), where it is permissible to download and share the work provided it is properly cited. The work cannot be changed in any way or used commercially without permission from the journal.

Medicine (2018) 97:41(e12719)

Received: 25 May 2018 / Accepted: 14 September 2018

http://dx.doi.org/10.1097/MD.0000000000012719

Several cases of postoperative arterial occlusion of after TKA have been reported and most of the cases occurred with lack of concerns of post operative arterial occlusion.[1,5,6] While a case of arterial occlusion after TKA without the use of tourniquet use have been reported, occlusion in such case occurred at the previously existing vascular graft.[4,7] In our case, after acknowledging the risk for arterial occlusion preoperatively, we did not use tourniquet, and bone cutting was performed under the assistance of computer navigation in order to minimize arterial damage during surgery. A vascular surgeon was in close contact throughout the surgery process. Through Doppler ultrasound scanning, vessels were found to be patent until the end of the surgical process. However, arterial occlusion was revealed just after the patient left the operating room. On reporting this case, we emphasized that aneurysm of the left popliteal artery is a high-risk factor for arterial occlusion after total surgery. Close cooperation with vascular surgeons throughout the surgery is necessary.[4,8]

Informed written consent was obtained from the patient for publication of this case report and accompanying images.

2. Case report

A 79-year-old man presented with several years of left knee joint pain. Nine years earlier, the patient underwent vascular graft



Figure 1. Scanogram revealed valgus osteoarthritis on his left knee. Preoperative scanogram (A). Post operative scanogram (B).

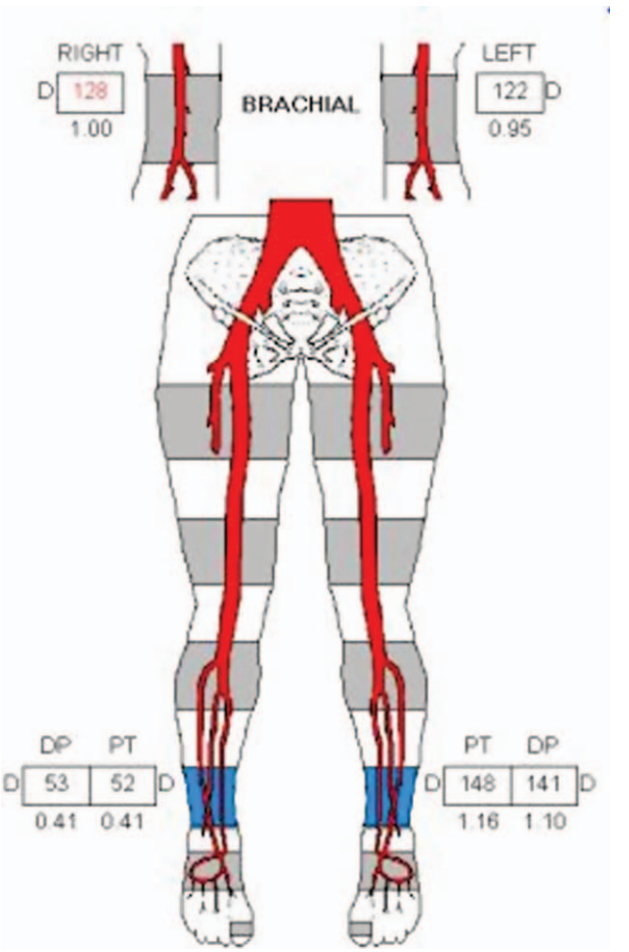

Figure 2. Preoperative examination for arterial blood flow. Examination revealed the blood flow of the left dorsalis pedis and left posterior tibial artery remained normal, with 1.16 and 1.10 of ankle-brachial index.

surgery on his right knee due to occlusion in his right popliteal artery. On physical examination, the patient showed antalgic gait due to the pain in his left knee. The patient underwent TKA on his right knee 11 years earlier. Scanogram revealed valgus osteoarthritis on his left knee. Kellgren Lawrence grade of his left knee was 4, and the Hip-knee-ankle angle showed valgus of 7.85 degrees (Fig. 1). Preoperative function, by means of Knee Society Score (KSS), was 30 of KSS knee and 15 of KSS function. Examinations for arterial blood flow and femoral artery computed tomography (CT) scan were performed for the decision of TKA. Preoperative examination for arterial blood flow demonstrated reduced blood flow of the patient's right dorsalis pedis and right posterior tibial artery, with ankl-brachial

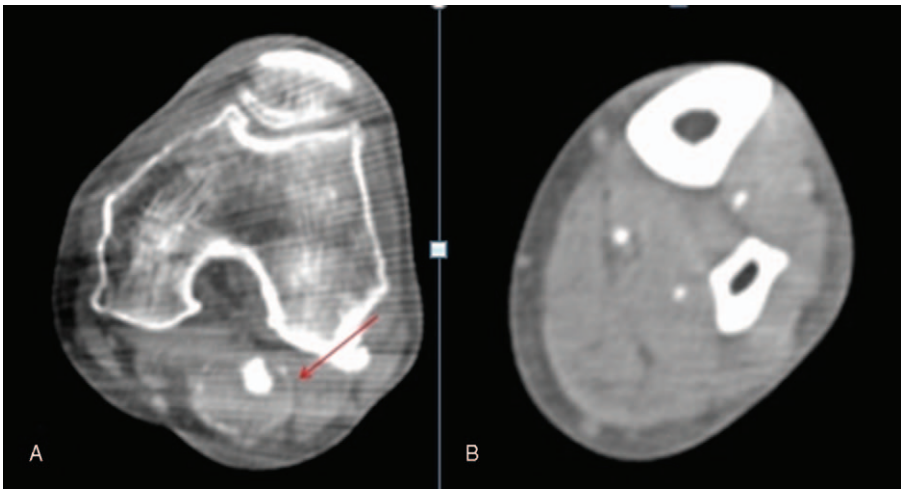

Figure 3. Femoral artery CT scan revealed aneurysm (arrow) at the left popliteal artery with mural thrombus (A), with occlusion of the left ATA, while the left peroneal artery and PTA remained patent (B). ATA = anterior tibial artery, CT = computed tomography, PTA = posterior tibial arterty.

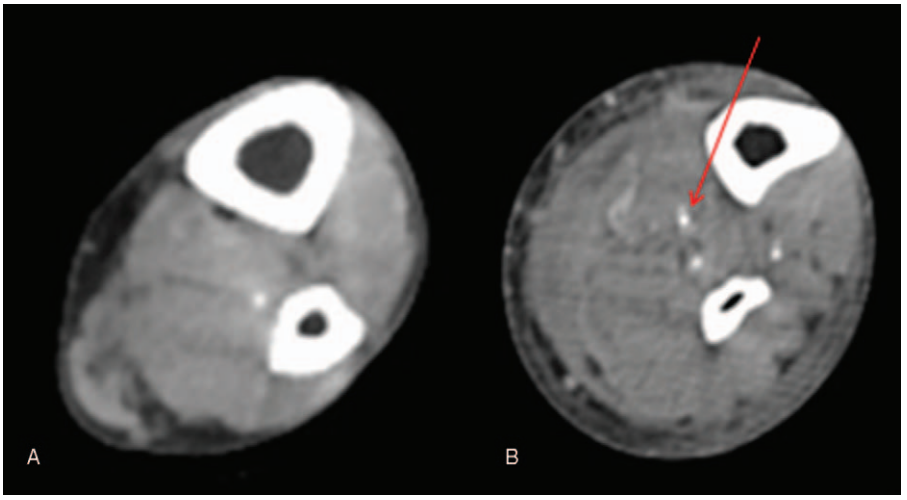

Figure 4. The CT scan revealed occlusion of the posterior tibial artery with patent peroneal artery (A). After thromboembolectomy, posterior tibial artery was repurfused (B). CT computed tomography.

index of 0.41 and 0.41. The blood flow of the left dorsalis pedis and left posterior tibial artery remained normal, with ankle-brachial index of 1.16 and 1.10 (Fig. 2). Femoral artery CT scan revealed aneurysm at the left popliteal artery with mural thrombus, with occlusion of the left anterior tibial artery (ATA), while the left peroneal artery and PTA remained patent (Fig. 3). After consulting the patient about the results, alongside with the patient's strong desire, we decided to perform TKA. During preoperative planning, in order to minimize vascular damage during surgery, first, we planned to not use tourniquet. Second, we planned to use computer navigation during bone cutting. Third, we planned to check the blood flow using Doppler ultrasonography during surgery. The surgery was performed as planned, and through Doppler ultrasound scanning during and right after surgery, blood flow was examined. Doppler ultrasound was performed in the patient's room at the very day of surgery. Blood flow of the posterior tibial artery at the medial side of the ankle was not detectable, and the patient underwent femoral artery CT scan. The CT scan revealed occlusion of the posterior tibial artery (Fig. 4), and at the following day, the patient underwent surgical thromboembolectomy by the department of vascular surgery. Blood flow of the posterior tibial artery was intact on the Doppler ultrasound after thromboembolectomy.

After consult with the department of vascular surgery, the patient underwent 7 days of anticoagulation therapy using low-molecular-weight heparin. During anticoagulation, physical therapy was not permitted to the patient, and at 7 days after thromboembolectomy, the patient was allowed to go through the routine rehabilitation protocol. Scanogram taken at the follow-up session at 3 months after surgery showed HKA ankgle valgus of 1.2 degrees and the Knee Society Score of 40 in KSS knee and 40 KSS function. Examination for arterial blood flow taken at the follow-up session at 3 months after surgery demonstrated the blood flow of the left dorsalis pedis and left posterior tibial artery, with 1.08 and 1.17 of ankle-brachial index (Fig. 5).



Figure 5. At 3 months after surgery demonstrated the blood flow of the left dorsalis pedis and left posterior tibial artery, with 1.08 and 1.17 of ankle-brachial index.

3. Discussion

Arterial occlusion may rarely occur after TKA). However, since chronic arterial problem arises among 2% of patients who underwent TKA,[7] surgeons must always be concerned about

such problems when planning TKA. Previous studies have pointed out popliteal artery aneurysm as a high-risk factor for postoperative arterial occlusion after TKA.[6] Besides, presence of an arterial bypass graft, revision surgery, and so forth have been reported as risk factors for postoperative arterial occlusion after TKA.[8] Many surgeons have reported the technique of not using tourniquets during TKA in high-risk patients. Especially, postoperative arterial occlusion in patients with previous surgical history of vascular graft has been reported, despite no tourniquet use.[7]

In our case, since the patient had a history of popliteal artery aneurysm, our team was already aware of the risk of postoperative arterial occlusion. During the surgery, we did not use tourniquet and we also performed the surgery with the assistance of computer navigation for the process of bone cutting, instead of using femoral intramedullary guide rods which may increase indirect vessel injury during its insertion into the bone. Right after the surgery was finished, blood flow to the lower extremities was examined by means of Doppler ultrasound scanning. However, when we re-examined the blood flow by Doppler ultrasound several hours postoperatively, the blood flow was not detectable. Despite preoperative planning in order to minimize vascular injury, delayed arterial occlusion occurred.

While 30% of all thromboembolic events are detected during the surgery, 30% of the events are identified within 24 postoperative hours, and 35% of the events are identified after 24 postoperative hours.[8] Although surgeons may find out that the blood flow is patent during surgery, surgeons must be aware of thromboembolic events throughout the hospitalization period.

In our case, although we have assured the patency of the blood flow using Doppler ultrasound during surgery, arterial occlusion was confirmed after the patient left the operating room. In case of patients at high risk for arterial occlusion, we recommend regular assessments for the blood flow throughout the hospitalization period.

The patient in our case achieved recovery of the blood flow by surgical thromboembolectomy within 24 hours from occlusion. However, according to previous studies, clinical results of postoperative arterial occlusion after TKA are not promising.[8] The clinical results of the patient in our case may be due to prompt surgical intervention (within 24 hours) after careful postoperative observation.

We experienced a case of postoperative arterial occlusion after TKA in a patient at high risk of postoperative arterial occlusion due to the patient's popliteal artery aneurysm, despite performing surgical techniques with low possibility of indirect injury to the vessels. Once again, we emphasize that popliteal artery aneurysm is a high-risk factor for postoperative arterial occlusion after TKA and that close cooperation with a vascular surgeon is necessary.

4. Conclusion

Despite the efforts to minimize vascular injury, we have experienced a case of postoperative arterial occlusion after TKA in a patient with popliteal artery aneurysm. Before planning total knee replacement (TKR) in such highly risked patients, we recommend thorough consultation to the patient and close cooperation with vascular surgeons.

Author contributions

Conceptualization: Won Kee Choi.
Investigation: Kyung Tae Kim.
Supervision: Myung Rae Cho.
Writing – original draft: Won Kee Choi.

References

[1] Inomata K, Sekiya I, Otabe K, et al. Acute arterial occlusion after total knee arthroplasty: a case report. Clin Case Rep 2017;5:1376–80.
[2] Bayne CO, Bayne O, Peterson M, et al. Acute arterial thrombosis after bilateral total knee arthroplasty. J Arthroplasty 2008;23:1239.e1–e6.
[3] Langkamer VG. Local vascular complications after knee replacement: a review with illustrative case reports. Knee 2001;8:259–64.
[4] Calligaro KD, DeLaurentis DA, Booth RE, et al. Acute arterial thrombosis associated with total knee arthroplasty. J Vasc Surg 1994;20:927–30.
[5] Matziolis G, Perka C, Labs K. Acute arterial occlusion after total knee arthroplasty. Arch Orthop Trauma Surg 2004;124:134–6.
[6] Chikkanna JK, Sampath D, Reddy V, et al. Popliteal artery thrombosis after total knee replacement: an unusual complication. J Clin Diagn Res 2015;9:RJ01–2.
[7] Turner NS3rd, Pagnano MW, Sim FH. Total knee arthroplasty after ipsilateral peripheral arterial bypass graft: acute arterial occlusion is a risk with or without tourniquet use. J Arthroplasty 2001;16:317–21.
[8] Pal A, Clarke JM, Cameron AE. Case series and literature review: popliteal artery injury following total knee replacement. Int J Surg 2010;8:430–5.