DOI:10.1111/j.1477-2574.2011.00401.x HPB

ORIGINAL ARTICLE

Biliary complications after right lobe living donor liver transplantation: a single-centre experience

Onur Yaprak[1], Murat Dayangac[1], Murat Akyildiz[2], Tolga Demirbas[1], Necdet Guler[1], Fisun Bulutcu[1], Nuray Bassullu[3], Elif Akun[4], Yildiray Yuzer[1] & Yaman Tokat[1]

[1]Florence Nightingale Hospital, Hepatobiliary and Organ Transplant Center, Departments of [2]Gastroenterology and [3]Pathology, Bilim University, and [4]Department of Internal Medicine, Gayrettepe Florence Nightingale Hospital, Istanbul, Turkey

Abstract

Background: Biliary complications that developed after right lobe liver transplantation from living donors were studied in a single centre.

Methods: From 2004 to 2010, 200 consecutive living donor right lobe liver transplantations were performed. The database was evaluated retrospectively. Biliary complications were diagnosed according to clinical, biochemical and radiological tests. The number of biliary ducts in the transplanted graft, the surgical techniques used for anastomosis, biliary strictures and bile leakage rates were analysed.

Results: Of a total of 200 grafts, 117 invloved a single bile duct, 77 had two bile ducts and in six grafts there were three bile ducts. In 166 transplants, the anastomosis was performed as a single duct to duct, in 21 transplants double duct to ducts, in one transplant, three duct to ducts and in 12 transplants as a Roux-en-Y reconstruction. In all, 40 bile leakages (20%) and 17 biliary strictures (8.5%) were observed in 49 patients resulting in a total of 57 biliary complications (28.5%). Seventeen patients were re-operated (12 as a result of bile leakages and five owing to biliary strictures).

Conclusion: Identification of more than one biliary orifice in the graft resulted in an increase in the complication rates. In grafts containing multiple orifices, performing multiple duct-to-duct (DD) or Roux-en-Y anastomoses led to a lower number of complications.

Keywords

liver transplantation, biliary complications, living donor, anastomosis, bile leakage

Received 17 August 2011; accepted 14 September 2011

Correspondence

Onur Yaprak, Florence Nightingale Hastanesi, Organ Nakil Merkezi, Abide-i Hurriyet Cad. 34381, Sisli, Istanbul, Turkey. Tel: 90 212 2244950. Fax: 90 212 2244982. E-mail: onuryaprak@hotmail.com

Introduction

In spite of recent advances in surgery and immunosuppression in the field of liver transplantation, biliary complications continue to result in considerable morbidity and mortality after surgery. Transplantation from living donors carries a higher risk of biliary complications when compared with cadaveric transplants.

After right lobe transplants from living donors, the incidence of developing a biliary complication has been reported to be as high as 24–60%.[1–3] Several options such as surgical, endoscopic or interventional radiological approaches have been attempted for the treatment of such complications.

The aim of the present study was to discuss the biliary problems encountered after 200 consecutive right lobe liver transplantations from living donors performed at a single centre.

Methods

Between 2004 and 2010, 200 adult-to-adult right lobe and 20 left lobe living donor liver transplantation were performed at Florence Nightingale Hospital Organ Transplantation Center. Donor evaluations were done by volumetric computerized tomography (CT), CT angiography, magnetic resonance cholangiography (MRC) in the pre-operative period and ultrasonography (USG) and cholangiography during the operation. Regarding donor safety, exclusion criteria for right lobe liver donation were remnant liver volume <30% and a biopsy-proven hepatosteatosis of 20%. Regarding recipient's risk, technical features which resulted in donor exclusion were: more than two bile ducts draining the right lobe, more than two right portal vein branches and a complex venous drainage for each of the four right lobe segments. In the donors with

 © 2011 International Hepato-Pancreato-Biliary Association



Figure 1 Single duct to duct (DD)

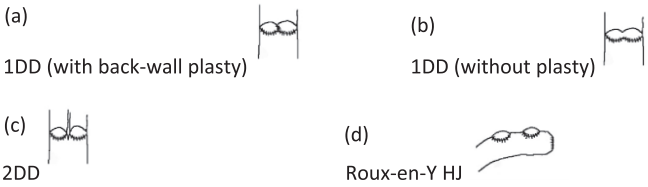

Figure 2 Double duct to duct (DD)

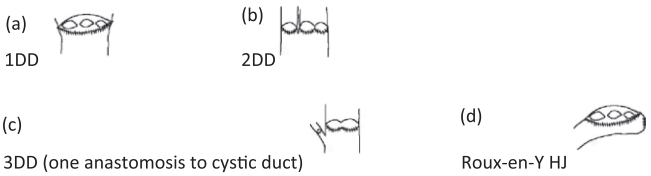

Figure 3 Triple duct to duct (DD)

double right hepatic bile ducts, their recipients were informed about a possible increased risk of biliary complications.

Biliary complications were retrospectively evaluated in 200 right lobe liver transplantations from living donors. Biliary complications were diagnosed according to clinical, biochemical and radiological tests. The number of biliary ducts in the transplanted graft, the surgical techniques used for anastomosis, biliary strictures and bile leakage rates were analysed.

Of a total of 200 grafts, 117 had a single bile duct, 77 grafts had two bile ducts and six grafts had three bile ducts. Figures 1–3 describes all anastomoses types and techniques. In all, 111 of the 117 grafts had single bile ducts, bile anastomoses were performed with 6/0 propylene sutures as interrupted, end-to-end, single duct-to-duct (1DD), whereas in six of them a Roux-en-Y was performed. Of the 77 grafts with two bile ducts, 45 were turned into a single duct at the back table by placing 6/0 propylene sutures to their posterior walls and in the recipient 6/0 propylene interrupted sutures were placed to perform end-to-end 1DD anastomosis. In nine of these 77 grafts, the posterior walls of the bile ducts were already connected; therefore, 6/0 propylene sutures were used for interrupted, end-to-end, IDD anastomosis in the recipient. In 18 grafts containing two bile ducts, the distance between the ducts was more than 3 mm and in such instances, a plasty was not performed and two separate anastomoses were undertaken in the recipient as double duct to duct (2DD). In five grafts with two bile ducts, Roux-en-Y anastomosis was performed. Concerning the six patients with three bile ducts in their grafts, three patients underwent 2DD, one patient had triple anastomosis (one to the cystic duct), one patient had a 1DDand one patient had Roux-en-Y.

A total of 12 patients had Roux-en-Y bilioenteric anastomoses. Six of these patients had primary sclerosing cholangitis as their diagnosis, five had very distant double bile ducts, one had very distant three bile ducts; in these patients duct-to-duct anastomosis was not felt to be safe and, therefore, a Roux-en-Y reconstruction was preferred. Forty patients had external biliary stents placed. In the use of biliary stents, the most influential factor was the presence of more than one bile duct in the graft. In such instances, the tip of the stent was guided towards the posterior section duct whose anastomosis angle lied more deeply.

Donor right hepatectomy

The operation was started with a J-shaped incision combining the median superior and right subcostal approaches. After ligating and cutting the falciform ligament, the right triangular ligament was cut by electrocautery to mobilize the liver. After identifying and cutting individually the retrohepatic veins draining to vena cava, the liver was separated from the retrohepatic vena cava. The right hepatic vein was suspended after ligating and dissecting the hepato-caval ligament. A cholecystectomy was performed after ligating and dissecting the cystic duct and cystic artery. The right hepatic artery and right portal vein were dissected and suspended. With a short-lasting vascular clampage test, the demarcation line between the right and left lobes of the liver was identified and the area from the gall bladder bed to the hepatic vein junction was marked with an electrocautery. The parenchyma was transected with the help of a cavitron ultrasonographic aspirator (CUSA; Valleylab, Boulder, CO, USA) and the vascular and biliary structures were identified within the parenchyma and clipped. After completion of the parenchymal transection, intra-operative cholangiography was used to identify the point where the bile duct was to be transected. After administration of heparin, the right hepatic artery was ligated and transected. After clamping the right portal vein with a vascular clamp, the portal vein was transected above the clamp. The right hepatic vein was clamped with a glover clamp and with a cut above the clamp and then the liver was taken out. The graft was brought to the perfusion table (back table). Hepatic vein, portal vein and bile duct stumps were closed.

Back table

The graft was perfused with histidine-tryptophan-ketoglutarate (HTK) solution from within the portal vein. The bile duct of the graft was irrigated with physiological saline to check whether there was a leak in the parenchyma or not. If there was a leak, that was sutured. If the bile duct had to be taken as double ducts as a result of the anatomical variation and if the distance between the two ducts was not more than 3 mm, two ducts were turned into a single orifice using 6/0 propylene sutures.

Recipient operation

Falciform ligaments were ligated and separated, and the right and left triangular and coronary ligaments were separated. The peritoneum on the medial side of the gastrohepatic ligament and the

© 2011 International Hepato-Pancreato-Biliary Association

caudate lobe was opened and the left side of the liver was completely mobilized. The cystic duct and artery were ligated and separated. The bile duct and hepatic arteries were dissected and were then ligated individually close to the hilus and then separated. As distinct from cadaveric transplantation, the artery and the bile duct were taken from within the hilus were they were kept for as long as possible. The portal vein was skeletonized. The liver, short hepatic veins and caudate lobe branches were ligated, separated and dissected from above the vena cava using a 'piggy-back' technique. By placing vascular clamps, the portal vein was transected from the left-right bifurcation. The hepatic veins were transected from above the vascular clamp and the hepatectomy was completed. The anastomosis was constructed between the right hepatic vein stump and donor right hepatic vein, using continuous 5/0 propylene sutures with an intra-luminal everting end-to-side hepatic vein anastomosis. Portal vein anastomosis was performed using 6/0 propylene sutures. Reperfusion was established by opening the hepatic vein and portal vein clamps. For the hepatic artery anastomosis, 8/0 ethilon sutures were used between the graft and recipient artery and the procedure was completed using the microvascular technique. This was followed by bile duct anastomosis.

For bile duct anastomosis, 6/0 interrupted sutures were placed between the recipient bile duct and the graft bile duct to perform duct-to duct anastomosis with an end-to-end technique or with Roux-en-Y anastomosis to maintain bilioenteric continuity.

Results

There were 152 male and 48 female patients, with a mean age of 50.7 ± 10.7 (16–72) years. According to the Child–Pugh classification, 120 patients were Child C, 60 patients were Child B and 20 patients were Child A. The mean model for end-stage liver disease (MELD) score was 17.2 ± 6.7 (4–47) and the mean body mass index (BMI) was 26.4 ± 3.9 kg/m^2 (15–41). The mean follow-up duration was 27.3 ± 20.5 (4–70) months. Concerning the indications for liver transplants, 71 patients had the hepatitis B virus (HBV), 32 patients had HCV, 26 patients had primary biliary cirrhosis or primary sclerosing cholangitis, 30 patients had hepatocellular carcinoma, 23 patients had cryptogenic causes, 4 patients had alcohol-related problems and 14 patiens had other reasons. Characteristic features of the patients are demonstrated on Table 1.

In 188 out of 200 patients (94%), DD continuity was achieved (166 anastomosis to a single duct, 21 anastomosis to double ducts and 1 anastomosis to triple ducts) and in 12 patients (6%) a Roux-en-Y type bilioenteric anastomosis was performed.

In all, 57 biliary complications developed in 49 patients: 40 bile leakages (20%) and 17 biliary strictures (8.5%). The total rate of biliary complications was 28.5%. A total of 17 patients (12 bile leakages and five biliary strictures) were re-operated. The anastomoses types of bile ducts and their results are shown on Table 2.

Table 1 Characteristic features of the patients (n = 200)

Age (years)	50.7 ± 10.7 (16–72)
MELD	17.2 ± 6.7 (4–47)
BMI	26.4 ± 3.9 (15–41)
Follow-up (month)	27.3 ± 20.5 (4–70)
Gender	
Male	152 (%76)
Female	48 (%24)
Child	
A	20 (%10)
B	60 (%30)
C	120 (%60)
Aetiology	
Hepatitis B/Hepatitis D	71 (%35.5)
Hepatitis C	32 (%16)
PBS,PSC	26 (%13)
Cryptogenic	23 (%11.5)
HCC	30 (%15)
Alcohol	4 (%2)
Others	14 (%7)

(Budd–Chiari, alveolar cyst hydatic, haemochromatosis, fulminant hepatitis, a neuroendocrine tumour, Wilson's disease)

BMI, body mass index; HCC, hepatocellular carcinoma; PBS, primary biliary cirrhosis; PSC, primary sclerosing cholangitis.

In 111 patients in whom a single duct was identified and 1DD anastomosis was performed, 16 (14.4%) developed bile leakages and 9 (8.1%) developed biliary strictures. Among this group of patients, five (4.5%) were re-operated for bile leakages and four (3.6%) for biliary strictures. Of the 45 patients with double ducts in their grafts and with 1DD anastomosis after back table plasty, 12 (26.6%) developed bile leakages and four (8.8%) developed biliary strictures. In this group, four (8.8%) patients were re-operated for bile leakages and one (2.2%) for biliary stricture. Of the 18 patients who had double ducts in their grafts and underwent 2DD anastomosis, four (22.2%) had bile leakages and one (5.5%) developed a biliary stricture. In this group, one patient was re-operated because of a bile leakage. In nine patients who had double ducts in their grafts and who had 1DD performed without the need for plasty, two (22.2%) developed bile leakages and two (22.2%) had biliary strictures. None of the patients in this group required a re-operation. Of the six patients who had three bile ducts, two out of the three patients who had undergone 2DD experienced bile leakages whereas one patient developed biliary stricture.

Of the 12 patients who underwent Roux-en-Y anastomosis, four (30%) had bile leakage and one patient required re-operation for this.

Of the 40 patients placed with external stents to the anastomosis, 12 developed bile leakage (30%) and one developed a biliary stricture. Stenting did not decrease biliary complications.

© 2011 International Hepato-Pancreato-Biliary Association

Table 2 Type of biliary reconstructions and outcomes

Number of biliary orifice	Type of anastomosis	Number of patients	Number (%) of biliary leaks	Number (%) of biliary strictures	Number (%) of re-operations for biliary leak	Number (%) of re-operation- for biliary stricture
1	1DD	111	16 (14.4)	9 (8.1)	5 (4.5)	4 (3.6)
1	Roux-en-Y	6	2 (33.3%)	0	1 (16.6)	0
2	1DD (with back-wall plasty)	45	12 (26.6)	4 (8.8)	4 (8.8)	1 (2.2)
2	1DD (without plasty)	9	2 (22.2)	2 (22.2)	0	0
2	2DD	18	4 (22.2)	1 (5.5)	1 (5.5)	0
2	Roux-en-Y	5	2 (40%)	0	0	0
3	1DD	1	0	1 (100)	0	0
3	2DD	3	2 (66.6)	0	1 (33.3)	0
3	3DD (one anastomosis to cystic duct)	1	0	0	0	0
3	Roux-en-Y	1	0	0	0	0

DD, duct to duct.

For the treatment of 17 biliary strictures, 13 patients underwent endoscopic retrograde cholangiography (ERCP). In seven of these 13 procedures, the complication resolved. Five patients underwent percutaneous transhepatic cholangiography (PTC). Success was achieved in four patients and there was one failure. Five patients were re-operated. Of the 40 bile leakages, 12 stopped spontaneously and nine were percutaneously drained under the guidance of USG. Seven ERCPs were performed, of which five were successful. Twelve patients had to be re-operated. Of these patients, DD anastomosis was converted to Roux-en-Y bilioenteric anastomosis in 11 patients. In the remaining one patient, as the previous operation was Roux-en-Y anastomosis, revision and drainage were performed.

Of the 49 patients experiencing biliary complications, 12 patients died during the course of the follow-up and 37 patients survived. Of the 12 patients who died, four had been re-operated as a result of bile leakage, yet these patients had developed sepsis and multiorgan failure and had died. In the remaining eight patients, the cause of mortality was sepsis which developed secondary to prolonged biliary cholestatic problems in four patients. Four other patients died as a consequence of other causes (two tumour recurrences, one acute liver failure and one intra-abdominal bleeding).

There was no mortality or life-threatening complication in the donors. No donor developed hepatic failure or hepatic failure signs. The most common complication was wound infection, which was seen in 20 (10%) donors. Because of prolonged nausea, nine donors (4.5%) received total parenteral nutrition. Eight donors (4%) developed abdominal collections and four of these underwent percutaneous drainage.

Fourteen donors (7%) developed biliary complications (12 leaks and two strictures). One biliary leak and one biliary stricture required re-operation. One donor was re-operated because of a post-operative haemorrhage. The incidence of re-operation was 1.5% in all donors.

Discussion

Liver transplantation is the only curative treatment for end-stage liver disease and its complications in selected patients. However, in countries with a limited supply of grafts from cadavers, it is necessary to perform transplants from living donors. Right lobe living donor liver transplantations is superior than left lobe living donor liver transplantations as it allows for the solution of problems such as the small-for-size syndrome. However, biliary variations with an incidence of up to 50% in right lobe grafts pose the risk of biliary complications.[1–6]

The rate of biliary complications after a cadaveric transplant is 5–15%, but increases to 38% with transplants from living donors.[5,6] Predisposing factors have been listed as the ischaemia encountered in the donor bile ducts at the time of dissection and transection, the right hepatic artery not being dominant in the blood supply, thrombosis of hepatic artery, CMV infections, ABO incompatible transplants, not performing 'tension-free' anastomosis, the presence of a bile duct orifice of smaller than 4 mm and the presence of more than a single duct within the graft.

When DD anastomosis was compared with Roux-en-Y anastomosis after a right lobe transplantation, the DD anastomosis bile leakage rate was 31.7% and the biliary stricture rate was 16.3%; these rates were 7.3% and 18.2% after Roux-en-Y anastomosis, respectively.[7] In the present study, the rate of overall biliary complications was 28.5%, the rate of biliary stricture was 8.5% and biliary leakage was 20%.

Duct-to-duct anastomoses seems to be more advantageous, as they do not damage the physiology of the biliary tracts, do not cause an ascending infection, can be performed faster and they allow for subsequent ERCP. If DD anastomoses are to be performed, the important points to decrease the risk of complication are not to excessively dissect the recipient or donor bile ducts, to make clean transections, not to have discrepancies between the duct diameter and not to perform too tense an anastomoses.

© 2011 International Hepato-Pancreato-Biliary Association

Furthermore, it is important not to hamper the microcirculation around the duct and or to cause problems in hepatic artery anastomosis. Concerning the technique to be employed and the suture material to be used, each centre has its own protocols. Azoulay *et al*. reported non-absorbable suture materials as being superior, as they prevent inflammation and fibrosis that might occur during absorption.[8] In our centre, we used non-absorbable 6/0 polypropylene sutures, with the interrupted suture techniques for our anastomoses.

The topic of placing biliary stents after anastomosis is controversial with initial series reporting apparent reduction in biliary complications, whereas recent publications report stent procedures causing foreign body reactions and fibrosis, thereby leading to 26.6% biliary complication rates in such patients.[2,9,10] In the present group of patients in whom stents were placed, the bile leakage rate was 30% and it was concluded that the use of external biliary stents did not provide any benefit.

As can be seen in our results, the lowest number of complications where present in single duct DD anastomosis patients (14.4% bile leakage and 8.1% biliary strictures); in patients with more than one bile duct, whether it be with or without plasty, bile leakage rates were found to be more than 20%.

In grafts containing double bile duct grafts, if the distance between the ducts is more than 3 mm, the 'ductoplasty' performed to convert the ducts to a single one and to unify the orifices is not recommended. It is said that the septotomy and the plasty performed at this instance results in ischaemia and fibrosis, thus the use of the Roux-en-Y technique is recommended in such patients.[9,11] In spite of the fact that bile leakage was observed at a rate of 30% in the Roux-en-Y anastomosis portion of our series, only one patient developed biliary stricture.

Re-operation, ERCP, PTC and percutaneous biliary drainage are the most commonly used methods in the treatment of biliary complications. The success rate of ERCP in the treatment of biliary strictures is reported to be 75%.[12] The length of the segment harbouring the stenosis and performing a single or dual duct anastomosis influence the success of ERCP. For short strictures and single duct anastomoses, a few sessions of dilatation and the placement of internal stents are reported to increase the success rates. In patients in whom ERCP cannot bring about success, an external stent placement with PTC has been reported to yield successful results if these patients have dilated intrahepatic bile ducts.[13,14] In the present study, ERCP was successful in six out of 13 patients with biliary strictures and five out of seven patients with a biliary leakage. Furthermore, PTC was successful in four out of five patients with biliary strictures.

In conclusion, biliary complications experienced after liver transplantations from living donors continue to cause problems worldwide. The lowest number of complications developed in patients having one bile duct in their grafts and in those having a single DD anastomosis. Identification of more than one biliary orifice in the graft resulted in an increase in the complication rates. In patients who were identified to have double or triple ducts in the graft, provided that the ducts are not within the common bile sheath, these should either be anastomozed separately or a Roux-en-Y anastomosis should be performed during the first operation.

Contributions

O.Y. proposed the study. O.Y. and M.A. wrote the manuscript. N.G., T.D., M.D. collected the data. N.B., E.A., F.B., Y.Y. and Y.T. analyzed the data. All authors contributed to the design and interpretation of the study and to further drafts.

Conflicts of interest

No benefits in any form have been received or will be received from a commercial party related directly or indirectly to the subject of this article.

References

1. Qian YB, Liu CL, Lo CM, Fan ST. (2004) Risk factors for biliary reconstructions after liver transplantation. *Arch Surg* 139:1101–1105.
2. Nakamura T, Tanaka K, Kiuchi T, Kasahara M, Oike F, Ueda M *et al*. (2002) Anatomical variations and surgical strategies in right lobe living donor liver transplantation: lessons from 120 cases. *Transplantation* 73:1896 –1903.
3. Grewal HP, Shokouh-Amiri MH, Vera S, Stratta R, Bagous W, Gaber AO. (2001) Surgical technique for right lobe adult living donor liver transplantation without venovenous bypass or portocaval shunting and with duct-to-duct biliary reconstruction. *Ann Surg* 233:502–508.
4. Lo CM, Fan ST, Liu CL, Lo RJ, Lau GK, Wei WI *et al*. (1997) Extending the limit on the size of adult recipient in living donor liver transplantation using extended right lobe graft. *Transplantation* 63:1524–1528.
5. Colonna JO. (1996) Technical problems: biliary. In: Busuttil RW, Klintmalm GB, eds. *Transplant of the Liver*. Philadelphia, PA: Saunders, pp. 17–625.
6. Heffron TG, Emond JC, Whitington PF, Thistlethwaite JR Jr, Stevens L, Piper J *et al*. (1992) Biliary complications in pediatric liver transplantation: a comparison of reduced-size and whole grafts. *Transplantation* 53:391–395.
7. Gondolesi GE, Varotti G, Florman SS, Muñoz L, Fishbein TM, Emre SH *et al*. (2004) Biliary complications in 96 consecutive right lobe living donor transplant recipients. *Transplantation* 77:1842–1848.
8. Azoulay D, Hargreaves GM, Castaing D, RenéAdam, Bismuth H. (2001) Duct-to-duct biliary anastomosis in living related liver transplantation: the Paul Brousse Technique. *Arch Surg* 136:1197–1200.
9. Chan SC, Fan ST. (2008) Biliary complications in liver transplantation. *Hepatol Int* 2:399–404.
10. Kasahara M, Egawa H, Takada Y, Oike F, Sakamoto S, Kiuchi T *et al*. (2006) Biliary reconstruction in right lobe living-donor liver transplantation comparison of different techniques in 321 recipients. *Ann Surg* 243:559–566.
11. Hwang S, Lee SG, Sung KB, Park KM, Kim KH, Ahn CS *et al*. (2006) Long-term incidence, risk factors, and management of biliary complications after adult living donor liver transplantation. *Liver Transpl* 12:831–838.
12. Shah JN, Ahmad NA, Shetty K, Kochman ML, Long WB, Brensinger CM *et al*. (2004) Endoscopic management of biliary complications after adult living donor liver transplantation. *Am J Gastroenterol* 99:1291–1295.
13. Egawa H, Inomata Y, Uemoto S, Asonuma K, Kiuchi T, Fujita S *et al*. (2001) Biliary anastomotic complications in 400 living related liver transplantations. *World J Surg* 25:1300–1307.
14. Cheng YF, Chen CL, Chen YS, Huang TL, Chen TY, Lee TY *et al*. (2000) Interventional radiology in the treatment of post-liver transplant complications. *Transplant Proc* 32:2196–2197.

© 2011 International Hepato-Pancreato-Biliary Association