Brain & Development 41 (2019) 389–391

BRAIN & DEVELOPMENT
Official Journal of the Japanese Society of Child Neurology

www.elsevier.com/locate/braindev

Case Report

Ketogenic diet as a successful early treatment modality for SCN2A mutation

Dilsad Turkdogan [a], Gulten Thomas [a,*], Birsen Demirel [b]

[a] Division of Child Neurology, Department of Pediatrics, Marmara University, Faculty of Medicine, Turkey
[b] Department of Nutrition and Dietetics, Bilgi University School of Medicine, Turkey

Received 24 July 2018; received in revised form 28 September 2018; accepted 29 October 2018

Abstract

SCN2A mutations have been described in a very broad spectrum of clinical phenotypes including benign (familial) neonatal/infantile seizures and early infantile epileptic encephalopathies (EIEE) as Ohtahara syndrome (OS), Dravet syndrome (DS), epilepsy of infancy with migrating focal seizures and West syndrome (WS). Treatment modalities for epilepsy caused by SCN2A mutations mainly consist of sodium channel blockers but ketogenic diet (KD) is also considered as an option of treatment for intractible seizures caused by SCN2A mutations. Because of the wide nature of the heterogeneity of mutations related to SCN2A gene, the clinical phenotypes vary in severity and treatment response to KD has been reported to be controversial.

We present a patient diagnosed with OS associated with a **novel** SCN2A mutation (**c.408G > A, p.Met136Ile; OMIM®: 182390**) who had a complete resolution of seizures and EEG abnormalities with KD commenced at 39 days of age.

As far as we are aware our case is the youngest patient with SCN2A mutation treated with KD with complete resolution of epilepsy at an early age and has been seizure free of antiepileptic medications for a long duration.
© 2018 The Japanese Society of Child Neurology. Published by Elsevier B.V. All rights reserved.

Keywords: SCN2A mutation; Intractible seizures; Ketogenic diet

1. Introduction

SCN2A mutations have been described in a very broad spectrum of clinical phenotypes including benign (familial) neonatal/infantile seizures and early infantile epileptic encephalopathies (EIEE) as Ohtahara syndrome (OS), Dravet syndrome (DS), epilepsy of infancy with migrating focal seizures and West syndrome (WS) [1]. SCN2A mutations mainly affect the early developmental period and are generally accompanied by seizures although patients with SCN2A mutations have been reported to only have autism with no seizures [2,3]. The reason for the broad spectrum of clinical phenotypes is still unknown.

Treatment modalities for epilepsy caused by SCN2A mutations mainly consist of sodium channel blockers including phenytoin, carbamazepine, oxcarbazepine, lacosamide, lamotrigine and zonisamide especially at the first months of age [4]. Ketogenic diet (KD) has been used as a treatment modality for DS caused by genetic defects in the SCN1A, SCN2A, SCN9A and GABRG2 genes and has been reported to be effective to decrease seizures and have positive effect on hyperactivity, inattention, impulsivity and aggression [5].

* Corresponding author at: Division of Child Neurology, Department of Pediatrics, Marmara University, Faculty of Medicine, Fevzi Çakmak mah, Muhsin Yazıcıoglu cad, No: 10 Pendik, İstanbul, Turkey.
E-mail address: gulten@thomas.md (G. Thomas).

https://doi.org/10.1016/j.braindev.2018.10.015
0387-7604/© 2018 The Japanese Society of Child Neurology. Published by Elsevier B.V. All rights reserved.

Herein, we present a patient diagnosed with OS associated with a novel SCN2A mutation who had a complete resolution of seizures and EEG abnormalities with KD commenced at 39 days of age.

2. Case presentation

A 30 day old female patient was referred to our clinic with numerous daily focal and generalized tonic convulsions which started on the 3rd postnatal day. Her convulsions were refractory to antiepileptic medications used at optimal dosages, which were pyridoxine, phenobarbital, vigabatrine and clobazame respectively. The number and severity of her seizures increased with age. EEG at the age of 5 days, demonstrated burst suppression pattern. She had severe axial hypotonia and lack of eye contact. Her cranial MRI was normal. Metabolic work up was inconclusive except low CSF/plasma glucose ratio (0.36).

KD with a 3:1 ratio of fats vs protein and carbohydrate was started at 39 days of age with a preliminary diagnosis of glucose transporter deficiency-1 deficiency. She tested negative for SLC2A1 mutations. Whole exome sequencing demonstrated **de novo** heterozygous mutation (**c.408G > A, p.Met136Ile**) of SCN2A gene (**OMIM®: 182390**).

On 7th day of her diet her convulsions decreased in number and severity. All seizures ceased after 1 month of KD and EEG showed only focal spikes at the 3rd month. Antiepileptic medications were decreased 3 months after the diet was started. The seizures recurred at 6 months of age after routine vaccination which stopped spontaneously in a few weeks. At 11th month of the KD, video-EEG monitorization was completely normal (Fig. 1). All antiepileptic drugs were stopped at 1st year of KD. At 2.5 years of age she was still seizure-free with normal EEG, but developmental milestones were severely retarded, she had minimal eye contact with mild head control.

3. Discussion

Ketogenic diet has been used since 1920s to decrease seizure frequency from the observation that starvation improved epilepsy. Nowadays it is mainly used as a treatment of choice for intractable epilepsy unresponsive to antiepileptics. Further studies are continuing to evaluate the effects of KD on other neurological and psychological diseases [5].

Patients with EIEE – a group of epilepsies which have intractable multiple seizures resistant to antiepileptic medications, are good candidates for treatment with KD. While there is a great amount of evidence for the use of KD in EIEE such as DS, myoclonic atonic epilepsy, WS and in refractory/super refractory status epilepticus [5,6]. There are controversial results about its effects on seizure frequency because of the limitations of the studies and lack of open labeled prospective studies.

Considering side effects, cost effectiveness and difficulty in sustaining the diet, researches have been concentrated on studying the efficacy of KD on specific gene mutations responsible for epileptic encephalopathy syndromes. Ko et al. [7] found that KD was effective in patients with SCN1A, KCNQ2, STXBP1, and SCN2A mutations, but less effective in patients with CDKL5 mutations.

SCN2A mutations have recently been described as being responsible for a broad spectrum of clinical phenotypes [1,2]. Because of the wide nature of the heterogeneity of mutations related to SCN2A gene, the clinical phenotypes vary in severity and treatment response. Wolff et al. [4] published the nature of heterogeneity in SCN2A related mutations of 71 previously unreported patients and reviewed 130 previously reported patients. They reported the retrospective treatment results of 66 well documented patients where KD was tried and found ineffective in 13 patients [4]. A case with de novo mutation of SCN2A with WS was unresponsive to KD [8]. These studies have not reported the age of patients when KD was started.

Su et al. [9] introduced KD at 8 months of age in a patient with WS. The seizures stopped in the following 10 months and prominent EEG resolution was achieved. The modified Atkins diet was successful in a 4 year old patient with WS associated with SCN2A mutation [10]. In our case, comparably, the early resolution of encephalopathic features in favor of both seizures and EEG findings suggests that KD is a favorable therapeutic option for EIEE related with SCN2A mutations, especially if started at an early age.

Sodium channel blockers have been proven to have positive effects on seizures in SCN2A mutations and patients who respond to ketogenic diet might also benefit from the positive effects of these antiepileptics in addition to ketogenic diet. In our patient, we had not used sodium channel blockers because KD was started with a preliminary diagnosis of GLUT-1 deficiency and when the genetic test resulted, the patient's seizures had already stopped.

As far as we are aware our case is the youngest patient with SCN2A mutation treated with KD with complete resolution of epilepsy at an early age and has been seizure free of antiepileptic medications for a long duration.

4. Ethics

We had the informed consent from the parents of the patient for publication.

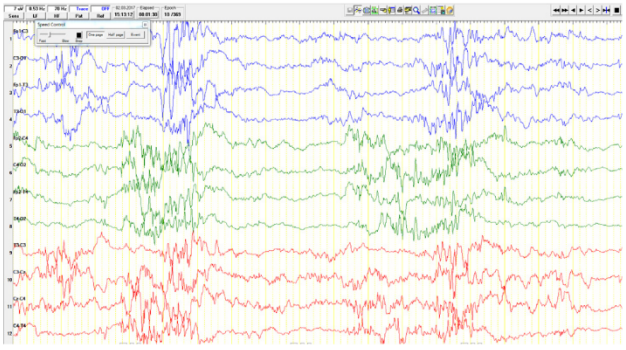

A) Electroencephalogram of the patient when 5 days old showing burst suppression



B) Electroencephalogram of the patient at 1st month of ketogenic diet showing multifocal spikes.



C) Electroenecephalogram of the patient at 11th month of the diet with normal background including sleep spindles.

Fig. 1. Electroencephalogram of the patient at three different stages of the treatment. A) Electroencephalogram of the patient when 5 days old showing burst suppression. B) Electroencephalogram of the patient at 1st month of ketogenic diet showing multifocal spikes. C) Electroenecephalogram of the patient at 11th month of the diet with normal background including sleep spindles.

References

[1] Howell KB, McMahon JM, Carvill GL, Tambunan D, Mackay MT, Rodriguez-Casero V, et al. *SCN2A* encephalopathy. Neurology 2015;85:958–66.

[2] Sanders SJ, Murtha MT, Gupta AR, Murdoch JD, Raubeson MJ, Willsey AJ, et al. De novo mutations revealed by whole-exome sequencing are strongly associated with autism. Nature 2012;485:237–41.

[3] Catterall WA. Sodium channels, inherited epilepsy, and antiepileptic drugs. Annu Rev Pharmacol Toxicol 2014;54:317–38.

[4] Wolff M, Johannesen KM, Hedrich UBS, Masnada S, Rubboli G, Gardella E, et al. Genetic and phenotypic heterogeneity suggest therapeutic implications in SCN2A-related disorders. Brain 2017;140:1316–36.

[5] Lee M. The use of ketogenic diet in special situations: expanding use in intractable epilepsy and other neurologic disorders. Korean J Pediatr 2012;55:316–21.

[6] Smith G, Craig A. Press ketogenic diet in super-refractory status epilepticus. Pediatr Neurol Briefs 2017;31:8.

[7] Ko Ara. The efficacy of ketogenic diet for specific genetic mutation in developmental and epileptic encephalopathy. Front Neurol 2018;9:530.

[8] Samanta D, Ramakrishnaiah R. De novo R853Q mutation of SCN2A gene and West syndrome. Acta Neurol Belg 2015;115:773–6.

[9] Su DJ, Lu JF, Lin LJ, Liang JS, Hung KL. SCN2A mutation in an infant presenting with migrating focal seizures and infantile spasm responsive to a ketogenic diet. Brain Dev 2018;40:724–7.

[10] Wong VC, Fung CW, Kwong AK. SCN2A mutation in a Chinese boy with infantile spasm – response to modified atkins diet. Brain Dev 2015;37:729–32.