ORIGINAL RESEARCH PAPER

Volume-7 | Issue-4 | April-2018 | ISSN No 2277 - 8179 | IF : 4.758 | IC Value : 93.98

INTERNATIONAL JOURNAL OF SCIENTIFIC RESEARCH

VOLUMETRIC TISSUE LOSS OF CARIOUS TEETH SCORED WITH ICDAS II

Medical Science

Yanikoglu F

Korkut B* *Corresponding Author

Celik ZC

Cetinbay C

Erkan K

Kocaman A

Tagtekin D

ABSTRACT

Aim: The International Caries Detection and Assessment System (ICDAS II) is a clinical scoring method which defines the stage of caries lesions. ICDAS 3,4 and 5 are the scores of teeth which needs to be restored mostly by direct approach. This study aimed to determine the relationship between ICDAS II scores and volumetric tissue loss of teeth after cavities prepared by minimally invasive principle.

Materials and Methods: Total of 42 extracted premolar teeth with ICDAS 3(n=11), ICDAS 4(n=14), ICDAS 5(n=17) were included to study. Digital photographs and radiographic images were taken. Single experienced examiner has diagnosed all teeth in day light, with naked eye by using all diagnostic records. Cavities were prepared with minimally invasive principle, and coronal build-ups were scanned by CAD/CAM. The volumes of these 3D images were calculated in Meshmixer 3.3. Data analyzed by using Regression & Correlation Analyses.

Results: The mean volume losses were found as following: ICDAS 3= 12,3%; ICDAS 4= 14%; ICDAS 5= 30,4%. There was a significant positive relationship between ICDAS scores and the volumetric tissue loss of teeth ($r(40)=.68$, $p<.0001$). Least standart deviation (LSD) was detected in ICDAS 4 teeth by SD=0,034 which is important in terms of indicating similar cavity dimensions after preparation.

Conclusion: Caries assessments considered according to ICDAS II scores were proportional to volumetic dental tissue losses. Our results can contribute the high performance of ICDAS II in terms of treatment decision and CAD/CAM and Meshmixer software for volumetric analysis being useful method under the conditions of this study.

KEYWORDS

Cavity, volume, ICDAS II, minimally invasive preparation, CAD-CAM.

Introduction

The earliest stage of a caries may start at 50 to 100 microns by subsurface demineralization and continue since the conditions proceed in favor of occurence of caries.[1] Even though, remineralization is possible since surface of the lesion is intact, there is considerable amount of structural changes affecting light reflections and crystal orientation in tissue.[2] When the conditions favoring the demineralization caries progress, the outer surface of an enamel lesion may be cavitated either by an explorer or lost under chewing function because of the underlined decomposed structure. Since a lesion is not intact anymore it has to be restored to save tissue integrity and provide the teeth in routine functioning. Nevertheless, in literature there is no definitive result about how much tissue lost from initial to extensive caries lesions in volume. Some detection methods may report the dimensions of a lesion by changes in fluorescence. However, there is no exact method reporting us how much tissue lost in different stages of a caries lesion. A caries detection system based on visual inspection, was developed to detect cavitated and non-cavitated stage lesions with acceptable reliability, 'The International Caries Detection and Assessment System ICDAS II[3,4]. The detection codes differ from 0 to 6 depending on the severity of caries lesion. Scores numbered 3, 4 and 5 are the ones in need of restoration mostly by direct approach (Table 1).

Table 1: ICDAS II scores [5]

ICDAS II Scores
0 - Sound surface
1 - Visual change in enamel (seen after prolonged air drying) or restricted within pit or fissure
2 - Distinct visual change in enamel
3 - Localized enamel break down (without clincal signs of dentin involvement)
4 - Underlying dark shadow from dentin
5 - Distinct cavity with visible dentin
6 - Extensive distinct cavity with visible dentin

By ICDAS II Scoring system as universal language among the collegues, clinicians may clearly be understood about the stage of caries. Following this identification very critical question arises: Are the remaining dental tissues strong enough to support the restoration already or should the clinician remove some of the sound tissues to get a better support? The problem may also be related to incomplete understanding of the clinician about caries process and its management.

Clinicians are getting confused with the increasing number of newly developed materials and methods when considering a treatment planing.[6] There is no black and white guide for treatment planning and grey areas always exist.[7] All restorative procedures must be carried out in conjunction with well-understood preventive techniques and patient education.[8]

The clinical decision in proper selection of restoration is related to many factors such as; lesion aetiology, lesion/cavity size, aesthetic, inter-occlusal, endodontic and periodontal considerations, patient's systemic condition, diet, parafunctions, restorative material and operative technique.[6,7,9-14] Low cost and less need for removal of sound dental tissues compared to the indirect restorations are the main advantages for the direct resin restorations.[9,15] However the longevity of these restorations is also a controversial topic.

The hypothesis of the study was “loss of intactness due to caries costs high tissue loss.” In this pilot study the aim was to determine how much tissue lost after removal of carious parts evaluating by a computer software program, meshmixer. Therefore, the correlation between ICDAS scores and volumetric tissue loss in posterior teeth with caries was evaluated.

Materials and Methods

Freshly extracted 45 maxillary right or left, first or second premolars with caries, were selected for the study. ICDAS II scoring system was used to standardize the lesions used in this study. The decayed teeth

were not selected according to the ICDAS scores initially but scored after random selection. Total of 45 extracted maxillary premolars with ICDAS 2 (n=2), ICDAS 3 (n=11), ICDAS 4 (n=14), ICDAS 5 (n=17), ICDAS 6 (n=2), were included to study. All teeth were cleaned from periodontal tissues and kept in 0.1% thymol solution during the study. Initial occlusal photopraphs were taken from all the teeth by using a professional modified macro dental camera (D700 body, 100 mm macro L objective and MR-14 EX II macro flash, Canon, Japan) at the department of Restorative Dentistry of Marmara University.

The decayed areas on each tooth were filled with laboratory wax in harmony with the remaining occlusal surface by single operator. The crowns of teeth with completed occlusal surfaces were scanned by a CAD/CAM device (Cerec Omnicam, Dentsply-Sirona) in Sirona Laboraties in Istanbul . The 3D image files of initial scan were exported from Cerec's software (SW 4.4.4) in 'cdt' extension format. Then each decayed tooth was prepared, in terms of minimal invasiveness, by an experienced single operator. Enamel preparations were done by using a high speed handpiece and green-banded, round, diamond burs under 2.5X magnification and 5500 kelvin head-light. (2.5X Eye Mag Loupe, Zeiss, Germany). Dentin preparations were done by using a low speed handpiece and tungsten-carbide, round burs under 2.5X magnification and 5500 kelvin head-light. Only the infected tissues were removed under caries indicator (Sable Seek, Ultradent) as control. A sharp Explorer was used to check softness of the remaining tissue, hard tissues even with discoloration are left in the cavity. The crowns of teeth with cavities in various dimensions were scanned by using the same CAD/CAM device. The 3D image files of the final scans were exported from the software in 'cdt' extension format.

The volumetric calculations of the initial and final 3D images were determined in another software, Meshmixer 3.3 (Autodesk, USA). Then the volumetric percentage differences between initial and final results of each tooth were calculated and saved. The collected data was analyzed by using Regression & Correlation Analysis.

Results

Initial volumes, final volumes, absolute volume loss and percentage volume loss of the teeth were scored with ICDAS II and cavities were created by minimally invasive preparation methods, are shown in Table 2. The mean volume loss of the groups were found as following: ICDAS 2: 5,5% ; ICDAS 3: 12% ; ICDAS 4: 14%; ICDAS 5: 30% ; ICDAS 6: 66% (Table 2). According to that there was a significant positive difference between ICDAS scores and the volumetric tissue loss of teeth ($r(40)=0.68$; $p<.0001$).

The mean standard deviation (*m*SD) values of the cavities which report the compatibility among the preparations of ICDAS 3, ICDAS 4, ICDAS 5 cavities were found as follows: SD=0,042, SD=0,034, SD=0,115. The lowest standard deviation in this study was found in ICDAS 4 cavities which is important in terms of indicating similar cavity dimensions after preparation. The highest standard deviation of cavity dimensions was found in ICDAS 5 cavities. Due to inadequacy of sample size of ICDAS 2 (n=2) and ICDAS 6 (n=2), the mean standard deviation value has not been calculated for these groups.

ICDAS CATEGORY	INITIAL VOLUME(mm^3)	FINAL VOLUME (mm^3)	VOLUME LOSS (mm^3)	VOLUME LOSS (%)
ICDAS 2	327,1	306,7	20,4	6
ICDAS 3	352,3	310,8	41,5	12
ICDAS 4	516,4	447,9	67,9	14
ICDAS 5	392,9	271,7	121,2	30
ICDAS 6	322,1	110,8	211,3	66

Table 2: Mean values of volumetric losses of teeth in different ICDAS categories (mm3 & percentage)

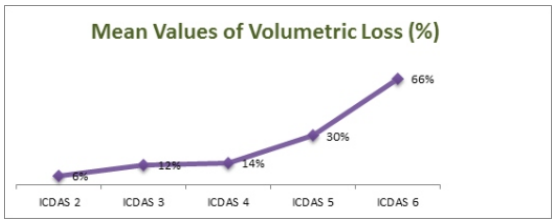

Figure 1: Mean values of volumetric (%) loss of teeth in different ICDAS scores

Discussion

Minimal invasive dentisty is the milestone of contemporary dentistry which focuses on the least invasive treatment option available to minimize tissue loss and patient discomfort. In fact, within minimum invasive dentistry concept, dentists should follow important steps: early diagnosis of caries lesions using adequate diagnostic devices, remineralization of the earliest lesions, minimum surgical intervention of cavitated lesion and selection of favorable restorative material[16]. Prior to these steps, clinicians must consider the caries risk of the patient in order to increase the success rate of the restorations.[8,17] The clinical decision regarding the most proper option of preparation and restoration is a very controversial subject and usually determined by a variety of factors such as; lesion aetiology, lesion/cavity size, aesthetic, inter-occlusal, endodontic and periodontal considerations, and also patient systemic condition, diet and parafunctions.[7,9-12] The clinical evaluation of restorations also involves the restorative material and several operative techniques.[6,11]

The width of the restoration material is reported as an important factor in survival rate of the restorations. At least 1mm thickness for composite resins, 2mm thickness for low-strength ceramics such as feldspathic and leucite reinforced ceramics and for lithium disilicate reinforced ceramics 1 - 1,2 mm thickness are recommended by the researchers.[10,18-22] However only some in vitro tests and a few short term clinical studies are available for commercially available composite resins which are limited in predicting the clinical success.[6,23] Long term clinical studies are needed to evaluate the realistic success of the restorative materials and to identify the modes and reasons of possible failures. The main reasons for failure are reported as, secondary caries, fracture, marginal deficiencies, wear and postoperative sensitivity.[11,13]

Even if the clinician knows about the caries risk of the patient, after the cavity preparation it is still not clear that which the type of the restoration must be selected, direct or indirect? Direct composite resins have become the first choice for posterior restorations and are increasingly popular among patients and clinicians.

The position of tooth also plays an important role in survival. Several studies have mentioned that restorations in premolars have shown better survival rates compared to the ones in molars.[6,9,12,24,25] The higher masticatory forces in posterior area can be the explanation for that result. However some studies oppose to that by indicating maxillary premolars as a more risky teeth due to anatomy of cusps.[17,26,27] The preservation of natural tooth structure must be the guiding factor for both the smallest and the largest cavities.

Cavity size and shape are reported to be related to the failure risk. Loss of dental tissue due to either caries lesion or cavity preparation reduces the fracture strength of the remaining dental structure.[28,29] In this study, findings showed the highest standard deviation of ICDAS 5 scored teeth. The reason of this may be due to various preparation approaches or over-preparations in some cases, for the future restoration so can be resistant enough for occlusal load.

Class II cavities and extensive cavities are considered as more likely to fail than Class I cavities and minimally invasive cavities.[6,9,30-32]

According to that, we suggest ICDAS 4 scored teeth which are mostly dentin caries with intact enamel, to be evaluated in terms of occlusal/easy accesible and slot preparations. In proximal areas it is important to preserve as much enamel structure as possible for impeding tissue loss. Opdam et al., reported that every additional restoration surface resulted in an increased risk of failure 40%.[33] Mondelli et al., demonstrated that cavities with wider bucco-lingual dimensions have lower fracture strength than sound teeth, either restored or not.[34] While cusp flexibility and deflection are influenced by the depth of the cavity, the fracture strength was also influenced by the preparation depth as Blaser et al., contributed.[35] Nagasiri and Chitmongkolsuk reported a high rate of failure 12.4% of composite restorations on endodontically treated teeth and connected that to the remaining coronal tooth structure.[36] In a five year clinical study Coppola et al. reported 42 months average survival of posterior restorations with at least two surfaces. This result was told to be related to the operator's experience.[37]

Several studies have shown that the removal of sound tooth structure during cavity preparation decreases the strength of tooth as the width and depth of cavity increases.[17,26,38-40] Our study has revealed that the

average cavity sizes of teeth indicated as ICDAS 3 and ICDAS 4 were quite similar (12% and 14%). However, ICDAS 3 is identified as an stage of caries limited to enamel with surface discontinuity. Therefore the dimensions of the ICDAS 3 cavities were expected to be less. The focus should be on maximum conservation of demineralized, non-cavitated enamel and dentin in modern restorative dentistry procedures.[41] The traditional 'Black' cavity preparation approach is to start with enamel preparation followed by the removal of carious dentin. However the completeness of removal of carious dentin is still not clear in either clinical or scientific criteria.[5] Because it is a real problem to properly discriminate between infected, affected and sound or remineralizable dentin. Stained dentin is not always a clear sign for infection.[42,43] Moreover total removal of infected dentin is not always necessary for the success of the treatment.[5,17] Some researchers associated that with caries risk. Köhler et al., blamed caries risk as a factor associated with the failure rate 5.5% and Opdam et al. confirmed that result.[12,44] Trachtenberg et al., also supported that with clinical study in children, by revealing the higher DMFT index the higher risk of restoration failure.[45]

'Extension for prevention' has given way to the new concept of minimally invasive dentistry as it was described in 2000 by Tyas et al. The concept includes: early caries diagnosis; classification of caries depth and progression; assessment of caries risk; reduction of cariogenic bacteria to decrease the risk of demineralization; arresting of active lesions; remineralization and monitoring of non-cavitated lesions; placement of restorations in teeth with cavitated lesions using minimal cavity designs; repair rather than the replacement of defective restorations; assessing disease management outcomes at intervals.[46]

Murdoch-Kinch and Mclean[8] reported that cavity preparation is not indicated in lesions in inner one-half of enamel and even slightly into dentin. They explained it on the basis that cavity progression in enamel is very slow even if it is active and usually takes six to eight years to progress through the whole enamel.[8] Mount and Hume suggested to gain minimal access to the lesions and remove areas that are infected and broken down to the point where remineralization is no longer possible.[47]

Unlike direct techniques, indirect restorations such as inlays and onlays usually require more reduction of sound dental substance during preparation process.[17,48] Another inference of this study is that, volume loss of teeth indicated as ICDAS 5 were accurately separated from ICDAS 6. While the mean volume loss was $m = 30\%$, none has shown more than 50% loss whereby ICDAS 6 indicated extensive cavity within visible dentin where more than 50% was lost due to caries. The accuracy of the distinction is very important for the decision on direct or indirect treatment plan. Related with that, it is reported that the preparation of an indirect restoration requires greater tooth reduction due to general indications of ceramic inlay/onlay as 10 degree taper and 15 degree taper angles.[10] On the contrary if thin buccal, lingual or proximal walls of an extensive cavity exist after caries or former restoration removal, then indirect restoration was strongly indicated rather than direct filllings, as polymerization forces might deform the remaining tooth structures, potentially inducing cracks.[49-52]

Rocca et al., recommended a minimum of 1 mm as minimal wall thickness before supportive preparations. If it is below that, preparation for reducing the height of the cusp and then a restoration with cusp coverage is indicated. They claimed that guideline as an accepted general clinical consensus.[10] Rocca and Krejci reported that, the residual-wall-support context is related not only to the width of wall but also to the position of tooth, presence of parafunctions, and presence or absence of marginal ridges.[53] Although 1-2 mm minimal wall thickness is recommended, the systematic occlusal coverage of cusps is not yet advocated as it has not proven yet to increase the strength of the tooth-restoration system, for both composite resins[54] and ceramics.[5,55-57]

In this study, caries assessments considered according to ICDAS II system scores were found to be proportional to volumetric dental tissue losses. Even if we do not pay attention to the ICDAS 1 and ICDAS 6 group results due to having only two teeth in each, the results of all other groups indicated that, ICDAS II scoring is as effective as a quantitative 3D calculation method, under the conditions of this study. It is clear that only ICDAS scoring can provisionally indicate the possible volume loss of the crown after the cavity preparation.

On the other hand the CAD/CAM device used in this research, showed a high performance and accuracy in volumetric tissue analysis. According to the results of this study, CAD/CAM device was found to be a promising method and may contribute the decision of clinician during preparation phase and restoration phase. Volumetric analysis was seemed to be an auxiliary method to decide the type of the cavity and the restoration besides 2D evaluation methods like cavity wall thickness measurement. Meshmixer 3.3 (Autodesk, USA) software allows manipulation of triangulated data of point cloud representing geometrical model. Additionally it enables further calculations on given geometry. Scanning input datas were used for the evaluation.

However, the lost volume can be occurred in any part of dental crown. It is possible to get exacly the same volumetric loss rate while having 3 mm cavity wall thickness, but also while having less than 1 mm. As many researchers recommended about having at least 1-2mm cavity wall thickness before cuspal coverage[10,53], it may be more realistic to combine volumetric analysis with cavity wall thickness calculation for now. Also as each tooth has different size, shape and different caries lesions, it was impossible to standardize the cavity size, shape, depth and width in this study. So perhaps there could have been some unwilling errors during the comparison of volumetric calculations with ICDAS scores. The 3D volumetric cavity measurements, after a minimal invasive cavity preparation, can be a possible solution for residual-wall-support context.

The hypothesis of this study was approved by demonstrating the linear relation between degrees of caries and amount of tissue loss. According to that the next target will be creating a new, reliable, repeatable and quantitative cavity evaluation method to decide the most proper preparation and restoration type.

Conclusion

Our study showed that the ICDAS scores were significantly consistent with the dental volume loss of preparations with minimally invasive approach in teeth. The categories of ICDAS system were reliable and successfull in distinguishing the stages of caries, showing strong correlation with volumetric loss of the teeth. However, on the basis of our findings, we think that ICDAS 3 cavities should be prepared more conservatively, and that structures outside the active caries areas should not be included into cavity preparation. As the volumetric tissue loss increases exponentially, it is vital to take preventive precautions before irreversible damage occurs.

In literature there is still no research-based worldwide accepted evidence determining the type of restoration and preparation.[5,11] Clinicians should give much more importance to the early diagnosis of caries. Beyond anything, it is intended to save the teeth from restorative steps and to detect in early / white spot phase which lesions are still reversible. According to the results of this study, volumetric analysis with CAD/CAM and Meshmixer software are useful methods for the evaluation.

Intactness of a tooth should be preserved first and all prevention methods should be applied in clinics. Although ICDAS 3,4,5 and 6 coded cavities were minimally prepared, the lost amount were quite high as 30%, 66%. Our study underlines the importance of prevention and points ICDAS II evaluation with as valuable Meshmixer programme as a quantitive method for the cavity preparations. Further experimental studies are adviced to be used with this method.

Acknowlegements

We would like to thank to Cigdem Kumarki and Sirona Team for guidence to the CAD/CAM system.

REFERENCES

1. Sarma S, & Hegde MN, Sadananda V, Matthews B. Minimal Invasive Techniques in Caries Detection, Diagnosis and Mangagement -A Clinical Study. Global Journal of Medical Research: J Dentistry & Otolaryngology, 2016; 16(2): 17-21.
2. Featherstone, J. Dental caries: a dynamic disease process. Australian Dental Journal, 2008; 53: 286–291.
3. Braga MM, Oliveira LB, Bonini GAVC, Bönecker M, Mendes FM. Feasibility of the International Caries Detection and Assessment System (ICDAS-II) in epidemiological surveys and comparability with standard World Health Organization criteria. Caries Research, 2009; 43(4): 245-249.
4. Pitts N. 'ICDAS' – An international system for caries detection and assessment being developed to facilitate caries epidemiology, research and appropriate clinical management. Community Dent Health 2004; 21: 193–198.
5. Koch G. Pediatric dentistry: a clinical approach. John Wiley & Sons. Diagnosis and Management of Dental Caries, 2017; Chapter 12, p-131,138,140.
6. Demarco FF, Corrêa MB, Cenci MS, Moraes RR, Opdam NJ. Longevity of posterior composite restorations: not only a matter of materials. Dental Materials, 2012; 28(1):87-

101.
7. Smithson J, Newsome P, Reaney D, Owen S. Direct or indirect restorations? Int Dent-African Ed, 2011;1(1):70-80.
8. Murdoch-Kinch CA, McLean ME. Minimally invasive dentistry. The Journal of the American Dental Association, 2003;134(1):87-95.
9. Da Rosa Rodolpho PA, Donassollo TA, Cenci MS, Loguércio AD, Moraes RR, Bronkhorst EM, Demarco FF. 22-Year clinical evaluation of the performance of two posterior composites with different filler characteristics. Dental Materials, 2011;27(10):955-963.
10. Rocca GT, Rizcalla N, Krejci I, Dietschi D. Evidence-based concepts and procedures for bonded inlays and onlays. Part II. Guidelines for cavity preparation and restoration fabrication. Int J Esthet Dent, 2015;10(3):392-413.
11. Hickel R, Manhart J. Longevity of restorations in posterior teeth and reasons for failure. Journal of Adhesive Dentistry, 2001;3(1):45-65.
12. Opdam NJM, Bronkhorst EM, Loomans BAC, Huysmans MC. 12-year survival of composite vs. amalgam restorations. Journal of dental research, 2010;89(10):1063-1067.
13. Bernardo M, Luis H, Martin MD, Leroux BG, Rue T, Leitão J, DeRouen TA. Survival and reasons for failure of amalgam versus composite posterior restorations placed in a randomized clinical trial. The Journal of the American Dental Association, 2007;138(6):775-783.
14. Hickel R, Roulet JF, Bayne S, Heintze SD, Mjoer IA, Peters M, Vanherle G. Recommendations for conducting controlled clinical studies of dental restorative materials. Science Committee Project 2/98--FDI World Dental Federation study design (Part I) and criteria for evaluation (Part II) of direct and indirect restorations including onlays and partial crowns. The journal of adhesive dentistry, 2007;9:121-147.
15. Brunthaler A, König F, Lucas T, Sperr W, Schedle A. Longevity of direct resin composite restorations in posterior teeth: a review. Clinical oral investigations, 2003;7(2):63-70.
16. Kielbassa AM, Mueller J, Gernhardt CR. Closing the gap between oral hygiene and minimally invasive dentistry: A review on the resin infiltration technique of incipient (proximal) enamel lesions. Quintessence International, 2009; 40(8): 663-681.
17. Mondelli J, Sene F, Ramos RP, Benetti AR. Tooth Structure and Fracture Strength of Cavities. Braz Dent J, 2007;18(2):134-138.
18. Magne P, Schlichting LH, Maia HP, Baratieri LN. In vitro fatigue resistance of CAD/CAM composite resin and ceramic posterior occlusal veneers. J Prosthet Dent, 2010;104:149–157.
19. Schlichting LH, Maia HP, Baratieri LN, Magne P. Novel-design ultra-thin CAD/ CAM composite resin and ceramic occlusal veneers for the treatment of severe dental erosion. J Prosthet Dent 2011;105:217–226.
20. Skouridou N, Pollington S, Rosentritt M, Tsitrou E. Fracture strength of minimally prepared all-ceramic CEREC crowns after simulating 5 years of service. Dent Mater 2013;29:70–77.
21. Guess PC, Schultheis S, Wolkewitz M, Zhang Y, Strub JR. Influence of preparation design and ceramic thicknesses on fracture resistance and failure modes of premolar partial coverage restorations. J Prosthet Dent 2013;110:264–273.
22. . Clausen JO, Abou Tara M, Kern M. Dynamic fatigue and fracture resistance of non-retentive all-ceramic full-coverage molar restorations. Influence of ceramic material and preparation design. Dent Mater 2010;26:533–538.
23. Ernst CP, Martin M, Stuff S, Willershausen B. Clinical performance of a packable resin composite for posterior teeth after 3 years. Clinical oral investigations, 2001;5(3):148-155.
24. Pallesen U, Qvist V. Composite resin fillings and inlays. An 11-year evaluation. Clinical oral investigations, 2003;7(2):71-79.
25. Opdam NJ, Bronkhorst EM, Cenci MS, Huysmans MCD, Wilson NH. Age of failed restorations: a deceptive longevity parameter. Journal of dentistry, 2011;39(3): 225-230.
26. Jagadish S, Yogesh BG. Fracture resistance of teeth with Class 2 silver amalgam, posterior composite, and glass cermet restorations. Oper Dent 1990;15:42-47.
27. Millar BJ, Robinson PB, Davies BR. Effects of the removal of composite resin restorations on Class II cavities. British dental Journal 1992;173:210-212.
28. Hunter AR, Treasure ET, Hunter AJ. Increases in cavity volume associated with the removal of class 2 amalgam and composite restorations. Oper Dent 1995;20:2-6.
29. Mondelli RF, Barbosa WF, Mondelli J, Franco EB, Carvalho RM. Fracture strength of weakened human premolars restored with amalgam with and without cusp coverage. Amer J Dent, 1998;11:181-84.
30. Da Rosa Rodolpho PA, Cenci MS, Donassollo TA, Loguércio AD, Demarco FF. A clinical evaluation of posterior composite restorations: 17-year findings. Journal of dentistry, 2006;34(7):427-435.
31. Soncini JA, Maserejian NN, Trachtenberg F, Tavares M, Hayes C. The longevity of amalgam versus compomer/composite restorations in posterior primary and permanent teeth: findings From the New England Children's Amalgam Trial. The Journal of the American Dental Association, 2007;138(6):763-772.
32. Van Nieuwenhuysen JP, D'hoore W, Carvalho J, Qvist V. Long-term evaluation of extensive restorations in permanent teeth. Journal of dentistry, 2003;31(6):395-405.
33. Opdam NJ, Bronkhorst E.M, Roeters JM, Loomans BA. Longevity and reasons for failure of sandwich and total-etch posterior composite resin restorations. Journal of Adhesive Dentistry, 2007;9(5):469-475.
34. Mondelli J, Steagall L, Ishikiriama A, de Lima Navarro MF, Soares FB. Fracture strength of human teeth with cavity preparations. J Prosthet Dent 1980;43:419-422.
35. Blaser PK, Lund MR, Cochran MA, Potter RH. Effect of designs of Class 2 preparations on resistance of teeth to fracture. Oper Dent 1983;8:6-10.
36. Nagasiri R, Chitmongkolsuk S. Long-term survival of endodontically treated molars without crown coverage: a retrospective cohort study. The Journal of prosthetic dentistry, 2005;93(2):164-170.
37. Coppola MN, Ozcan YA, Bogacki R. Evaluation of performance of dental providers on posterior restorations: does experience matter? A data envelopment analysis (DEA) approach. Journal of Medical Systems, 2003;27(5):445-456.
38. Larson TD, Douglas WH, Geistfeld RE. Effect of prepared cavities on the strength of teeth. Oper Dent 1981;6:2-5.
39. Gelb MN, Barouch E, Simonsen RJ. Resistance to cusp fracture in class II prepared and restored premolars. J Prosthet Dent 1986;55:184-185.
40. Stampalia LL, Nicholls JI, Brudvik JS, Jones DW. Fracture resistance of teeth with resin-bonded restorations. J Prosthet Dent 1986;55:694-698.
41. Truman BI, Gooch BF, Sulemana I, Gift HC, Horowitz AM, Evans CA, Griffin SO, Carande-Kulis VG; The Task Force on Community Preventive Services. Reviews of evidence on interventions to prevent dental caries, oral and pharyngeal cancers, and sports-related craniofacial injuries. Am J Prev Med 2002;23(1):21-54.
42. Kidd EAM, Ricketts DNJ, Beighton D. Criteria for Caries Removal at the Enamel-Dentine Junction: a Clinical and Micro-biological Study. Br Dent J 1996;180:287-291.
43. Sabbagh J, McConnell RJ, McConnell MC. Posterior composites: Update on cavities and filling techniques. Journal of dentistry, 2017;57:86-90.
44. Köhler B, Rasmusson CG, Ödman P. A five-year clinical evaluation of Class II composite resin restorations. Journal of dentistry, 2000;28(2):111-116.
45. Trachtenberg F, Maserejian NN, Tavares M, Soncini JA, Hayes C. Extent of tooth decay in the mouth and increased need for replacement of dental restorations: the New England Children's Amalgam Trial. Pediatric dentistry, 2008;30(5):388-392.
46. Tyas MJ, Anusavice KJ, Frencken JE, Mount GJ. Minimal intervention dentistry: a review. FDI Commission Project 1-97. Int Dent J 2000;50(1):1-12.
47. Mount GJ, Hume WR. A revised classification of carious lesions by site and size. Quintessence Int 1997;28:301-303.
48. Roulet JF, Spreafico R. Esthetic posterior indirect restorations. Advances in Operative Dentistry: contemporary clinical practice. Berlin: Quintessence Publishing; 2001.
49. Versluis A, Tantbirojn D, Pintado MR, DeLong R, Douglas WH. Residual shrinkage stress distributions in molars after composite restoration. Dent Mater 2004;20:554–564.
50. Tantbirojn D, Versluis A, Pintado MR, DeLong R, Douglas WH. Tooth deforma- tion patterns in molars after composite restoration. Dent Mater 2004;20:535–542.
51. Bicalho AA, Pereira RD, Zanatta RF. Incremental layering technique and composite material-part I: Cuspal deformation, bond strength, and physical properties. Oper Dent 2014;39:71–82.
52. Bicalho AA, Valdívia AD, Barreto BC, Tantbirojn D, Versluis A, Soares CJ. Incremental layering technique and composite material-part II: Shrinkage and shrinkage stresses. Oper Dent 2014;39:83–92.
53. Rocca GT, Krejci I. Crown and post-free adhesive restorations for endodontically treated posterior teeth: from direct composite to endo- crowns. Eur J Esthet Dent 2013;8:156–179.
54. Fonseca RB, Fernandes-Neto AJ, Correr-Sobrinho L, Soares CJ. The influence of cavity preparation design on fracture strength and mode of fracture of laboratory-processed composite resin restorations. J Prosthet Dent 2007;98:277–284.
55. Federlin M, Sipos C, Hiller KA, Thonemann B, Schmalz G. Partial ceramic crowns. Influence of preparation design and luting material on margin integrity–A scanning electron microscopic study. Clin Oral Investig 2005;9:8–17.
56. Stappert CF, Guess PC, Gerds T, Strub JR. All ceramic partial coverage premolar restorations. Cavity preparation design, reliability and fracture resistance after fatigue. Am J Dent 2005;18:275–280.
57. Soares CJ, Martins LR, Fonseca RB, Correr-Sobrinho L, Fernandes Neto AJ. Influence of cavity preparation design on fracture resistance of posterior Leucite-reinforced ceramic restorations. J Prosthet Dent 2006;95:421–429.