Photobiomodulation, Photomedicine, and Laser Surgery
Volume XX, Number XX, 2020
© Mary Ann Liebert, Inc.
Pp. 1–8
DOI: 10.1089/photob.2019.4783

Original Research

Evaluation of Patient's Perceptions, Healing, and Reattachment After Conventional and Diode Laser Frenectomy: A Three-Arm Randomized Clinical Trial

Gamze Sezgin, DDS, PhD,[1] Hafize Ozturk Ozener, DDS, PhD,[1]
Suleyman Emre Meseli, DDS, PhD,[2] and Leyla Kuru, DDS, PhD[1]

Downloaded by UPPSALA UNIVERSITETSBIBLIOTEK from www.liebertpub.com at 07/01/20. For personal use only.

Abstract

Objective: The aim of this study is to compare the conventional and diode laser techniques in terms of patient's perceptions, epithelization, reattachment, and periodontal clinical parameters in the treatment of abnormal papillary frenum.

Materials and methods: Forty-eight patients with abnormal papillary frenum were enrolled in the study. Patients were randomly assigned into three groups; conventional frenectomy operation (C group), diode laser-assisted frenectomy (L group), and diode laser-assisted frenectomy with conventional horizontal incision on the periosteum (L + P group). Post-operative pain, discomfort in speaking, and chewing scores were assessed with visual analogue scale (VAS) at post-operative 3rd hour and on days 1, 7, 14, 21, and 45. Epithelialization process of the wound surface was evaluated by hydrogen peroxide solution applied to the wound on days 7, 14, 21, and 45 following operations. The distance between the frenum attachment point and mucogingival junction (FMGJ) was recorded at baseline, post-operative 45th day, and 6th month to assess the reattachment of the frenum. Plaque index, gingival index, bleeding on probing, and probing depth were recorded at baseline and post-operative 7th, 14th, 21st, and 45th days.

Results: On the 1st and 7th day after operation, VAS pain score in the C group was significantly higher than in the L and L + P groups ($p < 0.017$). Difficulty in speaking and chewing scores were significantly lower in the L and L + P groups compared to the C group at post-operative 3rd hour and 7th day ($p < 0.017$). The FMGJ and epithelization period demonstrated no difference among the groups at any time point ($p > 0.05$).

Conclusions: Our results suggest that diode laser provides better post-operative patient's perceptions than the conventional technique in frenectomy operation. In addition, both conventional and laser-assisted frenectomy surgeries prevent the frenum reattachment regardless of periosteal horizontal incision.

Keywords: labial frenum, lasers, laser therapy, visual analogue scale, post-operative pain

Introduction

Frenum, an anatomic structure formed by a fold of mucous membrane and connective tissue fibers, attaches the lip and cheeks to the alveolar mucosa, gingiva, and the underlying periosteum.[1] A frenum when closely attached to the gingival margin may cause some clinical problems, including insufficient plaque control by restriction of oral hygiene procedures and gingival sulcus exposure to the oral environment due to the mobility of gingival margin.[1,2] These conditions may accelerate progression of the periodontal disease, resulting in ongoing attachment loss and eventual bone loss.[3] Moreover, aberrant frenum attachment gives rise to prosthetic problems, since it interferes with the retention and/or stability of the denture, and causes irritation.[3–5]

Frenectomy is a surgical procedure in which the connection of the frenum and underlying bone is separated and completely removed.[6] Different frenectomy operations such

[1]Department of Periodontology, Faculty of Dentistry, Marmara University, Istanbul, Turkey.
[2]Department of Periodontology, Faculty of Dentistry, Istanbul Aydin University, Istanbul, Turkey.

Downloaded by UPPSALA UNIVERSITETSBIBLIOTEK from www.liebertpub.com at 07/01/20. For personal use only.

as conventional frenectomy, diamond technique (double hemostat technique), V-plasty technique (single hemostat technique), V-Y plasty technique, and submucosal frenectomy are performed using a scalpel.[6] In recent years, dental lasers have found a wide variety of applications in the field of dentistry, including periodontal surgery.

The photophysical properties of lasers allow them to possess strong ablation, hemostasis, detoxification, and bactericidal effects.[7] Studies have reported that the laser-assisted frenectomy provides the clotting of small blood vessels by hemostasis, resulting in a marked decrease in post-operative pain and bleeding.[8–11] Infection risk could also be reduced by simultaneous wound area sterilization.[12] Owing to the minimal damage to surrounding tissue, a reduction in wound contraction with less pain, edema, and minimal functional complications could be encountered in laser-assisted surgeries compared to conventional methods during the post-operative period.[3,13,14] Moreover, no requirement for sutures, shorter surgical operation time, and reduced patient anxiety could be listed as the other advantages of laser-assisted surgeries.[15,16]

Semiconductor diode lasers are often indicated for soft tissue surgeries since their wavelength (ranging from 800 to 980 nm) approximates to the absorption coefficient of pigmented tissues containing hemoglobin and melanin.[17] The diode laser has minimal thermal side effect on dental hard tissues and, therefore, it can be used safely for the incision and coagulation of oral mucosa and gingiva, pocket disinfection for bacterial elimination, sulcular curettage, and excision of periodontal cyst and pyogenic granuloma.[18–22]

Limited number of studies had reported the clinical healing after frenectomy operations with conventional technique and diode laser.[17,23–26] In the conventional frenectomy operation, a horizontal periosteal incision is routinely applied to prevent muscular reattachment of frenum to its original position.[27] However, this periosteal incision was not performed in the clinical studies evaluating healing following laser-assisted frenectomy operations[17,24–28]; thus, its role has not been clarified accurately. While the frenum reattachment after laser surgery was assessed only by Pie-Sanchez et al.,[3] epithelization and post-operative comfort of the patients were investigated in a few studies with short follow-up periods.[17,24] Thus, lack of data about clinical healing after frenectomy operations leads to need for further investigations.

Therefore, the aim of this clinical study was to evaluate patient's perceptions, including pain, and difficulty in speaking and chewing, epithelization, and reattachment following conventional and diode laser-assisted frenectomy operations performed on the subjects having abnormal papillary frenum attachment. The null hypothesis was that, there is no difference in the clinical outcome of patients following frenectomy operations performed by either conventional or diode laser-assisted techniques with/without periosteal incision.

Materials and Methods

This three-arm randomized prospective clinical trial was carried out in the Department of Periodontology, Faculty of Dentistry, Marmara University, Turkey, by the approval of Clinical Studies Ethical Committee of Yeditepe University. It was registered in clinicaltrials.gov with the number NCT03552809. The research was conducted according to the principles outlined in the Declaration of Helsinki on experimentation involving human subjects.

Study population and inclusion and exclusion criteria

A total of 48 participants with abnormal papillary frenum attachment diagnosed according to Mirko et al.,[29] who were referred to the periodontology department, were involved in this study. The inclusion criteria for the volunteers were as follows: (1) systemically healthy, (2) nonsmoker, (3) between 18 and 65 years of age, (4) not received any periodontal treatment within the last 3 months, (5) presence of at least central incisors, lateral incisors, and canines at the maxilla, and (6) consent to participate in the study. The exclusion criteria were as follows: (1) any systemic disease that might interfere with wound healing process (i.e., diabetes mellitus and HIV infection), (2) smoking, (3) antibiotics, anti-inflammatory drugs, or any other medication taken within the last 6 months that might affect the outcome of the study, (4) any hypersensitivity reactions against to paracetamol, and (5) any physical limitation or restriction that might preclude normal oral hygiene procedures. All subjects signed the written informed consent before participating in the study.

Sample size calculation

The sample size was calculated based on the clinical outcome of a similarly designed study.[23] Post-operative pain was evaluated as the primary outcome of the study. Fourteen subjects per group would provide 80% power to detect a true difference of 0.99 in mean post-operative pain among group with a 0.29 mean standard deviation.

Study groups, randomization, and clinical protocol

Flow diagram of the study is presented in Fig. 1. Seven days before onset of the study, all subjects went through detailed medical and dental history and received intraoral and radiographical examinations. Out of 90 patients assessed for eligibility, 42 subjects were excluded (Fig. 1). Oral hygiene instructions were given to participants who met the inclusion criteria according to their individual needs. At baseline, clinical periodontal parameters of all participants were recorded, followed by mechanical debridement performed using ultrasonic scaler (Cavitron®; Dentsply International) and hand instruments (Gracey, SG 5/6, 7/8, 11/12, 13/14; Hu-Friedy Ins. Co.).

Following, total 48 subjects enrolled in this study were randomly assigned into one of the described groups below through a computer-based randomization table (www.graphpad.com/quickcalcs).

Conventional surgery group (C group; $N=16$). Following local infiltrative anesthesia with articaine HCL associated with epinephrine 1:100,000, the frenum was grasped with a straight hemostat inserted into the depth of the vestibule and the tissue adjacent to the upper and lower surfaces of the hemostat was incised with a no.15 scalpel. Resected diamond-shaped portion of the frenum was removed by hemostat. Then, a horizontal incision was made on the

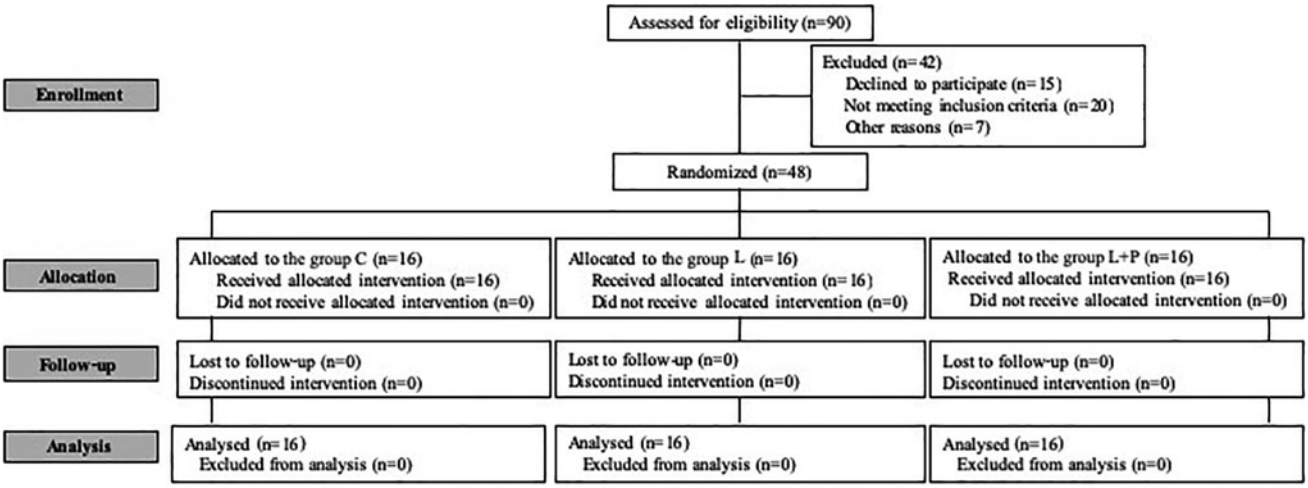

FIG. 1. Flow diagram of patient's enrollment for frenectomy surgery.

periosteum using a scalpel to prevent reinsertion of the fibers. The wound site was primarily closed with the absorbable suture (4/0, Pegelak®; Doğsan), which was removed at post-operative 1 week.

Diode laser-assisted surgery group (L group; $N=16$). The frenectomy procedure was performed under local infiltrative anesthesia with articaine HCL associated with epinephrine 1:100,000. The frenum was held by a straight hemostat similar to the C group and laser energy was applied to the upper and lower parts of the frenum adjacent to the hemostat with a 400 μm diameter, plain-ended, optical fiber tip of a diode laser device (Table 1). The wound site was left to secondary healing without any sutures.

Diode laser-assisted surgery+periosteal incision group (L+P group; $N=16$). In the L+P group, first, the same surgical procedures were performed as the L group. Then, a horizontal incision was made on the periosteum using a scalpel as the C group. The wound site was left to secondary healing without any suture, following bleeding control.

All surgical procedures were performed by an experienced single specialist (H.O.O.). Following surgical interventions, to control the post-operative pain, paracetamol (Vermidon® 500 mg; Sandoz İlac San. & Tic. A.S., Istanbul, Turkey) was prescribed to all participants. Pain scores in patients using analgesics were recorded before drug use. As a precaution, all patients were informed about the maximum dosage of the medication, that is, thrice a day with 8-h intervals.

TABLE 1. DIODE LASER DEVICE'S PARAMETERS

Manufacturer	GIGA Cheese II®
Wavelength	810 nm
Wave emission	Continuous
Total energy	2.5 J/sec
Maximum output power	10 W
Frequency	70 Hz
Fiber	400 μm diameter
Mode	Contact

Clinical evaluation

As aforementioned, all surgical interventions were performed by H.O.O. and all clinical examinations were carried out by a calibrated single examiner (G.S.). While, patients in the C group had sutures for primary wound healing, the patients in the L and L+P groups had no sutures. Thus, neither both clinicians (H.O.O. and G.S.) nor patients were blinded throughout the study period. To achieve the intra-examiner calibration of G.S., 20 nonstudy participants were selected and the distance between the frenum attachment point and mucogingival junction (FMGJ) of these subjects was measured twice within 5 days. The intra-examiner correlation was calculated as 95.13% reproducibility.

Clinical periodontal parameters, including plaque index (PI),[30] gingival index (GI),[31] and bleeding on probing (BoP), were recorded using a periodontal probe of University of North Carolina (PCPUNC15; Hu-Friedy Ins. Co.). All periodontal parameters were recorded in six sites per tooth as full mouth evaluation at baseline and on post-operative 7th, 14th, 21st, and 45th days. To record the duration of the operations, grasping the frenum with hemostat was accepted as the beginning of the operation, and control of the bleeding was accepted as the end of the operation.

A visual analogue scale (VAS), which consisted of a horizontal line with a range of numbers from ''0'' to ''10,'' of which ''0'' means ''no pain'' and ''10'' means unbearable discomfort, was used to evaluate the pain and discomfort during speaking and chewing. Scores about the patient's post-operative perceptions were assessed at 3 h and on the 1st, 7th, 14th, 21st, and 45th days post-operatively.

The epithelization of wound surface was evaluated by applying 3% hydrogen peroxide solution[32] onto the surface on post-operative 7th, 14th, 21st, and 45th days. Catalase enzyme released by the blood cells decomposes the hydrogen peroxide to water and oxygen with foaming. When foaming occurred immediately after application of the solution, epithelization of the wound was considered to be incomplete. When foaming was not observed, epithelization was recorded as complete.

The FMGJ was recorded at baseline, on post-operative 45th day, and 6th month to assess the attachment point of

Downloaded by UPPSALA UNIVERSITETSBIBLIOTEK from www.liebertpub.com at 07/01/20. For personal use only.

the frenum fibers. To find out attachment point of the frenum fibers, a pressure was applied onto frenum with a hand instrument.[3] Following this, gingival papillary tip was mobile and the color of the soft tissue became white.

Statistical analysis

Each patient was accepted as one statistical unit and the statistical analysis was performed by SPSS 20 (SPSS Corporation, Chicago, IL) with a significance level $p<0.05$. The Kolmogorov-Smirnov test was used to check the distribution for normality. Repeated measurements of clinical parameters were analyzed with Friedman test and Wilcoxon signed-rank test. The Kruskal-Wallis, Chi-square, and Fisher's exact tests were used to determine differences among the groups. Moreover, in case of significant difference among groups, the Mann-Whitney U test was used to compare two groups by Bonferroni correction with a significance level of 0.017.

Results

A total of 48 patients (female/male = 27/21) with a mean age of 33.15 ± 10.02 years (range 18–54) were recruited to this study. The mean age of the patients in the C group ($N=16$, female/male = 8/8), L group ($N=16$, female/male = 9/7), and L + P group ($N=16$, female/male = 10/6) was 35.38 ± 8.85, 33.19 ± 11.87, and 30.88 ± 9.21 years, respectively ($p>0.05$). The pre-operative and post-operative clinical appearances representing each study group are shown in Fig. 2.

The comparisons of VAS scores of pain and discomfort during speaking and chewing of the study groups are shown in Table 2. On the 1st and 7th day post-operatively, the pain score of the C group was significantly higher than the L and L + P groups ($p<0.017$) without any significant difference between the L and L + P groups ($p>0.017$). In terms of discomfort during speaking, there was a significant difference among the groups at post-operative 3rd hour ($p=0.000$). In addition to this, VAS score of the C group was approximately four times higher than the L group ($p=0.001$) and six times higher than the L + P group ($p=0.000$) at 3rd hour post-operatively. Similarly, the C group demonstrated significantly higher VAS score of discomfort during speaking than other groups on the 1st day ($p=0.000$). However, no difference was detected among the groups regarding the VAS score of discomfort while speaking during the rest of the study period ($p>0.05$). Chewing discomfort was statistically higher in the C group than the L and L + P groups on post-operative 3 h and 1 and 7 days ($p=0.000$) without any difference between the groups that utilized diode laser ($p>0.05$). No discomfort during chewing was observed in all treatment groups at the remaining time points ($p>0.05$).

As shown in Table 3, no difference was observed among the groups in the PI, GI, and BoP measurements at baseline. Both PI and GI scores of the C group were significantly higher than the L group on the 7 and 45 days post-operatively ($p<0.017$). However, there was no difference regarding BoP percentages among groups in any time period ($p>0.05$) (Table 3). The intragroup analyses revealed that mean values of recorded clinical parameters remained similar throughout the study period in all groups ($p>0.05$).

At baseline, the mean FMGJ distance was similar in all study groups ($p>0.05$) (Table 4). Forty-five days after surgical intervention, the frenums in all groups were observed to be reattached at the level of mucogingival junction, revealing the mean FMGJ distance as 0.00 mm (Table 4). The reductions in the FMGJ distance were significant in all groups ($p=0.000$), without any difference among them ($p>0.05$). When the reattachment of frenums was assessed at 6 months, no recurrence was detected in any of the groups, again without any difference among them ($p>0.05$) (Table 4).

The mean duration of the operation was approximately three times longer in the C group compared with both L and L + P groups ($p=0.000$) (Table 4). Even though the number of medication consumed was similar in all groups at 3 h post-operatively ($p>0.05$), it was observed that patients in the C group needed to take medication significantly more than the other two groups on the 1st day after operation ($p=0.000$) (Table 4). Analgesic usage was found to be the highest in the C group, parallel to high pain VAS scores on the 1st day.

As shown in Table 5, none of the participants presented whole epithelization of the wound surface on day 7, except one patient from the L + P group ($p>0.05$). All groups demonstrated completely epithelialized wound area on the post-operative 14th day.

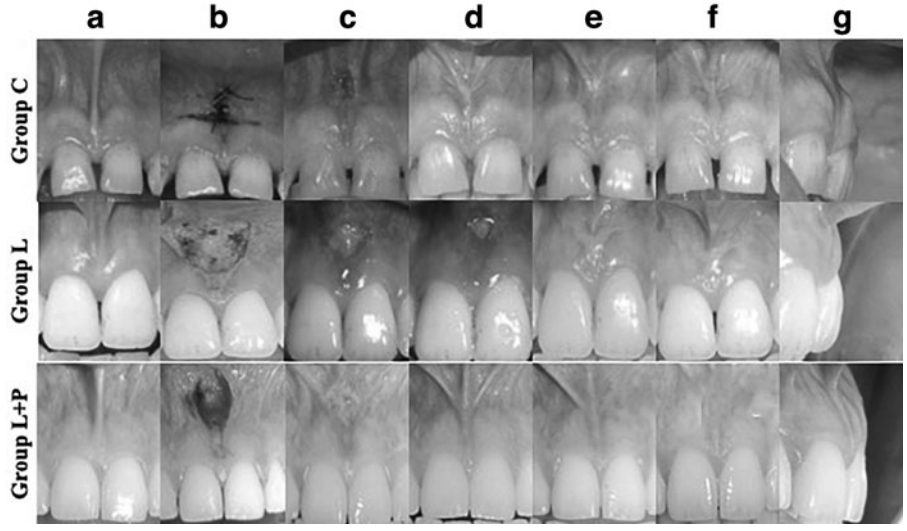

FIG. 2. Comparison of the group C, group L, and group L + P **(a)** baseline intraoral view; **(b)** the wound site after operation; **(c)** the clinical appearance of healing on post-operative 7th, **(d)** 14th, **(e)** 21st, **(f)** and 45th day and **(g)** 6th month.

Downloaded by UPPSALA UNIVERSITETSBIBLIOTEK from www.liebertpub.com at 07/01/20. For personal use only.

Downloaded by UPPSALA UNIVERSITETSBIBLIOTEK from www.liebertpub.com at 07/01/20. For personal use only.

Table 2. The Comparison of Visual Analogue Scale Scores of Pain, and Discomfort at Speaking and Chewing Within and Among the Groups

	Pain				*Speaking*				*Chewing*			
	Group C (mean ± SD)	*Group L (mean ± SD)*	*Group L+P (mean ± SD)*	p*	*Group C (mean ± SD)*	*Group L (mean ± SD)*	*Group L+P (mean ± SD)*	p*	*Group C (mean ± SD)*	*Group L (mean ± SD)*	*Group L+P (mean ± SD)*	p*
Hour 3	2.06 ± 2.17	0.88 ± 1.15	0.44 ± 0.61	0.087	2.94 ± 2.44	0.69 ± 0.79†	0.44 ± 0.63†	0.000	2.69 ± 1.78	0.69 ± 1.14†	0.38 ± 0.89†	0.000
Day 1	0.94 ± 1.39	0.06 ± 0.25†	0.06 ± 0.25†	0.002	1.19 ± 1.28	0.06 ± 0.25†	0.06 ± 0.25†	0.000	2.31 ± 2.33	0.06 ± 0.25†	0.06 ± 0.25†	0.000
Day 7	1.69 ± 1.35	0.00 ± 0.00†	0.06 ± 0.25†	0.000	0.00 ± 0.00	0.00 ± 0.00	0.00 ± 0.00	1.000	1.25 ± 1.16	0.00 ± 0.00†	0.06 ± 0.25†	0.000
Day 14	0.00 ± 0.00	0.00 ± 0.00	0.00 ± 0.00	1.000	0.00 ± 0.00	0.00 ± 0.00	0.00 ± 0.00	1.000	0.00 ± 0.00	0.00 ± 0.00	0.00 ± 0.00	1.000
Day 21	0.00 ± 0.00	0.00 ± 0.00	0.00 ± 0.00	1.000	0.00 ± 0.00	0.00 ± 0.00	0.00 ± 0.00	1.000	0.00 ± 0.00	0.00 ± 0.00	0.00 ± 0.00	1.000
Day 45	0.00 ± 0.00	0.00 ± 0.00	0.00 ± 0.00	1.000	0.00 ± 0.00	0.00 ± 0.00	0.00 ± 0.00	1.000	0.00 ± 0.00	0.00 ± 0.00	0.00 ± 0.00	1.000
$p^{\ddagger}$	0.000	0.000	0.000		0.000	0.000	0.000		0.000	0.000	0.000	

Difference among groups, *Kruskal-Wallis test ($p < 0.05$); †Mann-Whitney U test Bonferroni correction ($p < 0.017$), compared to the group C; ‡Friedman test ($p < 0.05$).
SD, standard deviation.

Table 3. The Periodontal Parameters Throughout the Study Period

	PI				*GI*				*BoP (%)*			
	Group C (mean ± SD)	*Group L (mean ± SD)*	*Group L+P (mean ± SD)*	p*	*Group C (mean ± SD)*	*Group L (mean ± SD)*	*Group L+P (mean ± SD)*	p*	*Group C (mean ± SD)*	*Group L (mean ± SD)*	*Group L+P (mean ± SD)*	p*
Baseline	0.91 ± 0.16	0.91 ± 0.07	0.87 ± 0.14	0.243	0.93 ± 0.83	0.86 ± 0.08	0.89 ± 0.10	0.056	0.18 ± 0.66	0.42 ± 0.97	0.20 ± 0.58	0.212
Day 7	0.98 ± 0.04	0.84 ± 0.16†	0.89 ± 0.13	0.001	0.99 ± 0.04	0.87 ± 0.11†	0.90 ± 0.21	0.000	0.74 ± 1.69	0.16 ± 0.64	0.07 ± 0.28	0.065
Day 14	0.95 ± 0.07	0.87 ± 0.07	0.86 ± 0.19	0.022	0.90 ± 0.24	0.84 ± 0.16	0.85 ± 0.17	0.112	0.48 ± 0.83	0.24 ± 0.95	0.21 ± 0.63	0.092
Day 21	0.95 ± 0.07	0.86 ± 0.13	0.89 ± 0.15	0.037	0.95 ± 0.06	0.89 ± 0.09	0.87 ± 0.17	0.086	0.21 ± 0.73	0.03 ± 0.01	0.07 ± 0.28	0.202
Day 45	0.93 ± 0.24	0.84 ± 0.13†	0.90 ± 0.14	0.003	0.93 ± 0.22	0.86 ± 0.09†	0.88 ± 0.14	0.001	0.74 ± 1.69	0.16 ± 0.64	0.00 ± 0.00	0.212
$p^{\ddagger}$	0.396	0.320	0.616		0.342	0.264	0.795		0.729	0.736	0.637	

*Kruskal-Wallis test ($p < 0.05$); †Mann-Whitney U test Bonferroni correction ($p < 0.017$), compared to the group C; ‡Friedman test ($p < 0.05$).
BoP, bleeding on probing; GI, gingival index; PI, plaque index.

Table 4. Comparison of Distance Between the Frenum Attachment Point and Mucogingival Junction, Surgical Time, and Analgesic Consumption Among the Groups

	Group C (mean ± SD)	*Group L (mean ± SD)*	*Group L+P (mean ± SD)*	p*
FMGJ (mm)				
Baseline	6.06 ± 1.73	5.06 ± 1.44	6.00 ± 1.55	0.171
Day 45	0.00 ± 0.00	0.00 ± 0.00	0.00 ± 0.00	—
Month 6	0.00 ± 0.00	0.00 ± 0.00	0.00 ± 0.00	—
Surgical time				
Duration (min)	12.56 ± 1.26	4.19 ± 0.66†	4.56 ± 0.89†	0.000
Analgesic				
Hour 3	0.50 ± 0.52	0.25 ± 0.45	0.13 ± 0.34	0.063
Day 1	0.38 ± 0.62	0.13 ± 0.34†	0.00 ± 0.00†	0.042

*Kruskal-Wallis test ($p < 0.05$).
†Mann-Whitney U test Bonferroni correction ($p < 0.017$) compared to the group C.
FMGJ, distance between the frenum attachment point and mucogingival junction.

Downloaded by UPPSALA UNIVERSITETSBIBLIOTEK from www.liebertpub.com at 07/01/20. For personal use only.

Discussion

With their brilliance and excellent energy efficiency, diode lasers are suitable for oral soft tissue applications due to their beneficial effects regarding sufficient hemostasis, precise incision margin, and lack of swelling and pain.[24,33,34] In the field of periodontology, diode lasers are widely opted for pocket disinfection, excisional new attachment procedure, frenectomy, gingivectomy/gingivoplasty, crown lengthening and so on.[1,9,19–22] In this randomized, parallel-design clinical study, the patient's perceptions and clinical healing following conventional and diode laser-assisted frenectomies were evaluated.

It has been demonstrated that patients who underwent laser-assisted frenectomy operation experienced less post-operative pain and discomfort compared to the patients treated with conventional frenectomy.[24,25,28,35] Pain is a subjective perception and it is hard to reach an accurate assessment. There are several methods, including verbal rating scale, numerical rating scale, and VAS, for assessing pain.[36] VAS is the most commonly used method for evaluating pain,[1,35,37] since it provides an effective short-term assessment that can be easily processed by both patients and clinicians.[37] In this study, pain was assessed by VAS on post-operative 3rd hour and 1st, 7th, 14th, 21st, and 45th day. Mean VAS pain score of the C group at post-operative 3 h was found to be two-fold higher than the L group and almost 4.5-fold higher than the L+P group. Similarly, Kara[23] reported significantly higher pain perception in the conventional frenectomy group than the Nd:YAG laser group at 3 h post-operatively. Results of the previous studies revealed that VAS scores on post-operative 1 and 7 days were lower in the laser group compared to the conventional frenectomy group, which was compatible with our findings.[17,24–28] This can be attributed to the fact that conventional frenectomy is a relatively more invasive surgical treatment yielding larger surgical wound area, and that existing sutures may lead to increased pain perception. It has been also suggested that the reduction in pain perception after laser application is a result of nerve endings becoming unable to develop anastomosis with each other.[38] In the light of our findings, diode laser-assisted frenectomy yielded less post-operative pain on days 1 and 7 than the conventional technique.

As a key point to maintain patient's life quality, speech and chewing functions following periodontal surgery should not be painful. At post-operative 3rd hour, difficulty in chewing and speaking in the C group patients was observed to be higher than other groups. Similarly, in the study conducted by Kara,[23] discomfort in speaking and chewing was lower in the laser group than the conventional group. In concordance with our findings, some studies showed that patient's discomfort scores regarding chewing and speaking were lower in the laser group in the early period following surgical intervention.[17,24,25] Affecting daily functions, including speaking and chewing, existence of sutures, the tension, and pain perception at the wound area after conventional frenectomy surgery may result in higher difficulty scores in speaking and chewing in this treatment group.

In conventional frenectomy operations, a horizontal incision is applied on the periosteum to prevent reattachment of the dissected frenum fibrils.[39] Thus, in our study, a horizontal incision on the periosteum was performed not only in the conventional technique as required but also in the L+P group to investigate the reattachment on the post-operative 45 day and 6th month. So far, the only study evaluating reattachment of the frenum was reported by Pie-Sanchez

Table 5. Comparison of Epithelization Among the Treatment Groups

	Group C, N *(%)*		*Group L,* N *(%)*		*Group L+P,* N *(%)*		
	(+)	(−)	(+)	(−)	(+)	(−)	p[a]
Day 7	0 (0)	16 (100)	0 (0)	16 (100)	1 (6.2)	15 (93.8)	0.360
Day 14	16 (100)	0 (0)	16 (100)	0 (0)	16 (100)	0 (0)	1.000

[a]Pearson's Chi-square test ($p < 0.05$).
N, number of patients with complete epithelization.

Downloaded by UPPSALA UNIVERSITETSBIBLIOTEK from www.liebertpub.com at 07/01/20. For personal use only.

et al.,[3] who operated 50 pediatric patients randomly with either CO_2 laser or Er,Cr:YSGG laser without any horizontal incision on the periosteum. They demonstrated that the frenum fibrils reinserted at the mucogingival junction in both groups. Our findings and the results of Pie-Sanchez et al.[3] provide evidence that horizontal incision on the periosteum yielding scar formation is not a requirement to prevent the reattachment of the frenum fibrils to their original position in the laser-assisted frenectomy operations.

Healing duration differs in every tissue, depending on its nature and function.[40] While the primary wound healing is observed in conventional frenectomy surgery since surgical area is closed by suturing, the wound area is left to secondary healing in laser-assisted frenectomy. Patel et al.[25] evaluated healing visually after conventional and diode laser frenectomy operations with scores of ''complete epithelization'' and ''incomplete epithelization,'' and demonstrated that there was a difference in favor of the conventional group on the 7th day and 1st month in terms of wound healing. However, at the end of the 3rd month, wound healing did not show any difference between the groups. In our study, wound surfaces were rinsed with hydrogen peroxide solution and the foaming was evaluated. While both C and L groups showed no epithelialization on post-operative 7 days and only one patient had epithelialization in the L+P group (6.2%), it was completed in all groups on the 14th day. It has been suggested that delayed wound healing following laser application may be observed due to thermal damage during operation.[32,41] On the contrary, Fisher et al.[42] reported that laser-induced wounds demonstrated faster recovery and less scar formation than the conventional methods. Our findings revealed no difference between the conventional frenectomy healed by primary closure of the surgical area and laser-assisted frenectomy with secondary wound healing in terms of epithelization period.

It is not always easy to ensure optimal patient coordination and comfort following periodontal surgeries. To take the post-operative pain under control, paracetamols can be prescribed after frenectomy operations.[1,23–25,43] Some studies[1,23] had assessed the patient's discomfort and analgesic consumption after conventional technique and laser-assisted frenectomy. While Haytac and Ozcelik[1] reported that analgesic consumption percentage was 2.5 times higher in the conventional group than the laser group, Kara[23] showed this percentage $\sim$18.5 times higher in the conventional group. Similar to aforementioned studies, Kaur et al.[24] and Patel et al.[25] stated that the analgesic consumption in the diode laser-assisted frenectomy group was found to be less than the conventional frenectomy group. As clearly seen in our findings, due to the invasive surgical trauma, the conventional frenectomy group suffered more analgesic consumption compared to the laser-assisted frenectomy groups at post-operative 3rd hour and 1st day.

Another important issue about patient expectations in dental treatments is the time management. Results of our study revealed that mean surgical duration of the C group was three times longer than others. Junior et al.[43] reported that the duration of laser surgery was significantly shorter than conventional group, as expected. Laser-assisted surgical interventions prevent bleeding and do not require suturing, which enable the surgeons to complete the procedure in a short period of time. Thus, laser-assisted surgery possess high patient acceptance due to post-operative comfort.

One of the limitations of this study is the patients' daily stress and psychological state that may affect their perceptions. In addition, the menstrual period may significantly affect pain perception in female patients.[44]

Conclusions

Within the limits of this study, the use of diode laser in frenectomy provides less post-operative pain and discomfort during speaking and chewing in patients with abnormal papillary frenum attachments. Moreover, both conventional and laser-assisted frenectomy surgeries lead to same epithelization period and prevent the frenum reattachment regardless of periosteal horizontal incision.

Author Disclosure Statement

The authors declared that no competing financial interests exist.

Funding Information

This study was supported by a grant from Marmara University Scientific Research Project Commission, Istanbul, Turkey with the number: SAG-C-DUP-120516-0213.

References

1. Haytac MC, Ozcelik O. Evaluation of patient perceptions after frenectomy operations: a comparison of carbon dioxide laser and scalpel techniques. J Periodontol 2006;77:1815–1819.
2. Cortellini P, Bissada NF. Mucogingival conditions in the natural dentition: narrative review, case definitions, and diagnostic considerations. J Periodontol 2018;89(Suppl 1):204–213.
3. Pie-Sanchez J, Espana-Tost AJ, Arnabat-Dominguez J, Gay-Escoda C. Comparative study of upper lip frenectomy with the CO_2 laser versus the Er, Cr:YSGG laser. Med Oral Patol Oral Cir Bucal 2012;17:228–232.
4. Oesterle LJ, Shellhart WC. Maxillary midline diastemas: a look at the causes. J Am Dent Assoc 1999;130:85–94.
5. Gkantidis N, Kolokitha OE, Topouzelis N. Management of maxillary midline diastema with emphasis on etiology. J Clin Pediatr Dent 2008;32:265–272.
6. Edwards JG. The diastema, the frenum, the frenectomy: a clinical study. Am J Orthod 1977;71:489–508.
7. Ishikawa I, Aoki A, Takasaki AA, Mizutani K, Sasaki KM, Izumi Y. Application of lasers in periodontics: true innovation or myth? Periodontol 2000 2009;50:90–126.
8. Slot DE, Kranendonk AA, Paraskevas S, Van der Weijden F. The effect of a pulsed Nd:YAG laser in non-surgical periodontal therapy. J Periodontol 2009;80:1041–1056.
9. Stabholz A, Zeltser R, Sela M, et al. The use of lasers in dentistry: principles of operation and clinical applications. Compend Contin Educ Dent 2003;24:935–948.
10. White JM, Goodis HE, Rose CL. Use of the pulsed Nd:YAG laser for intraoral soft tissue surgery. Lasers Surg Med 1991;11:455–461.
11. Azma E, Safavi N. Diode laser application in soft tissue oral surgery. J Lasers Med Sci 2013;4:206–211.
12. Moshonov J, Orstavik D, Yamauchi S, Pettiette M, Trope M. Nd:YAG laser irradiation in root canal disinfection. Endod Dent Traumatol 1995;11:220–224.
13. Pogrel MA, Yen CK, Hansen LS. A comparison of carbon dioxide laser, liquid nitrogen cryosurgery, and scalpel wounds in healing. Oral Surg Oral Med Oral Pathol 1990; 69:269–273.

Downloaded by UPPSALA UNIVERSITETSBIBLIOTEK from www.liebertpub.com at 07/01/20. For personal use only.

14. De Santis D, Gerosa R, Graziani PF, et al. Lingual frenectomy: a comparison between the conventional surgical and laser procedure. Minerva Stomatol 2013;62(Suppl 1):45–53.
15. Gontijo I, Navarro RS, Haypek P, Ciamponi AL, Haddad AE. The applications of diode and Er:YAG lasers in labial frenectomy in infant patients. J Dent Child (Chic) 2005;72:10–15.
16. Yang HY, Zheng LW, Yang HJ, Luo J, Li SC, Zwahlen RA. Long-pulsed Nd:YAG laser treatment in vascular lesions of the oral cavity. J Craniofac Surg 2009;20:1214–1217.
17. Butchibabu K, Koppolu P, Mishra AP, Swapna LA, Uppada UK. Evaluation of patient perceptions after labial frenectomy procedure: a comparison of diode laser and scalpel techniques. Eur J Gen Dent 2014;3:129–133.
18. Aoki A, Sasaki KM, Watanabe H, Ishikawa I. Lasers in nonsurgical periodontal therapy. Periodontol 2000 2004;36:59–97.
19. Meseli SE, Kuru B, Kuru L. Effects of 810-nanometer diode laser as an adjunct to mechanical periodontal treatment on clinical periodontal parameters and gingival crevicular fluid volume of residual periodontal pockets. Niger J Clin Pract 2017;20:427–432.
20. Isola G, Matarese G, Lo Giudice G, et al. A new approach for the treatment of lateral periodontal cysts with an 810-nm diode laser. Int J Periodontics Restorative Dent 2017;37:e120–e129.
21. Isola G, Matarese G, Cervino G, Matarese M, Ramaglia L, Cicciù M. Clinical efficacy and patient perceptions of pyogenic granuloma excision using diode laser versus conventional surgical techniques. J Craniofac Surg 2018;29:2160–2163.
22. Pamuk F, Lütfioğlu M, Aydoğdu A, Koyuncuoglu CZ, Cifcibasi E, Badur OS. The effect of low-level laser therapy as an adjunct to non-surgical periodontal treatment on gingival crevicular fluid levels of transforming growth factor-beta 1, tissue plasminogen activator and plasminogen activator inhibitor 1 in smoking and non-smoking chronic periodontitis patients: a split-mouth, randomized control study. J Periodontal Res 2017;52:872–882.
23. Kara C. Evaluation of patient perceptions of frenectomy: a comparison of Nd:YAG laser and conventional techniques. Photomed Laser Surg 2008;26:147–152.
24. Kaur P, Dev YP, Kaushal S, Bhatia A, Vaid R, Sharma R. Management of the upper labial frenum: a comparison of conventional surgical and lasers on the basis of visual analogue scale on patients perception. J Periodontal Med Clin Pract 2014;1:38–46.
25. Patel R, Varma S, Suragimath G, Abbayya K, Zope S, Kale V. Comparison of labial frenectomy procedure with conventional surgical technique and diode laser. J Dent Lasers 2015;9:94–99.
26. Yüce H, Tülü F, Karataş Ö, Yarkaç F. Comparison of the postoperative pain and discomfort after diode laser and conventional frenectomy. J Dent Fac Atatürk Uni 2017;27:57–62.
27. Miller PD. Frenectomy combined with a laterally positioned pedicle graft-functional and esthetic considerations. J Periodont 1985;56:102–106.
28. Uraz A, Cetiner FD, Cula S, Guler B, Oztoprak S. Patient perceptions and clinical efficacy of labial frenectomies using diode laser versus conventional techniques. J Stomatol Oral Maxillofac Surg 2018;119:182–186.
29. Mirko P, Miroslav S, Lubor M. Significance of the labial frenum attachment in periodontal disease in man. Part I. Classification and epidemiology of the labial frenum attachment. J Periodontol 1974;45:891–894.
30. Silness J, Loe H. Periodontal disease in pregnancy. II. Correlation between oral hygiene and periodontal condition. Acta Odontol Scand 1964;22:121–135.
31. Loe H, Silness J. Periodontal disease in pregnancy. I. Prevalence and severity. Acta Odontol Scand 1963;21:533–551.
32. Isler SC, Uraz A, Guler B, Ozdemir Y, Cula S, Cetiner D. Effects of laser photobiomodulation and ozone therapy on palatal epitehelial wound healing and patient morbidity. Photomed Laser Surg 2018;36:571–588.
33. Buell BR, Schuller DE. Comparison of tensile strength in CO_2 laser and scalpel skin incisions. Arch Otolaryngol 1983;109:465–467.
34. Calisir M, Ege B. Evaluation of patient perceptions after frenectomy operations: a comparison of neodymium-doped yttrium aluminum garnet laser and conventional techniques in the same patients. Niger J Clin Pract 2018;21:1059–1064.
35. Akpinar A, Toker H, Lektemur Alpan A, Calisir M. Postoperative discomfort after Nd: YAG laser and conventional frenectomy: comparison of both genders. Aust Dent J 2016;61:71–75.
36. Sirintawat N, Sawang K, Chaiyasamut T, Wongsirichat N. Pain measurement in oral and maxillofacial surgery. J Dent Anesth Pain Med 2017;17:253–263.
37. Yucel A, Senocak M, Kocasoy Orhan E, Cimen A, Ertas M. Results of the Leeds assessment of neuropathic symptoms and signs pain scale in Turkey: a validation study. J Pain 2004;5:427–432.
38. Ize-Iyamu IN, Saheeb BD, Edetanlen BE. Comparing the 810 nm diode laser with conventional surgery in orthodontic soft tissue procedures. Ghana Med J 2013;47:107–111.
39. Archer WH. Oral surgery for a dental prosthesis. In: Oral and Maxillofacial Surgery. WH Archer (ed.). Philadelphia, PA: Saunders, 1975; pp. 135–210.
40. Wang PH, Huang BS, Horng HC, Yeh CC, Chen YJ. Wound healing. J Chin Med Assoc 2018;81:94–101.
41. Goharkhay K, Moritz A, Wilder-Smith P, et al. Effects on oral soft tissue produced by a diode laser in vitro. Lasers Surg Med 1999;25:401–406.
42. Fisher SE, Frame JW, Browne RM, Tranter RM. A comparative histological study of wound healing following CO_2 laser and conventional surgical excision of canine buccal mucosa. Arch Oral Biol 1983;28:287–291.
43. Junior RM, Gueiros LA, Silva IH, de Albuquerque Carvalho A, Leao JC. Labial frenectomy with Nd:YAG laser and conventional surgery: a comparative study. Lasers Med Sci 2015;30:851–856.
44. Fatima N, Babu PR, Sisinty VS, Tarakji B. Pain perception and anxiety levels during menstrual cycle associated with periodontal therapy. Int J Dent 2014;2014:472926.

Address correspondence to:
Hafize Ozturk Ozener, DDS, PhD
Department of Periodontology
Faculty of Dentistry
Marmara University
Basibuyuk Saglik Yerleskesi, Basibuyuk Yolu, 9/3
34854 Maltepe/Istanbul
Turkey

E-mail: hafize.ozturk@marmara.edu.tr

Received: November 27, 2019.
Accepted after revision: January 27, 2020.
Published online: June 30, 2020.