Rev Bras Anestesiol. 2017;67(2):139–146

Sociedade Brasileira de Anestesiologia

REVISTA BRASILEIRA DE ANESTESIOLOGIA

Publicação Oficial da Sociedade Brasileira de Anestesiologia
www.sba.com.br



SCIENTIFIC ARTICLE

Effect of dexmedetomidine on acute lung injury in experimental ischemia–reperfusion model

Ömer Burak Küçükebe[a], Deniz Özzeybek[b], Ruslan Abdullayev[a,*], Adil Ustaoğlu[c], Işıl Tekmen[d], Tuncay Küme[e]

[a] *Adıyaman University Research and Educational Hospital, Department of Anesthesiology and Reanimation, Adıyaman, Turkey*
[b] *Dokuz Eylül University Medical Faculty, Department of Anesthesiology and Reanimation, İzmir, Turkey*
[c] *Zonguldak Atatürk Hospital, Department of Anesthesiology and Reanimation, Zonguldak, Turkey*
[d] *Dokuz Eylül University Medical Faculty, Department of Histology and Embryology, İzmir, Turkey*
[e] *Dokuz Eylül University Medical Faculty, Department of Medical Biochemistry, İzmir, Turkey*

Received 1 March 2015; accepted 17 August 2015
Available online 21 March 2016

KEYWORDS
Experimental;
Dexmedetomidine;
Reperfusion injury;
Acute lung injury

Abstract
Purpose: Ischemia–reperfusion injury is one of the consequences of tourniquet application for extremity surgery. The aim of the study was to establish the effect of dexmedetomidine on the acute lung injury following lower extremity experimental ischemia–reperfusion model in rats.
Methods: Twenty-eight Wistar-Albino breed Rats were recruited after Ethics Committee approval and allocated into 4 groups, each with 7 subjects. Group 1 (SHAM) received only anesthesia. Group 2 (IR) had experienced 3 h of ischemia and 3 h of reperfusion using left lower extremity tourniquet after anesthesia application. Groups 3 (D-50) and 4 (D-100) had undergone the same procedures as in the Group 2, except for receiving 50 and 100 $mg \cdot kg^{-1}$, respectively, dexmedetomidine intraperitoneally 1 h before the tourniquet release. Blood samples were obtained for the analysis of tumor necrosing factor-α and interleukin-6. Pulmonary tissue samples were obtained for histological analysis.
Results: No significant difference regarding blood tumor necrosing factor-α and interleukin-6 values was found among the groups, whereas pulmonary tissue injury scores revealed significant difference. Histological scores obtained from the Group 2 were significantly higher from those in the Groups 1, 3 and 4 with *p*-values 0.001 for each comparison. Moreover, Group 1 scores were found to be significantly lower than those in the Groups 3 and 4 with *p*-values 0.001 and 0.011, respectively. No significant difference was observed between the Groups 3 and 4.
Conclusion: Dexmedetomidine is effective in reduction of the experimental ischemia–reperfusion induced pulmonary tissue injury in rats, formed by extremity tourniquet application.
© 2016 Sociedade Brasileira de Anestesiologia. Published by Elsevier Editora Ltda. This is an open access article under the CC BY-NC-ND license (http://creativecommons.org/licenses/by-nc-nd/4.0/).

* Corresponding author.
E-mail: ruslan_jnr@hotmail.com (R. Abdullayev).

http://dx.doi.org/10.1016/j.bjane.2015.08.002
0104-0014/© 2016 Sociedade Brasileira de Anestesiologia. Published by Elsevier Editora Ltda. This is an open access article under the CC BY-NC-ND license (http://creativecommons.org/licenses/by-nc-nd/4.0/).

PALAVRAS-CHAVE
Experimental;
Dexmedetomidina;
Lesão de reperfusão;
Lesão pulmonar aguda

Efeito de dexmedetomidina sobre lesão pulmonar aguda em modelo experimental de isquemia-reperfusão

Resumo
Objetivo: A lesão de isquemia-reperfusão é uma das consequências da aplicação do torniquete em cirurgias de extremidades. O objetivo do estudo foi determinar o efeito de dexmedetomidina em lesão pulmonar aguda após modelo experimental de isquemia-reperfusão em extremidade inferior de ratos.
Métodos: Vinte e oito ratos albinos Wistar foram recrutados após aprovação do Comitê de Ética e alocados em quatro grupos, cada um com sete indivíduos. O Grupo 1 (Sham) recebeu apenas anestesia. O Grupo 2 (IR) foi submetido a 3 horas de isquemia e 3 horas de reperfusão com o uso de torniquete em extremidade inferior após a aplicação da anestesia. Os grupos 3 (D-50) e 4 (D-100) foram submetidos aos mesmos procedimentos do Grupo 2, exceto por receberem 50 e 100 $mg \cdot kg^{-1}$ de dexmedetomidina, respectivamente, por via intraperitoneal 1 hora antes da liberação do torniquete. Amostras de sangue foram coletadas para análise de TNF-α e Interleucina-6 (IL-6). Amostras de tecido pulmonar foram coletadas para análise histológica.
Resultados: Não houve diferença significativa quanto aos valores sanguíneos de TNF-α e IL-6 entre os grupos, enquanto os escores de lesão em tecidos pulmonares revelaram diferença significativa. Os escores histológicos obtidos no Grupo 2 foram significativamente maiores que os dos grupos 1, 3 e 4, com valores-*p* de 0,001 para cada comparação. Além disso, os escores do Grupo 1 foram significativamente menores que os dos grupos 3 e 4, com valores-*p* de 0,001 e 0,011, respectivamente. Não houve diferença significativa entre os grupos 3 e 4.
Conclusão: Dexmedetomidina mostrou eficácia na redução de lesão em tecido pulmonar induzida por isquemia-reperfusão experimental em ratos, ocasionada por aplicação de torniquete em extremidade.
© 2016 Sociedade Brasileira de Anestesiologia. Publicado por Elsevier Editora Ltda. Este é um artigo Open Access sob uma licença CC BY-NC-ND (http://creativecommons.org/licenses/by-nc-nd/4.0/).

Introduction

Cessation of the blood flow, namely tissue ischemia, and reperfusion after a period of time are the main pathophysiological mechanisms responsible for organ damages following some clinical conditions like organ transplantation, cerebral ischemia, stroke, myocardial infarction, thromboemboli, cardiopulmonary bypass and vascular surgeries, major trauma and hemorrhagic shock, as well as surgical procedures with tourniquet use.[1,2] Ischemic damage is mainly the result of the necrosis of the cells due to oxygen cessation; oxygen supply during ischemia is not enough to meet the metabolic needs of the cells and this condition results in the activation of the anaerobic metabolism.[3] When the tissue blood flow is provided again, i.e. reperfusion starts, it paradoxically increases the local tissue damage, together with an inflammatory response resulting in distant organ damage.[2,3] Many inflammatory agents have been shown to be responsible for this damage, namely ischemia–reperfusion injury (IRI).[2]

Cytokines have been blamed for distant organ damage of IRI.[4] Blood, kidney and lung tumor necrosing factor-α (TNF-α), interleukin (IL) IL-1 and IL-6 levels have been found to be high after lower extremity ischemia.[5] The mediators released after ischemia–reperfusion (IR) result in local and distant organ injuries through free oxygen radicals and leukocytes.[6,7] Negative immunoregulatory effects of noradrenaline have been demonstrated in the formation of monocyte/macrophage origin mediators (TNF-α, IL-1, IL-6) and this effect was linked to its both β and α_2 adrenoceptors.[8]

Dexmedetomidine is a strong and selective α_2-adrenergic agonist that is an active d-isomer of medetomidine and metabolized in the liver. It has been approved to be used for sedation in intensive care unit and possesses sedative and analgesic characteristics.[9,10] There are few studies in the literature regarding anti-inflammatory effects of dexmedetomidine.[11–16] Yagmurdur et al.[14] have demonstrated dexmedetomidine to decrease the levels of malondialdehyde and hypoxanthine (that are formed after IR), following tourniquet application for upper extremity surgery. Although it has been shown that dexmedetomidine has some protective effects for IRI locally, we have not encountered a study regarding its effects on systemic inflammatory response and distant organ damage.

We aimed to establish the effects of two different doses of dexmedetomidine on the acute lung injury following lower extremity experimental IR model in rats. The hypothesis was based on possible protective effects of dexmedetomidine taking into consideration its anti-inflammatory effects.

Methods

This study was carried out in Dokuz Eylul University Medical Faculty Multidisciplinary Animal Laboratory between 01/01/2009 and 31/05/2009 after the obtainment of the

approval of Dokuz Eylul University Experimental Animal Studies Ethics Committee, İzmir, Turkey (24/11/2008, n° 134, Chairperson Prof. M. Olguner). Twenty-eight adult female Wistar-Albino breed rats weighting 250–340 g were used for the study. The animals were provided with standard pellet food and water and were kept in 12-hour cycles of light and dark for adaptation before the commencement of the study. The temperature and humidity were also standardized.

The rats were fasted for 12 h before the surgical procedure and were allowed to drink water only. Each rat was weighted before the experiment and the doses of dexmedetomidine were calculated. They were randomly allocated into one of the 4 groups using closed envelope method. Group 1 (SHAM, $n=7$) received only anesthesia with blood sample obtainment at the 1st hour of reperfusion and blood and tissue sample obtainment at the end of the reperfusion. Group 2 (IR, $n=7$) had experienced 3 h of ischemia and 3 h of reperfusion using left lower extremity tourniquet after anesthesia application. Blood sample was obtained at the 1st hour of reperfusion and at the end of the reperfusion blood and tissue samples were obtained. Group 3 (D-50, $n=7$) had undergone the same procedures as in the Group 2, except for receiving 50 μg/kg dexmedetomidine (Precedex, Abbott Laboratories Ltd. North Chicago ABD, 100 μ/mL) intraperitoneally 1 hour before the tourniquet release. Group 4 (D-100, $n=7$) had undergone the same procedures as in the Group 2, except for receiving 100 μg/kg dexmedetomidine intraperitoneally 1 h before the tourniquet release. Again the blood samples were obtained at the 1st hours of the reperfusion with blood and tissue samples at the end of the reperfusion for the Groups 3 and 4.

Anesthesia was performed using 50 $mg \cdot kg^{-1}$ ketamine (Pfizer Pharma GMBH, Germany) and 10 $mg \cdot kg^{-1}$ xylazine hydrochloride (Alfazine, 2%, Egevet) mixture applied intraperitoneally. Ischemia was performed using elastic bandage (1 cm width and 30 cm length) applied to the inguinal region of the left lower extremity. The tourniquet was deflated to establish reperfusion after the certain period of time. The environment temperature was kept stable and the operation table was heated to protect the rats from hypothermia and the body temperatures were kept between 36.8 °C and 37.5 °C. The rats were hydrated with 3 mL/kg/h isotonic sodium chloride subcutaneously throughout the IR procedure to avoid dehydration. The subjects were sacrificed after the obtainment of samples of blood and tissue. The procedure durations were kept equal in all the groups.

At the end of the 1st hour of 3-hour reperfusion period 1.5 mL blood was drawn from the tail vein of the rats for the analysis of TNF-α and IL-6, were put into sterile tube with ethylenediaminetetraacetic acid (EDTA) and centrifuged for 10 min with 1200 rpm speed. Plasma of the blood samples were separated put into Eppendorf tubes, freezed and kept at 70 °C until the analysis day. The rats received isotonic sodium chloride intraperitoneally equal to the amount lost for sampling. At the end of the reperfusion thorax was opened by subdiaphragmatic approach. Blood sample for TNF-α and IL-6 analysis was obtained in 2 mL volume directly from the heart and was kept using the same method as mentioned above. At the end of the procedure 5 mL of 10% formol was slowly applied through the cardiac apex via 20G needle and heart and lung bed were excised after the sacrification. A section from the middle zone of the right lung and the left lung totally were put into 10% formol and kept fixed for at least 24 h.

Analysis of inflammatory mediators

The analysis of inflammatory mediators (TNF-α vs. IL-6) was performed via Enzyme-Linked Immunosorbent Assay (ELISA). Absorbent values were read at 450 nm in the ELISA device (Organon Technica Microwell System Reader 230S). The results were expressed in pg/mL.

Histopathological analysis

Pulmonary tissues obtained from the subjects were stained using hematoxylin-eosin method and examined by light microscope (Olympus BH-2) under 200× magnification. Six random regions were selected from each sample and 0–4 point scoring were made taking into account histopathological findings like alveolar and interstitial hemorrhage, alveolar and interstitial neutrophile infiltration, edema and atelectasis. Scoring was made according to the injured area proportion as 0: no injury, 1: <25% injury, 2: 25–50% injury, 3: 50–75% injury, 4: diffuse injury.

Statistical analysis

The data obtained was evaluated using SPSS 11.0 software (Statistical Package for the Social Sciences, Chicago, Illinois). Kruskall Wallis and Chi-square tests were used for comparison of the groups. Mann–Whitney *U* test was used for comparison of the groups separately and Bonferroni correction was used when needed. *p*-Values less than 0.05 were considered statistically significant.

Results

This study was completed with 28 rats, each group containing seven. The time interval for the study was the same as indicated in *Methods* section (Fig. 1).

Table 1 represents TNF-α and IL-6 values and histological scores of the pulmonary tissue. Intergroup analysis revealed no statistically significant difference regarding TNF-α and IL-6 values neither in the 1st, nor in the 3rd hours of reperfusion.

Statistical analysis of the pulmonary injury histological scores was made using median values of the scores obtained from 6 microscopic areas examined. There was statistically significant difference among the groups regarding pulmonary injury scores ($p=0.001$). There was observed diffuse injury (score 4) in all the specimens of the Group 2. Histological scores obtained from the Group 2 were significantly different from the Groups 1, 3 and 4 with *p*-values of 0.001 for each comparison. Moreover, Group 1 scores were found to be significantly different from the Groups 3 and 4 with *p*-values of 0.001 and 0.011, respectively. No significant difference was observed between the Groups 3 and 4.

In the microscopical examination; samples from the Group 1 demonstrated normal alveolar sequence, perialveolar structures and cells, and normal interstitial areas (Fig. 2).

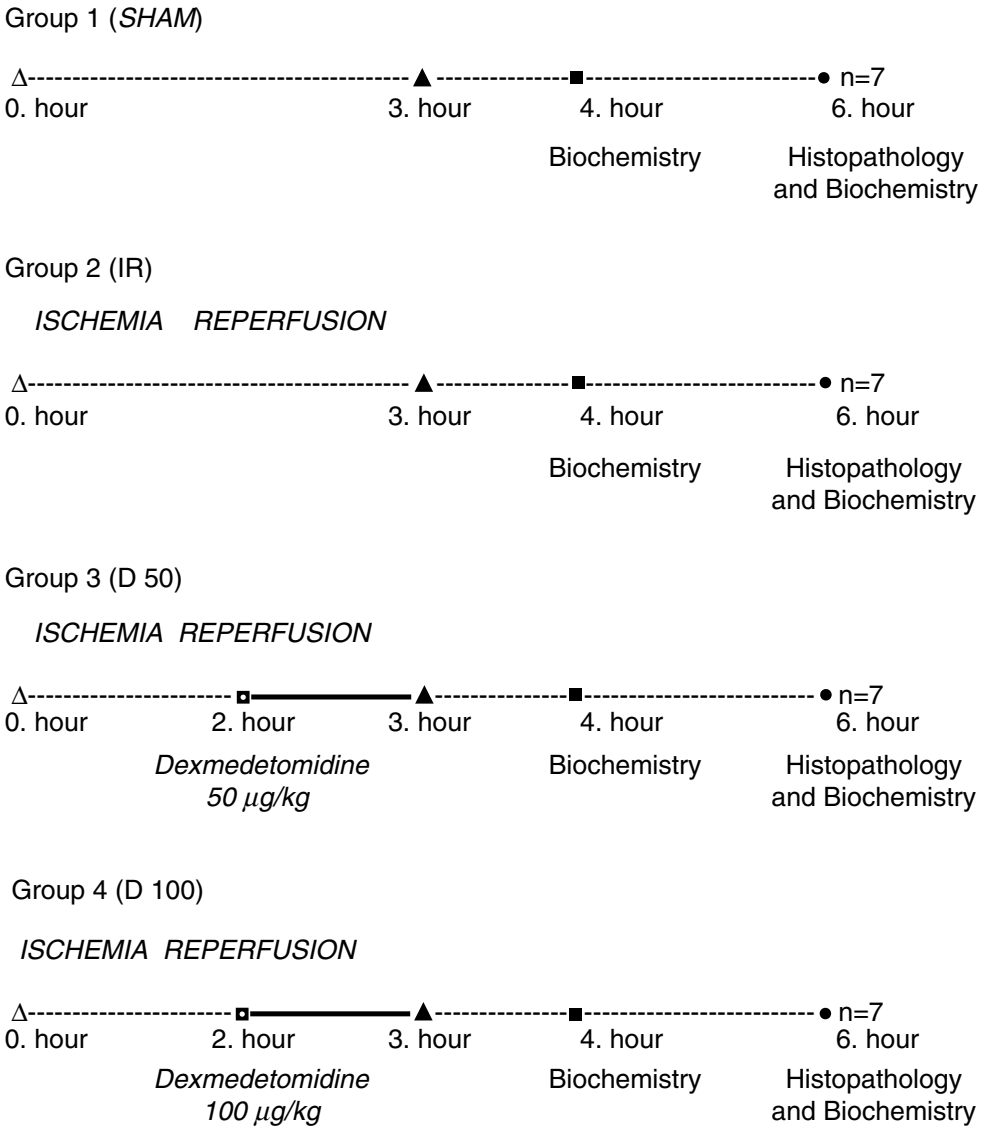

Figure 1 Schematic representation of the study protocol.

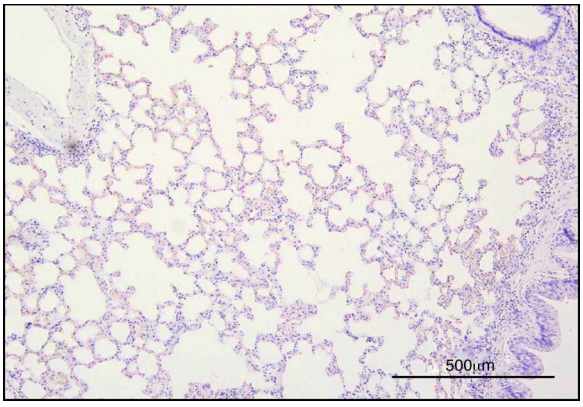

Figure 2 Group 1, normal structure of ventilated pulmonary tissue.

Samples from the Group 2 showed interstitial and intraalveolar neutrophile infiltration, hemorrhage, interalveolar septal thickening, interstitial edema, diffuse emphysematous areas and congestion. Large magnification revealed mostly atelectatic areas and areas with capillary stasis with decreased ventilation, collapsed alveoli, nonfunctional parenchymal areas, dense parenchymal neutrophile and macrophage infiltration in these regions, diffuse intraalveolar hemorrhage in the capillary stasis areas and patchy fibrosis areas together with sparse normally ventilated fields (Figs. 3 and 4). Samples from the Group 3 demonstrated diffuse interstitial neutrophile infiltration; interalveolar septal thickening, atelectasis, congestion, hemorrhage and emphysema less than in the Group 2. Normal pulmonary tissue was observed at the neighboring areas, despite mild parenchymal enlargement and neutrophile infiltration. Some regions revealed normal pulmonary tissue together with intense parenchymal hemorrhage, emphysematous areas and peribronchial infiltrations (Fig. 5). Samples from the Group

Table 1 TNF-α and IL-6 values and histological scores.

	Group 1 (*SHAM*) *n* = 7	Group 2 (IR) *n* = 7	Group 3 (D 50) *n* = 7	Group 4 (D 100) *n* = 7	*p*
TNF-α (pg/mL)					
Reperfusion 1 h	9.40 (7.40–11.50)	10.10 (9.10–25.30)	9.70 (8.30–10.90)	9.70 (7.70–10.60)	0.55
Reperfusion 3 h	9.30 (8.20–10.90)	9.80 (9.30–22.90)	10.20 (8.70–11.80)	9.00 (8.90–12.10)	0.26
IL-6 (pg/mL)					
Reperfusion 1 h	27.10 (21.60–41.30)	17.30 (13.20–52.60)	19.00 (15.80–58.00)	25.20 (20.00–48.90)	0.11
Reperfusion 3 h	32.70 (21.60–64.70)	61.20 (17.40–120.30)	24.40 (14.00–91.80)	31.80 (21.40–47.70)	0.83
Histological score	0.5[b] (0.0–1.0)	4.0[a] (4.0–4.0)	2.5 (2.0–3.0)	2.0 (0.5–3.5)	0.001

[a] Significant difference in the Group 2 compared with the Groups 1, 3 and 4, $p < 0.05$.
[b] Significant difference in the Group 1 compared with the Groups 3 and 4, $p < 0.05$.
The values are represented in median (minimum–maximum).

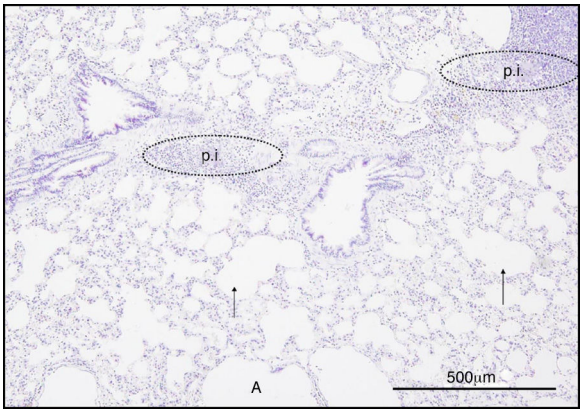

Figure 3 Group 2, alveolar structure has lost its pattern (↑), emphysematous changes (A), parenchymal inflammatory cell infiltration (Pİ).

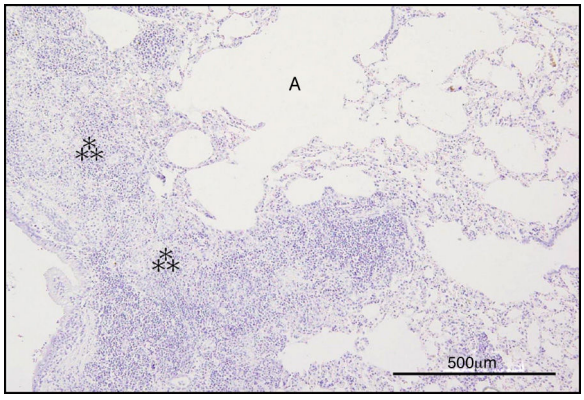

Figure 4 Group 2, dense neutrophile infiltration, parenchymal enlargement, non-ventilated pulmonary areas (⁂) and atelectatic areas (**A**).

4 demonstrated mild interstitial neutrophile infiltration, interalveolar septal thickening, atelectasis, congestion and hemorrhage to a much lesser extent than in the Group 2. Some regions revealed completely normal pulmonary tissue (Fig. 6).

Discussion

The main outcome of the study was that, dexmedetomidine decreased histological injury scores related to IR in rats experiencing ischemia and reperfusion, that was generated by extremity tourniquet application. Although there were not observed differences among the groups as regards blood inflammatory mediators TNF-α and IL-6, there were significant difference regarding histological appearances of the tissues. Histological scores of the Group 2 were found to be high, indicating the effects of the IR injury to the pulmonary

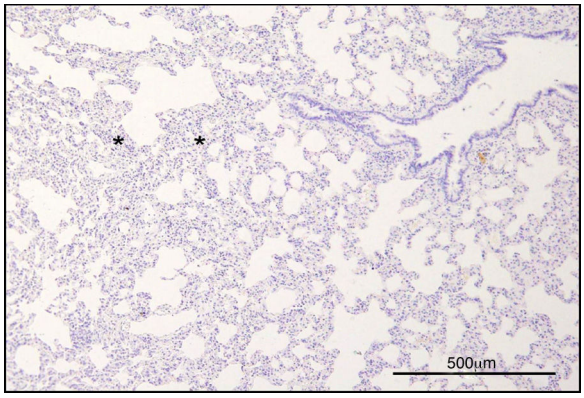

Figure 5 Group 3, mild parenchymal enlargement and neutrophile infiltration (*) together with normal neighboring pulmonary tissue structure.

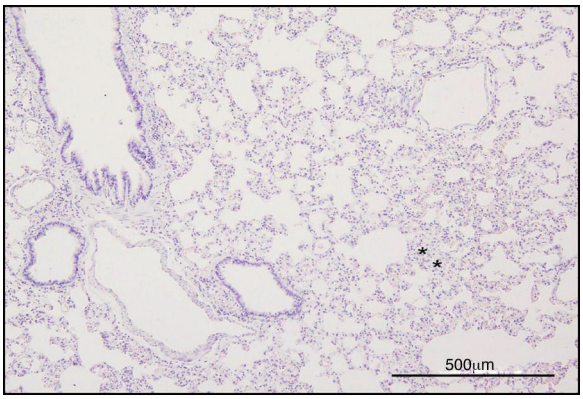

Figure 6 Group 4, mild inflammatory infiltration and thickened interalveolar septum (*) together with normal pulmonary tissue.

tissue. Groups 3 and 4 demonstrated lower injury scores, indicating protective effect of dexmedetomidine against IRI.

Although some authors offer multiple ligation method instead of tourniquet application because of the concern of venous and lymphatic obstruction, muscle, nerve damage after prolonged mechanical compression,[17] tourniquet method is non-invasive and seems to be more practical in the clinical application.[7,18]

Different ischemia and reperfusion times had been used for IR creation in the literature. We had taken into account resistance of the tissue against ischemia in our study. For instance, prominent morphological changes in the muscle tissue appear after 2 h of ischemia and so, the studies dealing with muscle IRI had used long ischemia periods.[19,20] Important correlation between ischemia period and ischemic injury was found.[21] Taking into account that there had been demonstrated irreversible histological injury[20] and diffuse neutrophile infiltration[18] in the muscle tissue after 3 h of ischemia period in the studies dealing with IRI in the muscle, we had chosen our ischemia period to be 3 h in the study.

Reperfusion period also was found to be an important factor in the formation of local and distant effects of IR.[2,7,19] Yasin et al.[7] had used different reperfusion times after 3 h ischemia and found positive correlation between reperfusion period and distant organ dysfunctions. They had also demonstrated histological changes after the 3 h of reperfusion, that were not apparent in the first 2 h. On account of this we had chosen the reperfusion time to be 3 h. Prominent histological changes, as diffuse neutrophile infiltration, alveolar sequence distortion, edema, in the pulmonary tissue of the IR group had supported our choice. These findings were coherent with the studies that used the same time periods.[7,18]

TNF-α was shown to play an important role in the pathogenesis of Systemic Inflammatory Response Syndrome (SIRS) and Multiple Organ Failure (MOF).[5,22,23] Similar mechanisms were suggested in the local and distant effects of IRI and studies conducted had shown TNF-α to play role in the organ damage pathogenesis.[3,7] Similarly, IL-6 also was shown to play role in complex inflammatory reaction related to trauma, shock and infection.[24] Positive correlation was demonstrated between plasma IL-6 concentrations and magnitude of soft tissue damage.[24] IL-6 levels were shown to increase in correlation with TNF-α in the studies dealing with lower extremity IR models.[5,6] Yasin et al.[7] had suggested that IR related inflammatory response can be shown with serum TNF-α and IL-6 levels and that there is positive correlation between this increase and distant organ injuries. They had evaluated blood TNF-α and IL-6 levels at the 1st, 2nd and 3rd hours of reperfusion after 3-hour ischemia period. TNF-α was found to increase significantly at the end of the 1st hour and return to control values at the 2nd hour; whereas IL-6 was found to increase progressively after the 1st hour of reperfusion with peak at the end of the 3rd hour. Hence, we had evaluated blood TNF-α and IL-6 levels both at the end of the 1st and 3rd hours.

There have been conducted many clinical and experimental studies with dexmedetomidine as it shows analgesic, anxiolytic and sedative properties alltogether.[25,26] Moreover, it has been shown that dexmedetomidine possesses antiinflammatory properties in the studies investigating its effects in ischemic and toxic inflammatory models.[11] Taniguchi et al.[11] have demonstrated that dexmedetomidine alleviates lung injury and decreases mortality rates by decreasing TNF-α and IL-6 levels and neutrophile infiltration in the alveolar walls in the experimental endotoxemic septic shock model. Shen et al.[27] have investigated TNF-α and IL-6 levels in lung injury caused by experimental intestinal IRI model and demonstrated decreased production of these cytokines in pulmonary tissue after dexmedetomidine administration.

Dexmedetomidine has been used via intraperitoneal route before[28] or during[12–14] IR in rat IR models. Although dexmedetomidine's protective effects had been shown regardless of its time of administration, there are no studies in the literature comparing its application periods. Furthermore, some studies investigating the effects of intraperitoneally administered dexmedetomidine have shown that, IR periods were not longer than the elimination time of dexmedetomidine.[13,28] Taking into consideration that the main culprit in the formation of lung injury is reperfusion process, and that TNF-α levels begin to rise near the end of the ischemia with peak levels at the 1st hour of reperfusion,[7] it was relevant to apply dexmedetomidine 1 hour before the reperfusion.

We have not come across certain dose intervals of dexmedetomidine for its antiinflammatory effects in the literature. The dose for dexmedetomidine, applied intraperitoneally, was decided to be 100 μg/kg, a highest dose safely applied in the current literature,[16,28] and the second dose was decided to be 50 μg/kg, to evaluate its possible dose dependent effects.

Despite similar IR periods in the studies regarding rat pulmonary IRI after extremity tourniquet application, different results regarding TNF-α levels have been observed.[5,18,29] Seekamp et al.[5] have demonstrated that TNF-α levels were not detectable in the blood throughout the 4-hour ischemia period, but started to rise at the 1st hour of reperfusion with decline after the 2nd hour. In addition, IL-6 levels started to rise at the 30th minute with peak at the end of the 4th hour. Yassin et al.[7] have stated that, TNF-α and IL-6 levels reach their peak levels at the 1st and 3rd hours of reperfusion, respectively; TNF-α levels drop below detectable levels after the 2nd hour of reperfusion and

IL-6 reach detectable levels in plasma from the 1st hour of reperfusion.

Duru et al.,[18] Harkin et al.,[30] Gaines et al.[31] have used similar IR models and time periods; despite they have demonstrated histopathological changes due to IR injury, they could not observe changes in TNF-α levels. Similarly, Welbourn et al.[29] could not observe TNF-α level changes after reperfusion; they have concluded that TNF-α had role in the IRI pathogenesis as histopathological changes decreased with the application of anti-TNF serum. We have also found no differences in the TNF-α and IL-6 levels in the dexmedetomidine applied groups, compared to SHAM group, despite significant histopathological differences. This condition may be attributed to insufficient number of subjects. Duru et al.[18] have stated that, the reason they could not have demonstrated cytokine level changes was that they might have spared TNF-α peak levels, as they obtained blood samples at the end of the 2nd hour of reperfusion. Gaines et al.[31] attributed this to the blood sample insufficiency. Welbourn et al.[29] have proposed that TNF-α can stay in the tissue after production in the pulmonary macrophages and so could not always be detected in the blood; it can mediate pulmonary tissue injury activating endothelium locally.

IRI generated by the tourniquet model was histopathologically demonstrated in this study. The changes in the IR group were significant compared to the SHAM and both dexmedetomidine groups, and this verified that the model was appropriately conducted. Significant differences in the findings in the dexmedetomidine groups compared to the IR group was interpreted as that dexmedetomidine had decreased pulmonary injury.

Although histopathological scores between the groups with dexmedetomidine 50 and 100 μg/kg were not significantly different, some normal pulmonary tissue areas in the microscopical examination in the D 100 group suggested that the drug might have acted in dose dependent manner. Studies with larger sample sizes with different doses, administration time and routes may be conducted to evaluate this effect.

No limitations for the study were encountered.

In conclusion, in our experimental study of lower extremity tourniquet induced IR model, dexmedetomidine was effective in preventing the IR induced lung injury. Histopathological and IL-6 level differences between the two groups with different doses of dexmedetomidine, although not statistically significant, suggests to conduct studies with larger sample sizes to evaluate the effects of different doses.

Implication statement

This experimental study demonstrates the ability of dexmedetomidine to reduce experimental ischemia–reperfusion related injury in rats. Controlled trials can be conducted in human to observe the clinical significance of this effect.

Conflicts of interest

The authors declare no conflicts of interest.

References

1. Cerra FB, Lajos TZ, Montes M, et al. Hemorrhagic infarction: a reperfusion injury following prolonged myocardial ischemic anoxia. Surgery. 1975;78:95–104.
2. Welbourn CR, Goldman G, Paterson IS, et al. Pathophysiology of ischaemia reperfusion injury: central role of the neutrophil. Br J Surg. 1991;78:651–5.
3. Grace PA. Ischaemia–reperfusion injury. Br J Surg. 1994;81:637–47.
4. Vilcek J. The cytokines: an overview. In: Thomson AW, editor. The Cytokine Handbook, vol. 1, 4th ed. London: Elsevier Science Academic Press; 2003. p. 3–18.
5. Seekamp A, Mulligan MS, Till GO, et al. Requirements for tumor necrosis factor-alpha and interleukin-1 in limb ischemia/reperfusion injury and associated lung injury. Am J Pathol. 1993;143:453–63.
6. Seekamp A, Till GO, Mulligan MS, et al. Role of selectins in local and remote tissue injury following ischemia and reperfusion. Am J Pathol. 1994;144:592–8.
7. Yassin MM, Barros D'Sa AA, Parks G, et al. Lower limb ischemia–reperfusion injury triggers a systemic inflammatory response and multiple organ dysfunction. World J Surg. 2002;26:115–21.
8. Maes M, Lin A, Kenis G, et al. The effects of noradrenaline and alpha-2 adrenoceptor agents on the production of monocytic products. Psychiatry Res. 2000;96:245–53.
9. Venn RM, Bryant A, Hall GM, et al. Preliminary UK experience of dexmedetomidine a novel agent for postoperative sedation in the intensive care unit. Anaesthesia. 1999;54:1136–42.
10. Bhana N, Goa KL, McClellan KJ. Dexmedetomidine. Drugs. 2000;59:263–70.
11. Taniguchi T, Kidani Y, Kanakura H, et al. Effects of dexmedetomidine on mortality rate and inflammatory responses to endotoxin-induced shock in rats. Crit Care Med. 2004;32:1322–6.
12. Jolkkonen J, Puurunen K, Koistinaho J, et al. Neuroprotection by the alpha2-adrenoceptor agonist, dexmedetomidine, in rat focal cerebral ischemia. Eur J Pharmacol. 1999;372:31–6.
13. Eser O, Fidan H, Sahin O, et al. The influence of dexmedetomidine on ischemic rat hippocampus. Brain Res. 2008;1218:250–6.
14. Yagmurdur H, Ozcan N, Dokumaci F, et al. Dexmedetomidine reduces the ischemia–reperfusion injury markers during upper extremity surgery with tourniquet. J Hand Surg Am. 2008;33:941–7.
15. Yang CL, Tsai PS, Huang CJ. Effects of dexmedetomidine on regulating pulmonary inflammation in a rat model of ventilator-induced lung injury. Acta Anaesthesiol Taiwan. 2008;46:151–9.
16. Kocoglu H, Ozturk H, Ozturk H, et al. Effect of dexmedetomidine on ischemia–reperfusion injury in rat kidney: a histopathologic study. Ren Fail. 2009;31:70–4.
17. Tassiopoulos AP, Carlin RE, Gao Y, et al. Role of nitric oxide and tumor necrosis factor on lung injury caused by ischemia/reperfusion of the lower extremities. J Vasc Surg. 1997;26:647–56.
18. Duru S, Koca U, Öztekin S, et al. Antithrombin III pretreatment reduces neutrophil recruitment into the lung and skeletal muscle tissues in the rat model of bilateral lower limb and reperfusion: a pilot study. Acta Anaesthesiol Scand. 2005;49:1142–8.
19. Khalil AA, Aziz FA, Hall JC. Reperfusion injury. Plast Reconstr Surg. 2006;117:1024–33.
20. Blaisdell FW. The pathophysiology of skeletal muscle ischemia and the reperfusion syndrome: a review. Cardiovasc Surg. 2002;10:620–30.

21. Petrasek PF, Homer-Vanniasinkam S, Walker PM. Determinants of ischemic injury to skeletal muscle. J Vasc Surg. 1994;19:623–31.
22. Seal JB, Gewertz BL. Vascular dysfunction in ischemia–reperfusion injury. Ann Vasc Surg. 2005;19:572–84.
23. Yao YM, Sheng ZY, Yu Y, et al. The potential etiologic role of tumor necrosis factor in mediating multiple organ dysfunction in rats following intestinal ischemia–reperfusion injury. Resuscitation. 1995;29:157–68.
24. Roumen RM, Hendriks T, van der Ven-Jonge KJ, et al. Cytokine patterns in patients after major vascular surgery, hemorrhagic shock, and severe blunt trauma. Relation with subsequent adult respiratory distress syndrome and multiple organ failure. Ann Surg. 1993;218:769–76.
25. Koroglu A, Demirbilek S, Teksan H, et al. Sedative, haemodynamic and respiratory effects of dexmedetomidine in children undergoing magnetic resonance imaging examination: preliminary results. Br J Anaesth. 2005;94:821–4.
26. Arain SR, Ruehlow RM, Uhrich TD, et al. The efficacy of dexmedetomidine versus morphine for postoperative analgesia after major inpatient surgery. Anesth Analg. 2004;98:153–8.
27. Shen J, Fu G, Jiang L, et al. Effect of dexmedetomidine pretreatment on lung injury following intestinal ischemia–reperfusion. Exp Ther Med. 2013;6:1359–64.
28. Engelhard K, Werner C, Eberspacher E, et al. The effect of the alpha 2-agonist dexmedetomidine and the N-methyl-D-aspartate antagonist S(+)-ketamine on the expression of apoptosis-regulating proteins after incomplete cerebral ischemia and reperfusion in rats. Anesth Analg. 2003;96:524–31.
29. Welbourn R, Goldman G, O'Riordain M, et al. Role for tumor necrosis factor as mediator of lung injury following lower torso ischemia. J Appl Physiol. 1991;70:2645–9.
30. Harkin DW, Barros D'Sa AA, McCallion K, et al. Ischemic preconditioning before lower limb ischemia–reperfusion protects against acute lung injury. J Vasc Surg. 2002;35:1264–73.
31. Gaines GC, Welborn MB 3rd, Moldawer LL, et al. Attenuation of skeletal muscle ischemia/reperfusion injury by inhibition of tumor necrosis factor. J Vasc Surg. 1999;29:370–6.