MARMARA
MEDICAL JOURNAL

Original Article

https://dergipark.org.tr/tr/pub/marumj

Morphological and biochemical evaluation of effects of *Myrtus communis* L. extract on heart and aorta in high fat-diet-induced obese rats

Nagehan OZYILMAZ YAY[1,2], Nurdan BULBUL AYCI[1,2], Rumeysa KELES KAYA[3], Ali SEN[4], Goksel SENER[5], Feriha ERCAN[2]

[1] Department of Histology and Embryology, Institute of Health Sciences, Marmara University, Istanbul, Turkey
[2] Department of Histology and Embryology, School of Medicine, Marmara University, Istanbul, Turkey
[3] Department of Pharmacology, School of Pharmacy, Marmara University, Istanbul, Turkey
[4] Department of Pharmacognosy, School of Pharmacy, Marmara University, Istanbul, Turkey
[5] Department of Pharmacology, Faculty of Pharmacy, Fenerbahce University, Istanbul, Turkey

Corresponding Author: Feriha ERCAN
E-mail: eferiha@hotmail.com, fercan@marmara.edu.tr

Submitted: 21.10.2022 **Accepted:** 26.01.2023

ABSTRACT

Objective: The purpose of this study was to examine the protective effects of *Myrtus communis L.* (MC) extract on high fat-diet (HFD) induced heart and aorta damage by evaluating oxidative stress and the endothelial nitric oxide system (eNOS).

Materials and Methods: Wistar albino male rats were divided into 3 groups (n=7) as control, HFD, and HFD+MC. Rats in HFD and HFD+MC groups were HFD fed for 16 weeks and in the last 4 weeks saline or MC (100 mg/kg) was administered orally (5 days/week). Triglyceride, cholesterol, and high-density lipoprotein (HDL) were estimated in blood serum. Tissue oxidative stress and inflammatory parameters were evaluated biochemically. Tissue morphologies, eNOS, inducible NOS (iNOS), and NADPH oxidase-2 (NOX-2)-immunopositive and apoptotic cells were evaluated histologically.

Results: Altered serum lipid profiles, degenerated heart, and aorta morphology, increased malondialdehyde, 8-hydroxy-2-deoxyguanosine, tumor necrosis factor-alpha, monocyte chemoattractant protein-1 and myeloperoxidase levels, and iNOS, NOX-2 immunopositive and apoptotic cells, decreased NO levels, eNOS-immunopositive cells in both tissues were observed in HFD group. All these parameters improved in the HFD+MC group.

Conclusion: This study revealed that HFD-induced obesity increased iNOS activation and oxidative stress in the cardiac and aortic tissues of the rats. MC improved oxidant/antioxidant balance and prevented heart and aorta damage via eNOS involvement.

Keywords: High-fat diet, Obesity, *Myrtus communis* L. extract, Heart, Aorta

1. INTRODUCTION

Based on the World Health Organization (WHO) definition, obesity is identified as excessive fat deposition that poses a risk to health. Approximately 1.9 billion people globally are overweight (Body mass index-MI≥25 kg/m2) or obese (BMI≥30 kg/m2). In many Western countries, one in every two people is considered to be either overweight or obese [1, 2]. Studies have shown that obesity can be caused by genetics, diet, environment, living conditions, and other factors [3]. It has been observed that cardiovascular diseases, atherosclerosis, Type 2 diabetes, cancer, sleep disorder, osteoarthritis, and some other diseases can develop as a result of obesity [4]. One of the main factors leading to obesity is consuming foods with high fat [5]. Oxidative stress is defined as reactive oxygen species (ROS) that cause lipid peroxidation and cellular damage in the organism due to the deterioration of the balance between oxidant and anti-oxidant systems in favor of oxidant systems [6]. It has been shown that oxidative stress induced by obesity is shown as the main mechanism responsible for obesity-related cardiovascular risk [7].

Numerous studies have shown that a high-fat diet leads to an increase in nicotinamide adenine dinucleotide phosphate (NADPH) oxidase-2 (NOX-2) and oxidative stress, which provides the production of free oxygen radicals [8]. Excessive amounts of ROS resulting from increased NOX-2 activation in obesity lead to endothelial dysfunction and ultimately to cardiovascular complications [9, 10]. It has been observed that increased ROS species as a result of a high-fat diet (HFD) lead to an increase in the synthesis of vascular constrictive factors while, reducing the release of relaxant factors such as nitric oxide (NO), which leads to endothelial dysfunction in the coronary arteries. However, antioxidant treatment applied in obese animals

How to cite this article: Yay Ozyilmaz N, Ayci Bulbul N, Kaya Keles R, Sen A, Sener G, Ercan F. Morphological and biochemical evaluation of effects of *Myrtus communis* L. extract on heart and aorta in high fat-diet-induced obese rats. Marmara Med J 2023; 36(2): 162-170. doi: 10.5472/marumj.1302544

© 2023 Marmara University Press, All Rights Reserved
ISSN: 1309-9469

http://doi.org/10.5472/marumj.1302544
Marmara Med J 2023;36(2): 162-170

prevented changes in NO metabolism and improved coronary vascular response [10]. The development of hypertension and atherosclerosis is the most common cardiovascular complications that develop after endothelial dysfunction in obese and diabetic individuals [11]. Increased oxidative stress in the vessel wall stimulates the development of inflammation, enhancing the expression of pro-inflammatory cytokines such as tumor necrosis factor-alpha (TNF-α), interleukin 6 (IL-6), and chemoattractant molecules such as monocyte chemoattractant protein-1 (MCP-1) [12, 13]. This results monocyte migration to the endothelial region and monocytes become active secretory macrophages. Endothelial dysfunction in obesity, a decrease in endothelial nitric oxide synthase (eNOS) activity and NO levels, also increase in inducible NOS (iNOS) activity, and consequently in peroxynitrite formation are observed [14]. In this case, vascular smooth muscle tissue deterioration occurs.

Herbal medicine including essential oils and flavonoids via antioxidative and anti-inflammatory activity may have many beneficial effects for many diseases associated with obesity, including cardiovascular failures [7, 15]. *Myrtus communis* L. subsp. communis (MC) is an aromatic plant commonly found in the Mediterranean region and the Middle East [16]. It is known to have anti-inflammatory, antihypertensive, antitussive, antiallergic, antiemetic, and diuretic effects. It has beneficial effects in experimental diabetes and hyperlipidemia [16, 17, 18]. Its ability to suppress inflammatory processes and scavenge oxygen-free radicals suggests that it is suitable for improving dysfunction in obesity [19]. Recent studies have shown that MC extract has antioxidative and antiinflammatory effects on experimental renovascular hypertension and obesity-induced renal and bladder damage [17, 20].

Based on the studies, we purposed to study the possible protective effects of MC on HFD-induced heart and aorta damage via biochemical and histological analysis. Cholesterol, triglyceride, and high-density lipoprotein (HDL) were measured in blood serum. Oxidative parameters as malondialdehyde (MDA), NO, 8-hydroxy-2-deoxyguanosine (8-OhdG), and inflammatory parameters as MCP-1, TNF-α, and myeloperoxidase (MPO) levels in heart and aorta tissues were measured using biochemical techniques. Cardiac and aorta morphology, apoptotic cells, eNOS, iNOS, and NOX-2-positive cells were evaluated using histological and immunohistochemical methods.

2. MATERIALS and METHODS

Experimental animals

Wistar albino male rats (2-3 month-old) were kept individually in a light – and temperature-controlled room on a 12-h/12-h light–dark cycle and fed a standard pellet lab chow. All experimental studies were allowed (23.2019.mar) by the Animal Care and Use Committee of the Marmara University School of Medicine.

Plant materials and preparation of MC extract

The plant samples used in this study were collected from the city of Manisa, (Turgutlu region). The samples were identified by a botanist in Marmara University, Faculty of Pharmacy. Voucher specimens were deposited in the Herbarium of Marmara University, Faculty of Pharmacy (MARE: 13006). Briefly, leaves of MC (100 g) were dried in the shade at room temperature. The dried powdered leaves were extracted with 96% ethanol using the Soxhlet device. After filtration, the extract was concentrated to dryness using a rotary evaporator. The powder MC extract obtained with a yield of 28.56% was kept in a dark glass bottle in a refrigerator (4°C) until use [21].

Experimental groups

Rats were divided into 3 experimental groups (n=7, in each group): 1) Control (C), 2) HFD, and 3) HFD+MC groups. A standard diet was applied to the C group. Rats in HFD and the HFD+MC groups were fed a high-fat diet for 16 weeks. MC extract (100 mg/kg/day, dissolved in saline) was given orally by gavage five days a week for the last month of the experiment to the rats in the HFD+MC group [21]. The weight of rats was measured weekly during the experiment. Rats were decapitated under ether anesthesia and blood was obtained for evaluation of lipid profiles. Heart and aorta samples were removed for histological, immunohistochemical, and biochemical evaluation.

Measurement of triglyceride, cholesterol, and HDL levels in blood serum

The serum concentration of triglyceride, cholesterol, and HDL levels was determined using commercial enzyme-linked immunosorbent assay (ELISA) kits (Biont Rat ELISA kit, Shanghai, China). The results were given as mmol/L for total cholesterol and ng/ml for triglyceride and HDL

Measurement of MDA, NO, 8-OHdG, MCP-1, TNF-α and MPO levels in the heart and aortic tissues

At the end of the experiment, heart and aortic tissue samples were collected and the levels of MDA, 8-OHdG, TNF-α, MCP-1, and MPO were measured using the ELISA method. The tissues were removed after decapitation, kept at – 20 °C, and were brought to a temperature in the range of 2-8 °C before analyzing. A small amount of tissue samples was placed in a tube, phosphate-buffered saline (PBS) (pH 7.4) was added to 10% homogenate, and the samples were centrifuged at 3000 rpm for about 20 minutes with the help of a homogenizer. Then, the supernatants were collected and the commercial ELISA kit procedures (Bioassay Technology Laboratory, Shanghai, China) were applied. The absorbances were measured with the help of an ELISA Reader at 450 nm and the absorbance-concentration graph was drawn. NO levels were evaluated by measuring levels of accumulated total nitrate in the tissue samples using a commercial total nitric oxide assay kit (ENZO Life Sciences, Lausen, Switzerland). A standard curve was generated ranging from 0 to 100 µM using nitrate as standard and the total nitrate concentration was measured as µM for each sample via the calibration curve.

Light microscopic preparation and histopathological scoring

Tissue samples from the heart and aorta were removed and fixed in a 10% formalin solution. Thereafter, tissue samples were dehydrated with increasing alcohol series, cleared using xylene, and embedded in paraffin at room temperature. Paraffin sections (4 µm-thick) of the heart and aorta were stained with hematoxylin and eosin (H&E). Five similar areas in each section were evaluated in the experimental groups. H&E stained heart sections were scored semiquantitatively by a scale ranging from 0 to 3 (0, none; 1, mild; 2, moderate; and 3, severe) for each criterion including inflammatory cell infiltration and disruption of cardiomyocytes [22]. The aorta tissue damage was scored semiquantitatively from 0 to 4 according to the disorganization of the medial layer elastic network (0, none; 1, mild, only external elastic lamina disrupted; 2, moderate, external elastic lamina and outer medial layers degraded; 3, high, external elastic lamina and medial elastic layers breakage; 4, severe, all elastic layers breakage, and aortic rupture) [23]. The maximum score was 6 for heart sections and 4 for aortic sections.

eNOS, iNOS, and NOX-2 immunohistochemistry

Antigen retrieval was applied by microwaving the slides in citrate buffer (20 min) to the deparaffinized sections. Slides were cooled at room temperature (20 min). Endogenous peroxidase activity was blocked with 3% H_2O_2 (10 min), and then slides were washed in PBS. Blocking reagent (Histostain plus kit-Thermo Scientific Massachusetts, USA) was added to each slide and incubated (20 min) at room temperature in a humid chamber. Tissue sections were incubated overnight at 4 °C with primary rabbit polyclonal eNOS (1:300), iNOS (1:50), and NOX-2 (1:200) antibodies. The sections were washed in PBS three times (5 min) and then incubated in secondary biotinylated goat anti-rabbit antibodies (Novus, Abingdon, UK) at room temperature (30 min). After washing with PBS, streptavidin peroxidase-labeled reagent (Histostain-plus kit, Thermo Fisher Scientific, Massachusetts, USA) was applied (30 min) at room temperature in a humid chamber. Sections were incubated with 3, 3-diaminobenzidine tetrahydrochloride dihydrate (DAB) (ScyTek Laboratories Inc., Logan, UT, USA), and then slides were counterstained with Mayer's hematoxylin. After the dehydration procedure, they were covered with entellan. In each section, 5 similar areas were photographed at 40x objective of the light microscope. Staining intensity was evaluated by the Image J software (version 1.52a, Wayne Rasband, National Institutes of Health, USA). Immunohistochemical staining confirmation was performed using a negative control staining that was processed without primary antibodies.

Terminal transferase-mediated dUTP-biotin Nick end Labeling Method

The apoptotic cells were evaluated by terminal transferase-mediated dUTP-biotin Nick end Labeling (TUNEL) according to the manufacturer's manual (ApopTag Plus, In Situ Apoptosis Detection Kit, S7101, Millipore, Massachusetts, USA). The procedure was as follows: every fifth paraffine section (a total of five sections from each animal) was incubated with proteinase K (5 min), washed with distilled water, and incubated with 3% H_2O_2 in PBS (5 min). The sections were then washed with PBS, put in the equilibrium buffer (30 min), and incubated in recombinant terminal transferase TdT enzyme at 37 °C (1 h). The sections were agitated in washing buffer (15 s), washed in PBS, put into anti-digoxigenin conjugate (30 min), and then washed with PBS. DAB was applied (5 min) and washed with distilled water, stained with Mayer's hematoxylin. After the dehydration procedure, they were covered with entellan (Merck, Darmstadt, Germany). In each section, five similar areas were evaluated at the 40x objective of the light microscope.

All light microscopic sections were observed and photographed with the digital camera (Olympus C-5060, Tokyo, Japan) of a photomicroscope (Olympus BX51, Tokyo, Japan).

Statistical Analysis

Data were analyzed using one-way analysis of variance (ANOVA). Differences between groups were determined with Tukey's multiple comparisons test, and the data were expressed as mean ± standard error of the mean (SEM). The significance of differences was taken at the level of $p < 0.05$. Calculations were performed using the Instant statistical analysis package (Prism 9.0 GraphPad Software, San Diego, CA, USA).

3. RESULTS

Body weight

The body weight of rats was not significantly different in the first week of the experiments among the experimental groups (268.40 ±3.71 g in the C group, 275.8 ± 4.58 g in the HFD group, and 260.6 ± 3.58 g in the HFD+MC group). At the end of 16 weeks, the rats in the HFD group showed the greatest increase in body weight. The body weight of rats in the HFD group (409.3 ± 4.8 g; $p<0.001$) was significantly increased compared to the C group (280.23 ± 4.20 g) and decreased in the HFD+MC group (337.3 ± 2.34 g: $p<0.001$) compared to the HFD group at the end of the experiment. The body weight of rats was not significantly different on the 16th week in the C and HFD+MC groups.

Triglyceride, cholesterol and HDL values

Serum triglyceride level was significantly increased in the HFD group ($p<0.001$) compared to the C and HFD+MC groups, while there was a significant decrease in the HFD+MC group ($p<0.01$) compared to the HFD group. Also, cholesterol level was significantly increased in the HFD group ($p<0.001$) compared to the C and HFD+MC groups, while there was a significant decrease in the HFD+MC group ($p<0.01$). However, HDL level was significantly decreased in the HFD group compared to the C and HFD+MC groups ($p< 0.001$) and this value significantly increased in the HFD+MC group ($p<0.05$) compared to the HFD group (Figure 1).

http://doi.org/10.5472/marumj.1302544
Marmara Med J 2023;36(2): 162-170

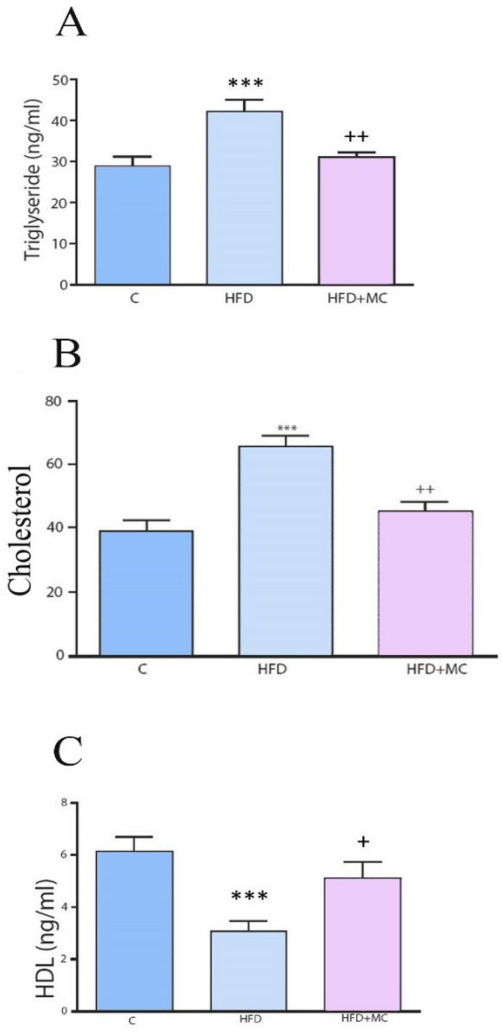

Figure 1. Triglyseride, cholesterol and HDL values in the experimental groups. *Serum triglyseride (A), cholesterol (B), HDL (C) levels are seen in the experimental groups. ***: p<0.001 compared to C group, +: p<0.05 ++: p<0.01 compared to HFD group.*

MDA, 8-OHdG, TNF-α, MCP-1, NO, and MPO levels in the heart and aorta tissues

Cardiac MDA (p<0.05), 8-OHdG (p <0.05), TNF-α (p<0.05), MCP-1 (p<0.05), and MPO (p<0.01) levels were higher and NO (p<0.05) level was lower in the HFD group than the C group. However, MDA (p<0.05), 8-OHdG (p<0.05) TNF-α (p<0.05), MCP-1 (p<0.05) and MPO (p <0.01) levels were lower and NO level (p<0.05) was higher in the HFD+MC group when compared to the HFD group in the heart homogenates.

Aortic MDA (p<0.01), 8-OHdG (p<0.01) TNF-α (p<0.01), MCP-1 (p<0.01) and MPO (p<0.01) levels elevated and NO (p<0.01) level reduced in the HFD group compared to the C group. However, MDA (p <0.01), 8-OHdG (p<0.01), TNF-α (p<0.01), MCP-1 (p<0.01), and MPO (p <0.01) levels elevated and NO level (p<0.05) reduced in the HFD+MC group compared to the HFD group in the aorta homogenates (Table I).

Histopathological findings

Normal heart morphology with regular cardiac muscle cells was seen in the C group. Myocardial fiber disorganization and degeneration of myofibrils in cardiomyocytes were seen in the HFD group. All these histopathological parameters were ameliorated in the HFD+MC group. The cardiac histopathological score was significantly increased in the HFD group (p<0.001) compared to the C group. However, the histopathological score decreased in the HFD+MC group (p<0.01) compared to the HFD group (Figure 2A-D). In the aorta sections regular intima, media, and adventitia layers were observed in the C group, thickened media layer with disorganized elastin lamella was observed in the HFD group. These structural changes were ameliorated in the HFD+MC group. The histopathological score in the aorta was significantly increased in the HFD group (p<0.01) compared to the C group. On the other hand, the histopathological score decreased in the HFD+MC group (p<0.01) compared to the HFD group (Figure 2A1-D1).

Table I. *MDA, NO, 8-OHdG, TNF-α, MCP-1 levels, and MPO activity results in the homogenization of the heart and aorta homogenates*

	MDA (ng/mg protein)	8-OHdG (ng/mg DNA)	NO (µM)	TNF-α (pg/mg protein)	MCP-1 (pg/ml)	MPO (U/g)
HEART						
C	98.48±2.72	12.72±0.65	42.45±6.89	331.6±20.66	378.3±36.10	0.458±0.04
HFD	122.05±1.26*	14.72±2.26*	38.64±10.82*	425.74±11.40*	480.8±18.48^{+}	0.556±0.03**
HFD+MC	110.42±3.32^{+}	10.27±0.65 $^{+}$	40.36±3.22^{+}	406.60±8.95^{+}	422.66±22.10^{+}	0.461±0.06^{++}
AORTA						
C	116.67±3.80	11.38±1.35	46.52±3.06	212.10±33.36	292.70±30.30	0.412±0.07
HFD	138.16±4.64**	12.08±1.01**	38.70±16.07*	353±11.55**	440.80±7.45**	0.458±0.04**
HFD+MC	122.82±2.38 $^{++}$	8.929±0.86^{+}	40.73±5.26^{++}	254.3±47.34^{+}	358.20±53.96^{++}	0.435±0.02^{++}

**: p<0.05, **: p<0.01 compared to C group, +: p<0.05 ++: p<0.01 compared to HFD group. MDA: Malondialdehyde, NO: Nitric oxid, 8-OHdG: 8- Hydroxy- 2- deoxyguanosine, TNF-α: Tumor necrosis factor-alpha, MCP-1: Monocyte chemoattractant protein-1, MPO: Myeloperoxidase, C: control, HFD: High fat-diet, HFD+MC: High fat-diet+ Myrtus communis L.*

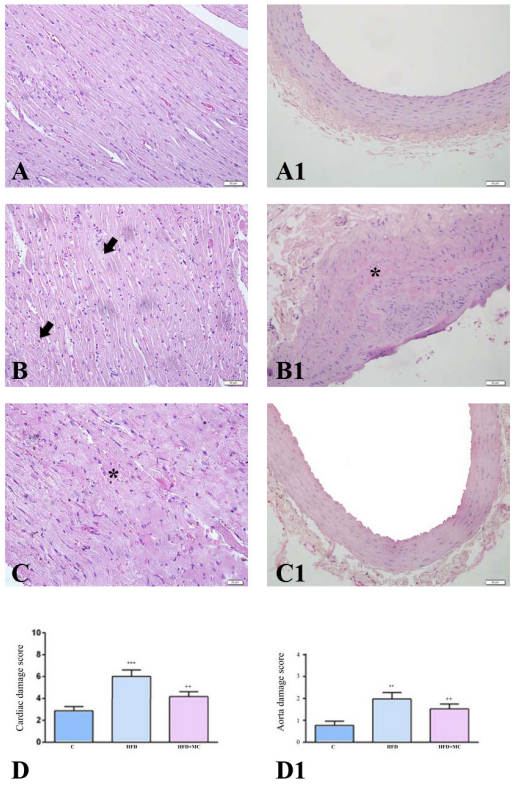

Figure 2. *Representative photomicrographs of H&E-stained cardiac (A-C) and aortic (A1-C1) tissues, cardiac (D) and aortic (D1) damage scores in the experimental groups. Normal cardiac morphology with cardiomyocytes are seen in the C (A) group. Degenerated cardiomyocytes with irregular arrangement of myofibrils (arrow) are seen in the HFD group (B). Regular cardiomyocytes (*) and decreased degenerated cardiomyocytes are seen in the HFD+MC group (C). Normal morphology of aortic wall with tunica intima, tunica media, and tunica adventitia are seen in the C (A1), HFD+MC (C1) groups. Irregular arrangement of elastin lamella and accumulation of eosinophilic material (*) in media region are seen in the HFD group (B1). **: p<0.01, ***: p<0.001 compared to the C group; ++: p<0.01 compared to the HFD group. Scale bar: 50 µm.*

eNOS, iNOS, and NOX-2 immunohistochemistry results

Brown-colored eNOS, iNOS, and NOX-2 immunopositive cells were observed in the heart and aortic tissues (Figures 3 and 4). eNOS – immunoreactivity (ir) was decreased in the heart and aorta tissues of the HFD group (p<0.05) compared to the C group. There was an increase in the eNOS-ir in the HFD+MC group (p<0.05) compared to the HFD group in both heart and aortic tissues (Figure 3A-3D, 4A-4D). However, iNOS-ir was increased in both tissues of the HFD group (p<0.01) compared to the C group. This value of heart and aortic tissues decreased in the HFD+MC group (p<0.05) when compared to the HFD group (Figure 3A1-D1, 4A1-D1). Additionally, NOX-2-ir of heart and aortic tissues increased in the HFD group (p<0.01) when compared to the C group. There was a decrease in the NOX-2-ir in the HFD+MC group (p<0.05) compared to the HFD group in both tissues (Figure 3A2-D2, 4A2-D2).

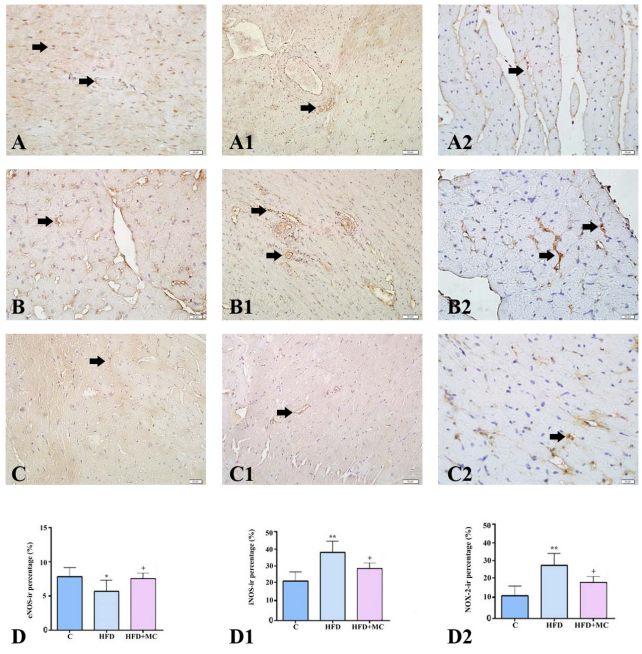

Figure 3. *Representative photomicrographs of eNOS (A-C), iNOS (A1-C1) and NOX-2 (A2-C2) immunostained cardiac tissue; percentage (%) of eNOS-ir (D), iNOS-ir (D1) and NOX-2-ir (D2) in the experimental groups. Arrow: eNOS, iNOS and NOX-2 immunopositive cells in control (A, A1, A2), HFD (B, B1, B2) and HFD+MC (C, C1 and C2) groups. *: p<0.05, **: p<0.01 compared to C group; +: p<0.05 compared to the HFD group. Scale bar: 50 µm.*

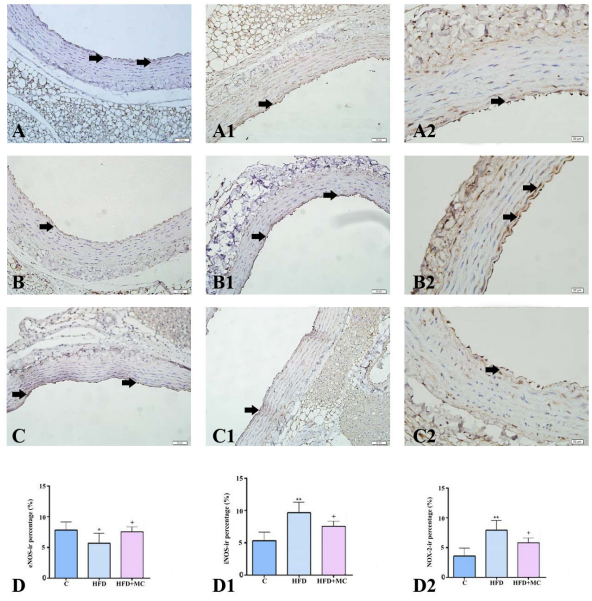

Figure 4. *Representative photomicrographs of eNOS (A-C), iNOS (A1-C1) and NOX-2 (A2-C2) immunostained aortic tissue; percentage (%) of eNOS-ir (D), iNOS-ir (D1) and NOX-2-ir (D2) in the experimental groups. Arrow: eNOS, iNOS and NOX-2 immunopositive cells in control (A, A1, A2), HFD (B, B1, B2) and HFD+MC (C, C1 and C2) groups. *: p<0.05, **: p<0.01 compared to the C group; +: p<0.05 compared to the HFD group. Scale bar: 50 µm.*

http://doi.org/10.5472/marumj.1302544
Marmara Med J 2023;36(2): 162-170

TUNEL method results

TUNEL-positive cells were seen as dark brown in color in the cardiac and aortic tissues of the experimental groups (Figure 5). However, the number of TUNEL-positive cells and apoptotic index were higher in both the cardiac and aortic tissues of the HFD group ($p<0.01$) when compared to the C group. Additionally, there was a decrease in the number of TUNEL-positive cells and apoptotic index in both the heart and aorta tissues of the HFD+MC group ($p<0.05$) when compared to the HFD group (Figure 5).

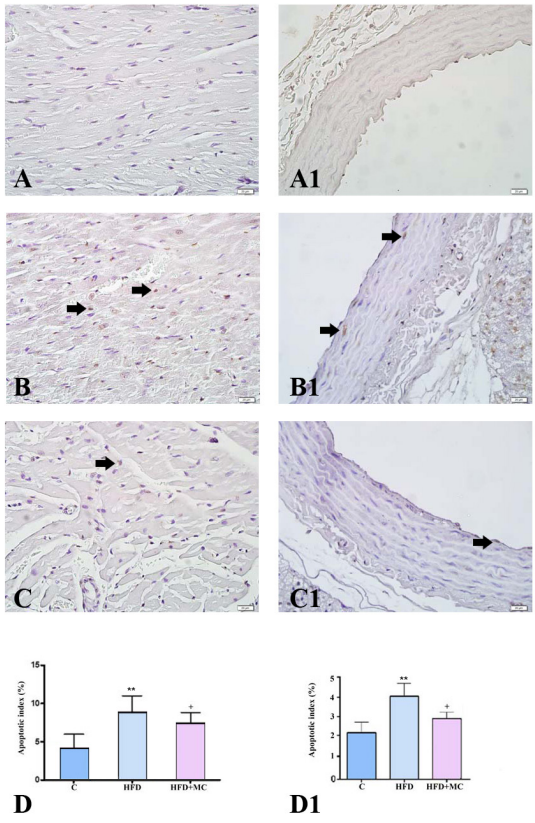

Figure 5. *Representative photomicrographs of TUNEL stained cardiac (A-C) and aortic (A1-C1) tissues and cardiac (D) and aortic (D1) apoptotic index in the experimental groups. Arrow: TUNEL positive cells in HFD (B, B1) and HFD+MC (C, C1) groups. **: $p<0.01$ compared to the C group, +: $p<0.05$ ++: $p<0.01$ compared to the HFD group. Scale bar: 20 µm.*

4. DISCUSSION

In the present study, the ameliorating effects of MC treatment on HFD-induced heart and aorta damage were evaluated by biochemical, histological, and immunohistochemical methods. This study demonstrated that HFD-induced obesity increased triglyceride, and cholesterol levels and decreased HDL levels in blood serum. Oxidative stress and inflammatory parameters including MDA and 8-OHdG levels and TNF-α, MCP-1, and MPO levels increased and NO levels decreased in the HFD group. Parallel with biochemical parameters, degenerated cardiac and aorta morphology, increased apoptotic, iNOS, and NOX-2 immunopositive cells, and decreased eNOS immunopositive cells were present in the HFD group. All these biochemical, histological, and immunohistochemical parameters improved in MC treated HFD group.

Previous animal and human studies have shown that HFD significantly increased body weight and oxidative stress has an important role in obesity and weight loss [7, 13]. For this reason, there are many studies on antioxidant treatments. It has been reported that MC extract has antiobesity effects [15, 24]. The present study showed that MC treatment reduces the body weight in HFD-induced obese rats. Also, previous studies have demonstrated significant alterations in lipid profiles such as an increase in serum triglyceride and cholesterol and a decrease in HDL levels in obese animals [7, 17]. MC treatment ameliorate biochemical alterations significantly and prevented dyslipidemia in HFD-induced obese rats [17]. Parallel to these findings, our study revealed an increase in triglyceride and cholesterol levels and a decrease in HDL levels in the blood serum, and MC treatment reversed these alterations.

Obesity is known to trigger cardiovascular diseases with the increased production of ROS [7, 8, 12]. In recent studies on obesity and the cardiovascular system, it revealed that cardiovascular dysfunction is often in regions where obesity is common [1]. Previous studies have reported that oxidative stress plays a key role in cardiovascular diseases [1, 7, 14]. One of the main factors of obesity formation is the consumption of foods with high-fat content. HFD increases oxidative stress formation due to the production of superoxide anions [25]. Obesity causes deterioration of the morphology in the heart via the inflammatory cell infiltration, diffuse fibrosis and collagen deposition, also leading to disruption of the structure of the endothelial cells in the vessels, resulting in endothelial dysfunction [26].

In recent years the use of plant derived antioxidants have been increased in research studies for the treatment and prevention of many diseases including cardiovascular diseases [27, 28]. Previous studies have shown that MC have, antiobesity, antioxidative, antiinflammatory, antiapoptotic effects against oxidative stress in various animal models. As a result of the researches, the effects of the aerial parts, leaves, fruits and essential oil of MC are revealed [15, 16]. Semi-myrtucommulone and myrtucommulone-A are the compounds of MC and their antiatherogenic effects are reported [29, 30]. However, there are few studies on the effect of MC treatment on obesity or body weight, heart and aorta studies are limited in the literature.

NO has an essential role in the continuation of cardiovascular homeostasis via protective effects against vascular injury, inflammation and thrombosis [13]. NO inhibits the adhesion of leukocytes to the endothelium, keeps vascular smooth muscle cells in a nonproliferative position, and limits the platelet aggregation [31, 32]. Common cardiovascular risk factors, such as hipertension and obesity impair the protective function of the endothelium [33]. Previous studies have shown that HFD induced obesity decreases eNOS activity and increases both NO levels and

iNOS activity by the excessive ROS production [13, 34]. In our study, we revealed a decrease in eNOS-ir cells and NO levels, and an increase in iNOS-ir cells in both heart and aorta in HFD induced obese rats. MC treatment ameliorated these NO levels, eNOS-ir and iNOS-ir in both heart and aorta tissues.

HFD increases the production of ROS and induces the pathological changes in tissues [35]. MDA is the key indicator of lipid peroxidation and it was reported that MDA levels increased in the HFD induced obesity [15, 17, 21]. Previous studies revealed that antioxidant agents decreased MDA levels in HFD induced obesity [18, 36, 37]. Similar to these studies, we observed increased MDA levels in HFD group and MC treatment ameliorated the alterations in both heart and aorta. Previous studies have shown that the main source of ROS is NOX-2, because activated NOX-2 transports electrons to oxygen causes the formation of superoxide anions [37]. Inhibition of this enzyme may play a role in protecting organs against oxidative damage [38]. Nutrition with a high-fat diet leads to the activation of NOX-2, which leads to the production of superoxide anions, and consequently to the increase of oxidative stress. NOX-2 is a major source of endothelial reactive oxygen species and expressed in the vessel in endothelial cells, adventitic fibroblasts and a smaller amount of smooth muscle cells. Excess oxygen radicals produced by NOX-2 cause endothelial dysfunction and cause vascular complications [39]. In our study we observed that HFD increased the number of NOX-2 immunopositive cells and MC treatment decreased the number of NOX-2 immunopositive cells.

Obesity increases ROS production and causes increased expression of proinflammatory cytokines such as TNF-α, MCP-1, and IL-6. Therefore, obesity is considered a chronic inflammatory disease [40]. In our study, HFD induced obesity increased inflammation-related markers via increasing ROS and detoriating anti-oxidant defense. TNF-α and MCP-1 levels increased in both heart and aorta tissues in HFD group, and it revealed that HFD induced damages were associated with inflammation. MC treatment ameliorated the levels of inflammatory markers including TNF-α and MCP-1, in both heart and aorta tissues.

Oxidative stress also affects the regulation of proliferation and apoptosis in the tissue. Thus, HFD induced oxidative stress causes an increase in apoptotic cell numbers in the heart and aorta. As it is well known, the alterations of apoptosis have been involved in pathology of the many diseases such as cardiovascular diseases [41]. In the present study, TUNEL positive cells counted and apoptotic index were used to evaluate apoptotic cells. The number of apoptotic cardiomyosites and endothelial and smooth muscle cells in aorta were the highest in the HFD. Increased apoptosis may be a consequence of HFD induced oxidative stress. MC treatment decreased apoptotic cells in both hearth and aorta via the strong antioxidative and antiinflammatory effects.

The increased ROS formation induced by a HFD may result in oxidation of both lipids and nucleic acids as well. Extensive oxidative damage interferes with replication and transcription, resulting in genetic instability and an increased mutations. Evaluation of the severity of oxidative damage to DNA commonly involves determination of the content of 8-OHdG which is an oxidized form of guanine [42]. 8-OHdG, is a marker of DNA damage which is formed by ROS in damaged tissue. Previous studies have shown that HFD induced obesity increases 8-OHdG in many tissues [43]. Moreover, it has been shown that HFD increased the number of apoptotic cells in the heart and aorta [44, 45]. In HFD induced obese rats, MC has been shown to increase anti-oxidant activity, reduce apoptosis and ameliorated the histopathological alterations [17, 18]. A previous study suggested that polyphenolic compounds have an important protective effect against cardiovascular diseases (46). LC-MS/MS analysis of MC ethanol extract in another previous study showed that the extract contained polyphenolic compounds such as myricetin hexoside, myricetin rhamnoside, ellagic acid, quercetin rhamnoside, myricetin, trihydroxy cinnamic acid derivative, cafeic acid derivative and sinapinic acid derivative [20]. In a previous study, it was found that MC extract had high total phenol content (368,68 mg/g extract as gallic acid equivalent) and total flavonoid (111,35 mg/g extract as catechine equivalent) with signifcant *in vitro* antioxidant activity [21]. Therefore, polyphenolic compunds in extract could be responsible for the curative effect of MC extract on HFD induced heart and aorta damage.

Parallel to these findings, an increase in 8-OHdG level and apoptotic activity in the heart and aorta tissues in the HFD group has been observed in our study. However, MC treatment reduced apoptotic activity and 8-OHdG level in both the heart and aorta tissues. MC extract amelioriated HFD-induced heart and aorta damage via inhibition of apoptotic activity. In this study it has been shown that MC extract might have antioxidant and antiapoptotic function in the heart and aorta tissue.

Conclusion

In conclusion, the present study revealed that HFD-induced obesity caused alteration in lipid profiles, histopathologic damage in the heart and aorta tissues by increased oxidative stress, NOX-2-ir and iNOS-ir, reduced NO activity. MC treatment has potent antioxidant, anti-inflammatory and antiapoptotic effects, it might ameliorate HFD induced cardiovascular damage via inhibiting the oxidative stress and regulating NO metabolism.

Acknowledgments: The authors would like to thank Dr. Gizem Emre for her help in identification of the plant material.

Compliance with Ethical Standards

Ethical Approval: This study was approved by Marmara University, Animal Care and Use Committee (23.2019.mar).

Financial Support: This study was supported by Marmara University Research Fund (SAG-C-DRP-250.919.0292).

Conflict of Interest: The authors declare that there are no conflicts of interest.

Author Contributions: NOY, NBA, GS and FE: Contributed conception and design, NOY, NBA, GS, RK and FE: Performed experiments and did data collection, NOY, GS and FE: Analyzed data, NOY and FE: Contributed to the writing. All authors approved the final version of the article.

REFERENCES

[1] World Health Organization. Obesity and overweight. 2021 June 9 (cited 2022 March 12). Available from: https://www.who.int/newsroom/ fact-sheets/detail/obesity-and-overweight

[2] Blüher M. Obesity: Global epidemiology and pathogenesis. Nat Rev Endocrinol 2019; 15(5):288-98. doi: 10.1038/s41574.019.0176-8

[3] Tobore TO, Towards A. Comprehensive theory of obesity and a healthy diet: The causal role of oxidative stress in food addiction and obesity. Behav Brain Res 2020; 384: 112560. doi: 10.1016/j.bbr.2020.112560

[4] Manna P, Jain SK. Obesity, oxidative stress, adipose tissue dysfunction, and the associated health risks: Causes and therapeutic strategies. Metab Syndr Relat Disord 2015; 13: 423-44. https://doi.org/10.1089/met.2015.0095

[5] Ndisang JF, Vannacci A, Rastogi S. Oxidative stress and inflammation in obesity, diabetes, hypertension, and related cardiometabolic complications. Oxid Med Cell Longev 2014; 2014:506948. doi: 10.1155/2014/506948

[6] Sonta T, Inoguchi T, Tsubouchi H, Sekiguchi N, Kobayashi K, Matsumoto S. Evidence for contribution of vascular NAD(P)H oxidase to increased oxidative stress in animal models of diabetes and obesity. Free Radic Biol Med 2004; 37:115–23. doi: 10.1016/j.freeradbiomed.2004.04.001

[7] Acikel Elmas M, Cakıcı SE, Dur IR, et al. Protective effects of exercise on heart and aorta in high-fat diet-induced obese rats. Tissue Cell 2019; 57:57-65. https://doi.org/10.1111/jfbc.12297

[8] Gamez-Mendez AM, Vargas-Robles H, Ríos A, Escalante B. Oxidative stress-dependent coronary endothelial dysfunction in obese mice. PloS One 2015; 10:e0138609. doi:10.1371/journal.pone.0138609

[9] Sukumar P, Viswambharan H, Imrie H, Cubbon RM, Yuldasheva N, Gage M. NADPH oxidase has a critical role in insulin resistance-related endothelial cell dysfunction. Diabetes 2013; 62:2130–134. doi: 10.2337/db12-1294

[10] Silver AE, Beske SD, Christou DD, Donato AJ, Moreau KL, Eskurza I. Overweight and obese humans demonstrate increased vascular endothelial NAD(P)H oxidase-p47phox expression and evidence of endothelial oxidative stress. Circulation 2007; 115:627–63. doi: 10.1161/CIRCULATIONAHA.106.657486

[11] Elmas MA, Ozakpinar OB, Kolgazi M, Sener G, Ercan F. Morphological and biochemical investigation of the healing effects of exercise on high fat diet induced kidney and bladder damage. Clin Exp Health Sci 2022; 12: 817 - 23. doi: 10.33808/clinexphealthsci.1027516

[12] Hoogeveen RC, Morrison A, Boerwinkle E, et al. Plasma MCP-1 level and risk for peripheral arterial disease and incident coronary heart disease: Atherosclerosis Risk in Communities study. Atherosclerosis 2005; 183:301-7. doi: 10.1016/j.atherosclerosis.2005.03.007

[13] Engin A. Endothelial dysfunction in obesity. Adv Exp Med Biol 2017; 960:345-79. doi: 10.1007/978-3-319-48382-5_15

[14] Silva JF, Correa IC, Diniz TF, et al. 2016. Obesity, inflammation, and exercise training: Relative contribution of iNOS and eNOS in the modulation of vascular function in the mouse aorta. Front Physiol 2016; 7:386. doi: 10.3389/fphys.2016.00386

[15] Patra S, Nithya S. Review of medicinal plants for anti-obesity activity. Transl Biomed 2015; 6:1-22. https://doi.org/10.21767/2172-0479.100021

[16] Alipour G, Dashti S, Hosseinzadeh H. Review of pharmacological effects of *Myrtus communis* L. and its active constituents. Phytother Res 2014; 28:1125-36. doi: 10.1002/ptr.5122

[17] Kanpalta F, Ertas B, Sen A, Akakin D, Sener G, Ercan F. *Myrtus communis* L. extract amelioarates high fat diet induced kidney and bladder damage by inhibiting oxidative stress and inflammation. Eur J Biol 2022; 81: 217-30. doi: 10.26650/EurJBiol.2022.111.1191

[18] Kuru Yaşar R, Kuru D, Şen A, Şener G, Ercan F, Yarat A. Effects of *Myrtus communis* L. extract and apocynin on lens oxidative damage and boron levels in rats with a high fat-diet. Turk J Ophthalmol 2021; 51: 344-50. doi: 10.4274/tjo.galenos.2021.27981

[19] Khan R, Feroz Z, Jamil M, Ahmed M. Hypolipidemic and Antithrombotic evaluation of *Myrtus communis* L. in cholesterol-fed rabbits. Afr J Pharm Pharmacol 2014; 8:235-39. doi: 10.5897/AJPP2013.3488

[20] Arslan S, Ozcan O, Gurel-Gokmen B, et al. Myrtle improves renovascular hypertension-induced oxidative damage in heart, kidney, and aortic tissue. Biologia 2022; 77: 1877-88. doi: 10.1007/s11756.022.01039-1

[21] Sen A, Yuksel M, Bulut G, et al. Therapeutic potential of *Myrtus communis* subsp. *communis* extract against acetic acid-induced colonic inflammation in rats. J Food Biochem 2017; 41: e12297. https://doi.org/10.1111/jfbc.12297

[22] Sener G, Toklu H, Kapucu C, et al. Melatonin protects against oxidative organ injury in a rat model of sepsis. Surg Today 2005; 35: 52 – 9. doi: 10.1007/s00595.004.2879-1

[23] Hamblin M, Chang L, Zhang H, Yang K, Zhang J, Chen YE. Vascular smooth muscle cell peroxisome proliferator-activated receptor-γ deletion promotes abdominal aortic aneurysms. J Vasc Surg 2010; 52:984-93. doi: 10.1016/j.jvs.2010.05.089

[24] Ahmed AH. Flavonoid content and antiobesity activity of leaves of *Myrtus communis*. Asian J Chem 2013; 25: 6818–22. https://doi.org/10.14233/ajchem.2013.14823

[25] Yu HT, Fu X, Liang B, et al. Oxidative damage of mitochondrial respiratory chain in different organs of a rat model of diet-induced obesity. Eur J Nutr 2018; 57: 1957-67. doi: 10.1007/s00394.017.1477-0

[26] Hariri N, Thibault L. High-fat diet-induced obesity in animal models. Nutr Res Rev 2010; 23: 270-99. doi: 10.1017/S095.442.2410000168

[27] Tuzcu Z, Orhan C, Sahin N, Juturu V, Sahin K. Cinnamon polyphenol extract inhibits hyperlipidemia and inflammation by modulation of transcription factors in high-fat diet-fed rats. Oxid Med Cell Longev 2017; 1583098. doi: 10.1155/2017/1583098

[28] Mabrouki L, Rjeibi I, Taleb J, Zourgui L. Cardiac ameliorative effect of Moringa Oleifera leaf extract in high-fat diet-induced obesity in rat model. Biomed Res Int 2020; 7:6583603. doi: 10.1155/2020/6583603.

[29] Rosa A, Deiana M, Casu V, et al. Antioxidant activity of oligomeric acylphloroglucinols from *Myrtus communis* L. Free Radic Res 2003; 37: 1013-19.

[30] Rossi A, Di Paola R, Mazzon E, et al. Myrtucommulone from *Myrtus communis* exhibits potent anti-inflammatory effectiveness in vivo. J Pharmacol Exp Ther 2009; 329: 76-86.

[31] Kumral ZN, Sener G, Ozgur S, et al. Regular exercise alleviates renovascular hypertension-induced cardiac/endothelial dysfunction and oxidative injury in rats. J Physiol Pharmacol 2016; 67: 45-55.

[32] Ritchie RH, Drummond GR, Silva S, Kemp-Harper BK. The opposing roles of NO and oxidative stress in cardiovascular disease. Pharmacol Res 2017; 116:57-69. doi: 10.1016/j.phrs.2016.12.017

[33] Skrzep-Poloczek B, Poloczek J, Chełmecka E, et al. The Oxidative stress markers in the erythrocytes and heart muscle of obese rats: Relate to a high-fat diet but not to DJOS bariatric surgery. Antioxidants 2020; 9:183. doi: 10.3390/antiox9020183

[34] Godo S, Shimokawa H. Divergent roles of endothelial nitric oxide synthases system in maintaining cardiovascular homeostasis. Free Radic Biol Med 2017; 109:4-10. doi: 10.1016/j.freeradbiomed.2016.12.019.

[35] Ritchie RH, Drummond GR, Silva S, Kemp-Harper BK. The opposing roles of NO and oxidative stress in cardiovascular disease. Pharmacol Res 2017; 116:57-69. doi: 10.1016/j.phrs.2016.12.017

[36] Sen A, Ozkan S, Recebova K, et al. Effects of *Myrtus communis* extract treatment in bile duct ligated rats. J Surg Res 2016;205: 359–67. https://doi.org/10.1016/j.jss.2016.06.094

[37] Wang X, Zhao S, Su M, Sun L, et al. Geraniol improves endothelial function by inhibiting NOX-2 derived oxidative stress in high fat diet fed mice. Biochem Biophys Res Commun 2016; 474: 182-7. doi: 10.1016/j.bbrc.2016.04.097

[38] Ma Y, Li H, Yue Z, et al. Cryptotanshinone attenuates cardiac fibrosis via downregulation of COX-2, NOX-2, and NOX-4. J Cardiovasc Pharmacol 2014; 64:28-37. doi: 10.1097/FJC.000.000.0000000086

[39] Du J, Fan LM, Mai A, Li JM. Crucial roles of Nox2-derived oxidative stress in deteriorating the function of insulin receptors and endothelium in dietary obesity of middle-aged mice. Br J Pharmacol 2013; 170 :1064–77. doi: 10.1111/bph.12336

[40] Gregor MF, Hotamisligil GS. Inflammatory mechanisms in obesity. Annu Rev Immunol 2011; 29: 415-45. https://doi.org/10.1146/annurev-immunol-031.210.101322

[41] Hunter AL, Choy JC, Granville DJ. Detection of apoptosis in cardiovascular diseases. Methods Mol Med 2005; 112:277-89. doi: 10.1385/1-59259-879-x:277

[42] Maciejczyk M, Zebrowska E, Zalewska A, Chabowski A. Redox balance, antioxidant defense, and oxidative damage in the hypothalamus and cerebral cortex of rats with high fat diet-induced insulin resistance. Oxid Med Cell Longev 2018; 6:6940515. doi: 10.1155/2018/6940515

[43] Valavanidis A, Vlachogianni T, Fiotakis C. 8-hydroxy-2'-deoxyguanosine (8-OHdG): A critical biomarker of oxidative stress and carcinogenesis. J Environ Sci Health C Environ Carcinog Ecotoxicol Rev 2009; 27:120-39. doi: 10.1080/105.905.00902885684.

[44] Kalpana Ballal, Christopher R Wilson, Romain Harmancey, Heinrich Taegtmeyer. Obesogenic high fat western diet induces oxidative stress and apoptosis in rat heart. Mol Cell Biochem 2010; 344:221-30. doi: 10.1007/s11010.010.0546-y

[45] Xu Z, Qin Y, Lv B, Tian Z, Zhang B. Intermittent fasting improves high-fat diet-induced obesity cardiomyopathy via alleviating lipid deposition and apoptosis and decreasing m6A methylation in the heart. Nutrients 2022; 14:251. doi: 10.3390/nu14020251

[46] Morton LW, Caccetta RAA, Puddey IB, Croft KD. Chemistry and biological effects of dietary phenolic compounds: relevance to cardiovascular disease. Clin Exp Pharmacol Physiol 2000; 27:152-59. doi: 10.1046/j.1440-1681.2000.03214.x.