REPUBLIC OF TURKEY
MARMARA UNIVERSITY
INSTITUTE OF HEALTH SCIENCES

# SELLA TURCICA MORPHOMETRICS IN SUBJECTS WITH DOWN SYNDROME

PETROS PAPAEFTHYMIOU

MASTER OF SCIENCE THESIS

DEPARTMENT OF ORTHODONTICS

SUPERVISOR
Assist. Prof. Dr. Elvan ÖNEM ÖZBİLEN

ISTANBUL-2022

REPUBLIC OF TURKEY
MARMARA UNIVERSITY
INSTITUTE OF HEALTH SCIENCES

# SELLA TURCICA MORPHOMETRICS IN SUBJECTS WITH DOWN SYNDROME

PETROS PAPAEFTHYMIOU

MASTER OF SCIENCE THESIS

DEPARTMENT OF ORTHODONTICS

SUPERVISOR
Assist. Prof. Dr. Elvan ÖNEM ÖZBILEN

ISTANBUL-2022

## STATEMENT

Hereby I declare that this thesis study is my own work, I had no unethical behavior in any stage from planning of the thesis until writing it, I have obtained all the information in this thesis within the academic and ethical rules, I have cited all the information and comments that are not obtained with this thesis study, and these sources are also included in the list of references, I hereby declare that I have no infringement of patents and copyrights during the study and writing of this thesis.

Petros Papaefthymiou

## ACKNOWLEDGEMENT

First of all, I would like to thank my thesis supervisor, Asst. Prof. Dr. Elvan Onem Ozbilen for her guidance and assistance not only in supervising my research work but through the whole course of my specialization in orthodontics. Her office door was always open when I needed help and answers to my questions. I am very lucky you were my mentor. I would like to express my deepest gratitude to my dear professors starting from Assoc. Prof. Dr. Nuray Yilmaz who always with her hard work and dedication stood as an example, Asst. Prof. Dr. Yasemin Bahar Acar and Asst. Prof. Dr. Ece Abuhan were always there to share their knowledge and invaluable experience with calmness and precision, and Asst. Prof. Dr. Kadir Beycan for his tutoring and guidance. Furthermore, I would like to thank Prof. Dr. Ahu Acar and Prof. Dr. Fulya Özdemir for sharing their experience despite their duties as heads of the department. In addition, I would like to mention Prof. Dr. Banu Çakırer Bakkalbaşı and Dr. Burcu Kılıç for their contribution to the archive for patients with Down Syndrome, without their valuable record collection over the years this research would not be possible. Moreover, I would like to thank my friends and colleagues in the department for their friendship and help every time I needed it. At this point, I need to express my gratitude to Prof. Demetrios Halazonetis from the department of orthodontics at the National and Kapodistrian University of Athens, for sharing his knowledge and guiding me anytime I sought his help. Without his participation, this thesis would not have been completed. Additionally, I would like to thank Epameinondas-Spyridon Themelis for his estimable contribution to statistical analysis. Finally, I must express my utmost gratitude to my parents, whose continuous support and encouragement though all the years of my studies have been vital in reaching the point I am now. This accomplishment would now have been possible with their efforts. I hope you are proud and happy.

## CONTENTS

Page

**ACKNOWLEDGMENT** ..... ii

**CONTENTS** ..... iii

**ABBREVIATIONS and SYMBOLS LIST** ..... vi

**FIGURE LIST** ..... vii

**PICTURE LIST** ..... x

**TABLE LIST** ..... xi

**1. ÖZET** ..... 1

**2. SUMMARY** ..... 2

**3. INTRODUCTION and AIM** ..... 3

**4. GENERAL INFORMATION** ..... 5

4.1. Down Syndrome (Trisomy 21) ..... 5

4.1.2. Genetics… ..... 5

4.1.2.1. Trisomy 21 ..... 5

4.1.2.2. Robertsonian translocation ..... 7

4.1.2.3. 21q21q translocation ..... 8

4.1.2.4. Partial trisomy 21… ..... 9

4.1.3. Clinical diagnostic characteristics… ..... 10

4.1.4. Growth and development in subjects with Down syndrome ..... 11

4.1.5. Diagnosis and screening… ..... 12

4.1.6. Craniofacial manifestations of Down syndrome ..... 13

4.1.6.1. Oral phenotypic manifestations of Down syndrome ..... 15

4.2. Cephalometrics… ..... 18

4.2.1. Introduction to cephalometrics… ..... 18

4.2.2. Historical review of cephalometrics ..... 19

4.2.3. Patient positioning ..... 20

4.2.4. Anatomical structures ..... 21

4.2.4.1. Cranial base ..... 21

4.2.4.2. Tracing of cranial base ..... 23

4.2.4.3. Sella turcica ..... 25

4.3. Geometric Morphometrics… ..... 26

4.3.1. Description of shape and Procrustes superimposition ..... 27

4.3.2. Shape variability and average shape considerations ..... 30

4.3.2.1. Principal component analysis (PCA) ..... 30

4.3.2.2. Application of principal component analysis in cephalometric analysis…32

**5. MATERIALS AND METHODS ..... 34**

5.1. Patient Selection… ..... 34

5.2. Data Collection…..... 35

5.3. Data Assessment… ..... 36

5.4. Statistical Analysis ..... 44

**6. RESULTS ..... 46**

6.1. Sample Demographics… ..... 46

6.2. Sella Size Analysis… ..... 46

6.3. Sella Shape Analysis ..... 47

**7. DISCUSSION and CONCLUSION ..... 52**

7.1. Sella Dimensions Related to Systemic Conditions… ..... 52

7.2. Discussion of the Materials and Methods ..... 53

7.3 Discussion of the Results… ..... 53

7.3.1 Sella Size ..... 54

7.3.2 Sella Shape ..... 55

7.4 Conclusion ..... 56

**8. REFERENCES** ..... 58

**9. ENCLOSURES** ..... 71

9.1 Enc ..... 71

**10. CURRICULUM VITAE** ..... 72

## ABBREVIATIONS and SYMBOLS LIST

DS: Down syndrome

TSH: Thyroid-stimulating hormone

MLPA: Multiplex ligation-dependent probe

FISH: Fluorescence in situ – hybridization

AFP: Alpha-fetoprotein

NGS: next-generation sequencing

PCA: Principal component analysis

PC: Principal component

MRI: Magnetic resonance imaging

CT: Computed tomography

%: Percent

˚: Degree

## FIGURE LIST

Page

**Figure 1**: Structure and morphology of chromosome 21 ..... 6

**Figure 2**: Karyotype of a male subject diagnosed with Down syndrome ..... 6

**Figure 3**: Association of maternal age and trisomy 21 at points of birth and amniocentesis ..... 7

**Figure 4**: Robertsonian translocation between two acrocentric chromosomes ..... 8

**Figure 5**: Formation of an isochromosome of the long arm of a chromosome ..... 8

**Figure 6**: Genotype-phenotype association in Down syndrome based on partial trisomy 21 subjects ..... 9

**Figure 7**: (a) Fluorescence-in-situ-hybridization (FISH). (b) Molecular karyotyping (microarray analysis). (c) Multiplex ligation-dependent probe amplification (MLPA). (d) Genome-wide sequencing techniques (next generation sequencing NGS) ..... 12

**Figure 8**: Lateral and frontal cephalometric radiographs ..... 18

**Figure 9**: (a) Broadbent craniostat for standardizing skull position and measuring. (b) Frankfort horizontal, Bolton-nasion, and orbitalplanes ..... 19

**Figure 10**: Patient positioning for the purposes of lateral cephalometric imaging ..... 20

**Figure 11**: Intracranial anatomical structures ..... 21

**Figure 12**: Superior view of the skull representing the regions of the cranial base exhibiting various degrees of stability. The regions with green are stable after 7 years of age. The region in pink presents minimal growth potential after the age of 6 years and completely no growth after 14 years ..... 22

**Figure 13**: The midsagittal anatomical region of the cranial base ..... 22

Page

**Figure 14**: Anterior cranial base tracing, including occipital, sphenoid, and ethmoid bones ..... 23

**Figure 15**: Tracing of the external auditory meatus. Identification of planum sphenoidale as the most superior part of sphenoid and ethmoid bones ..... 24

**Figure 16**: (a) Superimposition at arbitrary position and orientation. (b) Superimposition on anterior cranial base ..... 28

**Figure 17**: Tracings of figure 16 superimposed with the implementation of Procrustes method ..... 29

**Figure 18**: Average shape and scatter of a sample with multiple tracings. Procrustes superimposition has been implemented..... 31

**Figure 19**: Shapes exhibiting the variance of the first three PCs. The average shape is warped with the application of each principal component equal to three standard deviations..... 33

**Figure 20**: Tracing of sella turcica contour with the definition of the following anatomical landmarks and planes: posterior clinoid process (PClin), tuberculum sella (TS), sella posterior (SP), sella anterior (SA), sella floor (SF), Frankfort plane (FH). The following linear measurements were calculated: sella width (SP to SA, parallel to FH), sella anterior height (TS to SF, perpendicular to FH), sella midpoint height (midpoint between PClin and TS to SF), sella posterior height (PClin to SF, perpendicular to FH), sella length (PClin to TS) ..... 37

**Figure 21**: Initial tracing of sella turcica contour in Viewbox 4 software ..... 38

**Figure 22**: Finalizing tracing of the sella turcica contour in Viewbox 4 software..... 40

**Figure 23**: Measurement of the anterior, midpoint, and posterior sella height in Viewbox 4 software ..... 41

Page

**Figure 24**: The extracted sella turcica tracing with the Frankfort horizontal plane as a reference plane ..... 42

**Figure 25**: Automatic calculation of the sella turcica dimensions from Viewbox 4 software according to the anatomical landmarks defined ..... 42

**Figure 26**: Calculation of the sella turcica average shape of the entire sample of the study with Viewbox 4 software..... 43

**Figure 27**: Sella shape morphometric analysis with the implementation of Procrustes superimposition and principal component analysis (PCA) in Viewbox 4 software ..... 43

**Figure 28**: Dahlberg's formula implemented for error calculation in the present study ..... 45

**Figure 29**: Scree plot of variance and principal components ..... 48

**Figure 30**: Statistical investigation of principal component analysis of the sample in Viewbox 4 software ..... 49

**Figure 31**: Statistical investigation of principal component analysis of the sample in Viewbox 4 software with increased magnification ..... 49

**Figure 32**: Principal component analysis (PCA) plot for PC1 - PC2 and PC2 – PC3. (Red: Down syndrome subjects, Blue: control group) generated from Viewbox 4 software ..... 50

**Figure 33**: Average sella shape of (a) Control group, and (b) Down syndrome group ..... 50

**Figure 34**: Variability of sella turcica shape of the whole sample as affected from the first three PCs. Average shape is located in the center and the effects of each PC on sella shape in the extremes by 3 standard deviations ( +/- 3 SD) on the left and right ..... 51

# V. PICTURE LIST

Page

**Picture 1**: Typical facial appearance of a patient with Down syndrome .....10

**Picture 2**: (a) Clinodactyly of the 5th finger. (b) Tongue protrusion or macroglossia. (c) Epicanthus. (d) Brusfield spots..... 11

**Picture 3**: Extra-oral characteristics of a patient with Down syndrome.....14

**Picture 4**: Intra-oral characteristics of a patient with Down syndrome.....17

# VI. TABLE LIST

Page

**Table 1:** Sella size statistical comparison of Down syndrome subjects with healthy controls ..... 47

**Table 2:** Variance and cumulative variance of the first 10 PCs of shape percentages ..... 48

# 1. ÖZET

**Tezin başlığı:** Down Sendromlu Bireylerde Sella Tursika Morfometrisi
**Öğrencinin Adı, Soyadı:** Petros Papaefthymiou
**Danışmanın Adı, Soyadı:** Dr. Öğr. Üyesi Elvan Önem Özbilen
**Programın Adı:** Ortodonti (Ingilizce) Tezli Yüksek Lisans

**Amaç:** Bu çalışmanın amacı, Down sendromlu bireylerde sella tursikanın boyut ve şeklini morfometrik yöntemler uygulayarak sağlıklı kontrol grubu ile karşılaştırmaktır.
**Gereç ve Yöntem:** Bu retrospektif çalışmada, Marmara Üniversitesi, Diş Hekimliği Fakültesi, Ortodonti Anabilim Dalı'nda (İstanbul, Türkiye) muayene edilmiş 24 Down sendromlu bireyin arşiv kayıtları, yaş ve cinsiyet açısından eşleştirilmiş 24 sağlıklı birey karşılaştırılmıştır. Toplanan sefalometrik radyograflar Nemoceph (Nemotec, Madrid, İspanya) yazılımına yüklenmiş ve analizden önce magnifikasyon oranları ayarlanmıştır. Sella anterior, orta nokta ve posterior yükseklik gibi parametreler ölçülmüş, ayrıca sella genişliği, alanı ve uzunluğu hesaplanmıştır. Sella tursikanın geometrik morfometrik analizi, Viewbox 4 sefalometrik yazılımı (dHAL Software, Kifissia, Yunanistan) ile, Procrustes metoduyla çakıştırma ve temel bileşen analizi (PCA) gibi yöntemler uygulanarak yapılmıştır. İstatistiksel anlamlılık $p<0,05$ olarak belirlenmiştir.
**Bulgular:** Sella anterior yüksekliği, sella orta nokta yüksekliği, sella maksimum yüksekliği ve sella alanı ile ilgili olarak Down sendromlu bireyler ve sağlıklı kontrol grubu arasında istatistiksel olarak anlamlı farklılıklar bulunmuştur. Yukarıda bahsedilen tüm değerler Down sendromlu bireylerde istatistiksel olarak anlamlı ölçüde artmıştır ($p<0,05$). Temel bileşen analizi, Down sendromlu bireyler ve sağlıklı kontrol grubu arasında sella şeklinde istatistiksel olarak anlamlı bir farklılık ortaya koymuştur ($p<0,05$).
**Sonuç:** Down sendromlu bireyler, sağlıklı kontrol grubuna kıyasla anlamlı şekilde artmış sella tursika boyutları ve istatistiksel olarak anlamlı şekil farklılıkları göstermiştir.
**Anahtar kelimeler:** Sella turcica, Down sendromu, Geometrik morfometrik, Sefalometrik radyografi, Genetik

## 2. SUMMARY

**Title of Thesis:** Sella Turcica Morphometrics in Subjects with Down Syndrome
**Student Name, Surname:** Petros Papaefthymiou
**Supervisor Name:** Asst. Prof. Dr. Elvan Önem Özbilen
**Program Name:** Orthodontics (English) Masters with Thesis

**Objective:** The aim of the present study is to implement morphometric methods to investigate the size and shape of sella turcica in subjects with Down syndrome.
**Material and Methods:** In this retrospective study, archive records of 24 individuals with Down syndrome examined at Marmara University Faculty of Dentistry, Department of Orthodontics (Istanbul, Turkey) were compared to 24 non-syndromic individuals matched for age and gender. The collected cephalometric radiographs were loaded into the Nemoceph (Nemotec, Madrid, Spain) software and adjusted for magnification prior to analyzing. Parameters such as sella anterior, midpoint, and posterior height were measured, as well as sella width, area, and length were calculated. Geometric morphometric analysis of the sella was performed with Viewbox 4 cephalometric software (dHAL Software, Kifissia, Greece), implementing methods such as Procrustes superimposition and principal component analysis. Statistical significance was set at $p<0,05$.
**Results:** Statistically significant differences were found for sella anterior height, sella midpoint height, sella maximum height, and sella area. All the aforementioned values were significantly increased in the Down syndrome subjects ($p<0,05$). Principal component analysis (PCA) depicted a statistically significant difference in sella shape between patients with Down syndrome and healthy controls ($p<0,05$).
**Conclusion:** Subjects with Down syndrome presented significantly increased sella turcica dimensions as well statistically significant differences in shape compared to healthy controls.

**Keywords:** Sella turcica, Down syndrome, Geometric Morphometrics, Cephalometric radiography, Genetics

## 3. INTRODUCTION and AIM

Down syndrome (DS) is a genetic disorder induced by the existence of a partial or complete third copy of chromosome 21 and comprises one of the most frequent chromosomal anomalies (Carey, 1992; Down, 1995; Desai, 1997; Gardner et al., 2012). Patients with Down syndrome present specific phenotypic characteristics such as delays in growth and development, cognitive impairment, disturbances in hearing and vision, as well as thyroid gland malfunction (Smith, 1976; Dinani and Carpenter, 1990; Abdullah et al., 1994; Sadler, 1995; Horbelt, 2007; Mıhçı et al., 2010; Myrelid et al., 2010). The etiology of the thyroid gland malfunction could be attributed to disorders in the production of thyroid-stimulating hormone (TSH) which is secreted from the pituitary gland. The latter is located in the anatomical structure named sella turcica, which is quite important for the craniofacial complex as well as the whole body. The hormone secretion that occurs in the pituitary gland is vital for the regulation of aspects such as blood pressure, temperature, and thyroid function, as well as for producing urine and sex hormones (Kumar, 2003; Regezi, 2017). According to research, the pituitary gland is formed in fetal life before the formation of sella turcica, while its development is closely connected with sella turcica growth. It has been reported by various researchers that individuals diagnosed with many different syndromes such as holoprosencephaly, Down syndrome, fragile X syndrome, Williams syndrome, etc. exhibit dimensional and morphological disturbances in the sella turcica region during fetal stages of growth (Kjaer and Fischer-Hansen, 1995; Kjaer et al., 1998; Kjaer et al., 1998; Hjalgrim et al., 2000; Kjaer et al., 2002; Axelsson et al., 2004). However, the alterations of the sella turcica structure in some of the aforementioned conditions that are observed during fetal growth are evident postnatally as well (Kjaer and Fischer-Hansen, 1995; Kjaer et al., 1998). According to the literature, there are many studies investigating sella turcica dimensions for disorders other than Down syndrome (Axelsson et al., 2004; Alkofide, 2008). Nevertheless, to our knowledge only three studies examined the sella turcica structure in individuals with Down syndrome presenting partially similar but also controversial results (Russell and Kjaer, 1999;

Korayem and AlKofide, 2015; Hasan et al., 2019). Recently, some authors attempted to examine the size and shape of sella turcica in healthy and non-syndromic cleft lip and palate subjects by implementing geometric morphometric techniques (Andredaki et al., 2007; Antonarakis et al., 2020). This methodology possesses the advantage of eliminating the differences that arise from the orientation of the lateral cephalometric radiographs and of the sella turcica itself, in order not to affect the measurements of sella dimensions, as well as the analysis of shape. Particularly, the application of geometric morphometrics in the analysis of lateral cephalometric radiographs could enable the researcher to avoid many of the conventional obstacles that arise during the application of traditional methods to evaluate these films (Halazonetis, 2004). For the reasons mentioned above, the present study aims to investigate the size and the shape of sella turcica in subjects with Down syndrome by the application of geometric morphometric techniques, and to compare the results with an age and gender-matched healthy control group.

# 4. GENERAL INFORMATION

## 4.1. Down Syndrome (Trisomy 21)

Down syndrome (Trisomy 21) has been characterized as the most common and well-known of all malformation syndromes, with various different signs reported which are exceeding 100 (Smith, 1976). In 1866, Langdon Down reported a condition that he named "Mongolian idiocy" (Down, 1995). There has been a similar description of the syndrome by Seguin earlier in 1846 named "furfuraceous cretinism" (Seguin, 1846). Lejeune in 1959 described the association of the condition with an additional G group chromosome (Lejeune et al., 1959), whereas Polani et al. described translocation type Down syndrome (Polani et al., 1960). Finally, Clarke et al reported mosaicism for an additional G group chromosome (Clarke et al., 1963).

### 4.1.1. Prevalence

The birth prevalence for Down syndrome is reported to be 1:650 live births but variety is exhibited between different population groups ranging from 1:600 to 1:2000 live births. It is worthwhile mentioning that 15% of patients being institutionalized for mental retardation issues are diagnosed with Down syndrome (Lilienfeld, 1969; Hamerton, 1971).

### 4.1.2. Genetics

#### 4.1.2.1. Trisomy 21

In up to 95% of subjects with Down syndrome, their karyotype is consisted of 47 chromosomes, with an additional copy of chromosome 21 (Nussbaum, 2016) (Figure 1 and 2). The etiology of this trisomy is associated with the meiotic nondisjunction of the chromosome 21 pair. It is worthwhile mentioning that the risk of the birth of a child with trisomy 21 is increasing with maternal age, particularly when the mother is over 30 years of age (Figure 3).

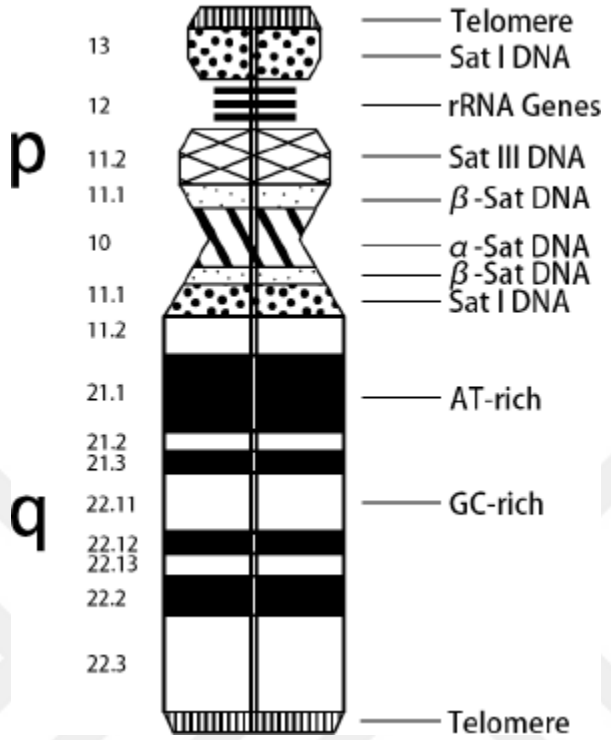


Figure 1: Structure and morphology of chromosome 21 (Willatt and Morgan, 2009).

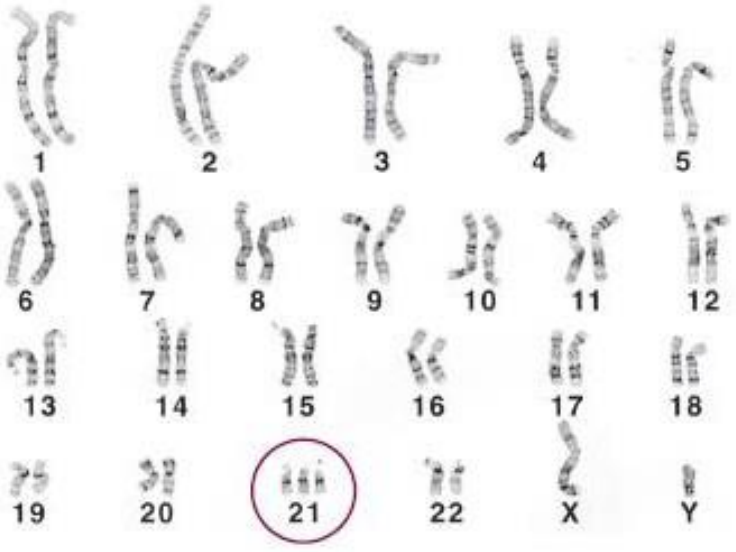


Figure 2: Karyotype of a male subject diagnosed with Down syndrome (Nussbaum, 2016).

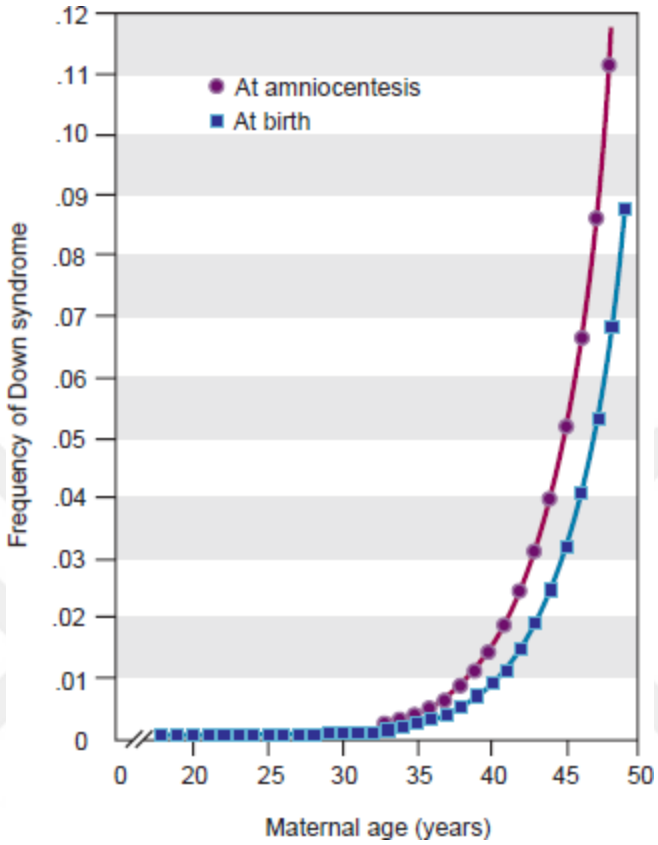


Figure 3: Association of maternal age and trisomy 21 at points of birth and amniocentesis (Nussbaum, 2016).

#### 4.1.2.2. Robertsonian translocation

Generally, 4% of patients diagnosed with Down syndrome have 46 chromosomes, due to the occurrence of a Robertsonian translocation between the 21q chromosome and the long arm of one acrocentric chromosome (commonly chromosomes 14 or 22) (Figure 4). Although subjects with a Robertsonian translocation associated with chromosome 21 have 46 chromosomes, are being trisomic for genes on the entireness of 21q. In contrast with classic trisomy 21, Down syndrome with Robertsonian translocation is not related to the age of the mother but presents a high occurrence rate in the families where one of the parents (specifically the mother) is a carrier (Nussbaum, 2016).

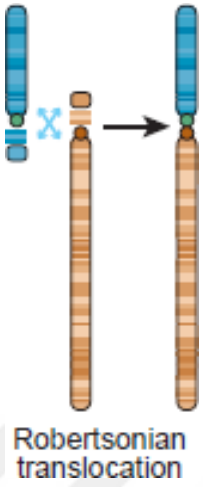


Figure 4: Robertsonian translocation between two acrocentric chromosomes (Nussbaum, 2016).

#### 4.1.2.3. 21q21q translocation

A 21q21q translocation chromosome can be observed in a small percentage of subjects with Down syndrome and it is believed to be originated as an isochromosome (Figure 5). All the gametes of a carrier with such a chromosome, must either possess the 21q21q chromosome or completely lack it and present the absence of chromosome 21 entirely. Additionally, the recurrence risk is increased in carriers exhibiting mosaicism (Nussbaum, 2016).

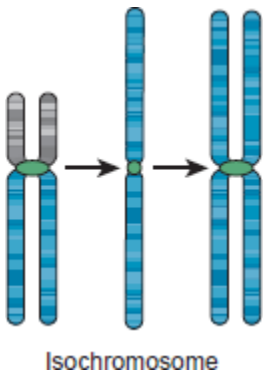


Figure 5: Formation of an isochromosome of the long arm of a chromosome (Nussbaum, 2016).

#### 4.1.2.4. Partial trisomy 21

On very rare occasions, a subject is being diagnosed with Down syndrome in whom only a part of the chromosome's 21 long arm exists in triplicate. It is worth mentioning that such patients are quite important, due to the fact that they could reveal which area of chromosome 21 might be associated with specific phenotypic features (Figure 6). Categorizing the distinctive genes which are critical for the expression of Down syndrome's phenotypic characteristics is crucial to understanding the etiologic basis of numerous diagnostic signs (Korbel et al., 2009).

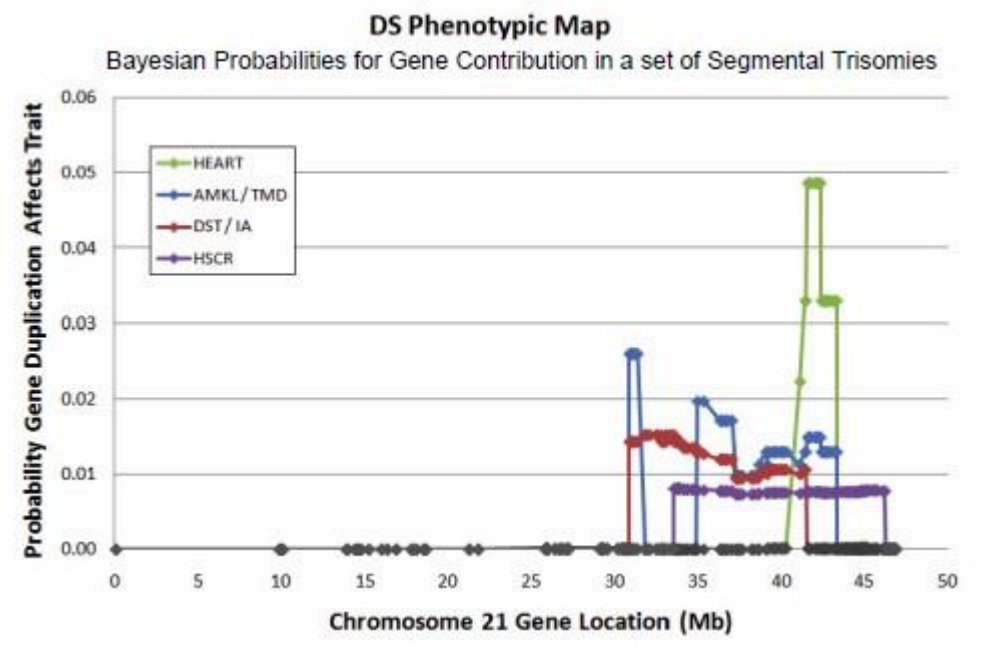


Figure 6: Genotype-phenotype association in Down syndrome based on partial trisomy 21 subjects (Korbel et al., 2009).

### 4.1.3. Clinical diagnostic characteristics

According to Hall (Hall, 1966), 10 frequent signs are reported in the newborn period:

1. Hypotonia
2. Poor Moro Reflex
3. Joint hyper-extensibility
4. Loose skin on the nape
5. Flattened facial profile
6. Up-slanted palpebral fissures
7. Small ears with overhanging helix
8. Pelvis dysplasia
9. Clinodactyly of the 5$^{th}$ fingers
10. Single transverse palmar creases

A minimum of four of the aforementioned signs were evident in all Hall's patients, whereas six or more were exhibited in 89% of the studied subjects (Picture 1 and 2). Down syndrome patients are often characterized by signs such as short height, intellectual disability, brachycephaly, flat occiput, epicanthic folds, Brushfield spots, tongue protrusion (or macroglossia), decreased neck height, short and broad hands, increased distance between 1$^{st}$ and 2$^{nd}$ toes, etc. (Smith, 1976).



Picture 1: Typical facial appearance of a patient with Down syndrome (Waterson, 1983).

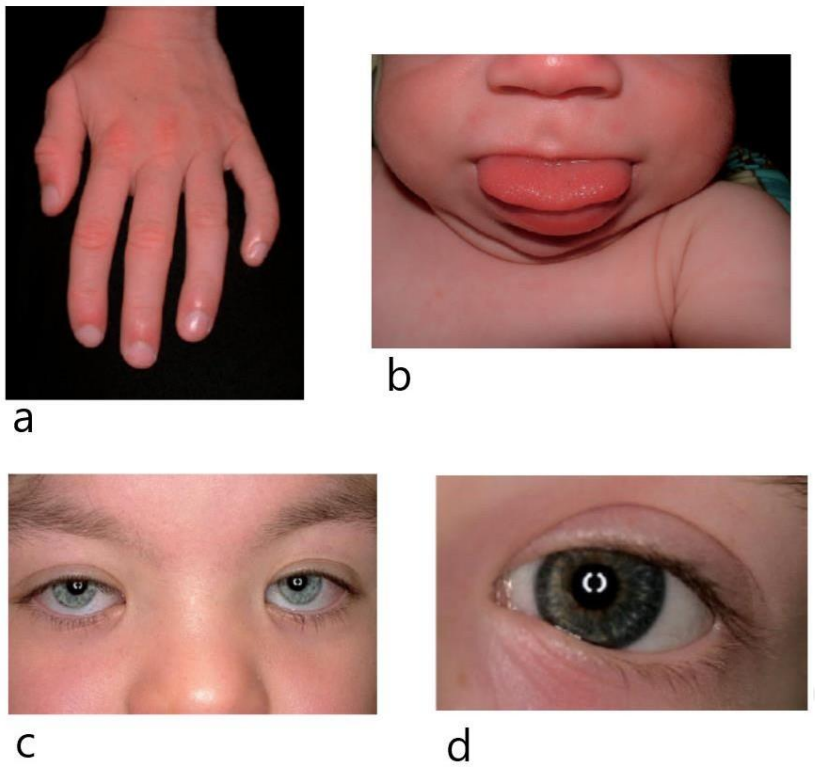


Picture 2: (a) Clinodactyly of the 5th finger, (b) Tongue protrusion or macroglossia, (c) Epicanthus, (d) Brushfield spots (Reardon, 2015).

### 4.1.4. Growth and development in subjects with Down syndrome

The impairment of growth and development is evident in subjects with Down syndrome. The average length in infants with Down syndrome is decreased by 2 to 3 cm, whereas the average weight is 400 grams less compared to healthy infants. Furthermore, a propensity towards premature birth has been reported in infants suffering from Down syndrome. Bone age of the subjects is characterized as normal to moderately increased at the birth time point, but it significantly decreases, so at 3 years postnatally bone maturity is reported to be substantially impaired. For male subjects, height is found to be on average 151 cm, whereas for females 141 cm. Finally, typical skeletal findings include flared iliac wings, and decreased length of the 5th finger meso-phalanx (Smith, 1976).

### 4.1.5. Diagnosis and screening

A variety of cytogenetic and molecular genetic techniques have been incorporated for the detection of Down syndrome. Molecular techniques such as microsatellite typing, multiplex ligation-dependent probe amplification (MLPA), and molecular karyotyping (microarray analysis), as well as conventional microscopic methods, such as karyotype (chromosome analysis) and fluorescence-in-situ-hybridization (FISH), have been implemented to detect "classic" genetic derangements (Caine et al., 2005; Willatt and Morgan, 2009; Eggermann et al., 2010). Furthermore, the risk for the occurrence of Down syndrome can be assessed after the initiation of the second trimester of pregnancy through serum alpha-feto protein (AFP) monitoring (Petit et al., 2009). Finally, the vast evolution of genome-wide sequencing techniques made the depiction of complete genomes a real possibility. Although it is still early the implementation of next-generation sequencing for the depiction of complete chromosome abnormalities such as trisomy 21, in the future such genetic disturbances would be identified swiftly, as well as with increased precision and reliability (Metzker, 2010).

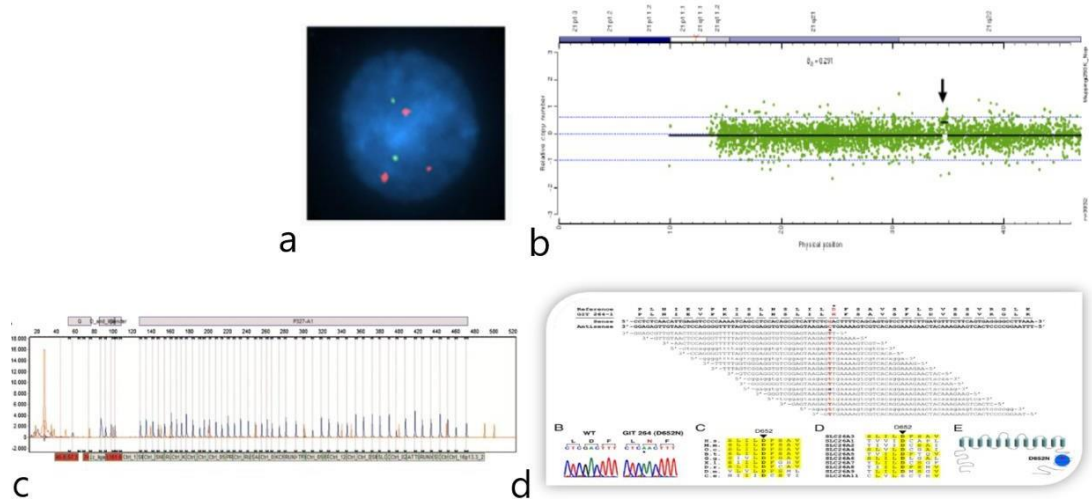


Figure 7: (a) Fluorescence-in-situ-hybridization (FISH), (b) Molecular karyotyping (microarray analysis), (c) Mutiplex ligation-dependent probe amplification (MLPA), (d) Genome-wide sequencing techniques (next generation sequencing - NGS) (Eggermann et al., 2010).

### 4.1.6. Craniofacial manifestations of Down syndrome

The maxilla is the craniofacial structure that is reported to be affected the most in patients with Down syndrome, mainly due to the developmental impairment of the midface, resulting in a profile characterized by a concavity in the regions of the zygomatic arch and malar bone (Weichert et al., 2016). According to recently conducted research, the upper jaw of such patients is found to be shorter compared to healthy controls, resulting in retrognathic maxilla (Alió et al., 2011; Korayem and AlKofide, 2014). Other studies demonstrating maxillary hypoplasia in this group of subjects corroborate these findings (van Marrewijk et al., 2016). However, it is worthwhile mentioning that patients with Down syndrome present similar rates of maxillary growth compared to healthy individuals, with the decreased maxillary dimensions at the onset of their development being the etiologic factor for their impairment (Alió et al., 2011). Furthermore, in relation to the mandibular length of individuals with Down syndrome, there are controversial reports. According to Korayem and AlKofide, the lower jaw length is analogous to healthy individuals (Korayem and AlKofide, 2014). On the contrary, Suri et al. reported that the mandibular length of Down syndrome subjects is significantly decreased (Suri et al., 2010). In terms of occlusion, numerous studies have depicted that Angle's Class III malocclusion is one of the most common craniofacial manifestations of subjects with Down syndrome (Abdul Rahim et al., 2014; Marques et al., 2015; Alkhadra, 2017). The etiologic factor of the aforementioned skeletal disharmony could be a combination of a protruded mandible and a deficient maxilla. In addition, an increased tendency to develop anterior as well as posterior open bite in patients suffering from Down syndrome has been reported in the literature (Foersch et al., 2015). Besides, posterior crossbite and deep bite are more frequently observed in Down syndrome subjects compared to healthy individuals (Ghaith et al., 2019). Finally, oral breathing is another frequent feature in such groups of patients, often leading to a narrow maxilla due to the change of tongue posture from the palate to the floor of the mouth which counteracts the pressure of the cheeks in the upper jaw. The disruption of the force equilibrium between the tongue and the cheeks results in

a narrower and deeper palatal vault, an increased growth tendency in the vertical dimension which consequently leads to an increased facial height (Oliveira et al., 2011).



Picture 3: Extra-oral characteristics of a patient with Down syndrome (Photos courtesy of Dr. Huseyin Budak).

#### 4.1.6.1. Oral phenotypic manifestations of Down syndrome

According to the literature, Down syndrome patients are characterized by an increased degree of alterations in the orofacial region. Particularly intra-oral manifestations of Down syndrome include changes in regions such as the teeth, the periodontal structures, and the tongue (Mubayrik, 2016). Moreover, various researchers reported an increased prevalence of hypodontia in patients with Down syndrome (Diéguez-Pérez et al., 2016; Ghaith et al., 2019). The etiology of this pathological condition could be attributed to a variety of factors, such as developmental modifications of the peripheral nervous system and alterations in the vascularization of dental buds (Suri et al., 2011). Furthermore, an increased rate of tooth wear is reported as well, due to the tendency of Down syndrome subjects to develop gastroesophageal reflux (Bell et al., 2002; Hyder et al., 2019). Structural tooth abnormalities are also a considerable part of the Down syndrome patients' phenotype. Those abnormalities frequently encompass microdontia, taurodontism, and tooth impactions (de Moraes et al., 2007; Cuoghi et al., 2016; Mubayrik, 2016; Ghaith et al., 2019). It is worthwhile mentioning that subjects with Down syndrome exhibit a lower percentage of dental caries in comparison with healthy individuals (Shukla et al., 2014; Diéguez-Pérez et al., 2016; Silva et al., 2020). This might be attributed to the alteration of the salivary composition in patients with Down syndrome which inhibits the development of carious lesions (Davidovich et al., 2010). However, such patients are more vulnerable to presenting deterioration of their periodontal structures, due to their differentiated immune response and their vulnerability to the early establishment of agents that are responsible for the development of periodontal diseases (Morinushi et al., 2006; Nuernberg et al., 2019). The tongue of Down syndrome individuals exhibit an irregular surface with fissures and is characterized by macroglossia (Ghaith et al., 2019; Kaczorowska et al., 2019). However, the tongue dimensions of Down syndrome subjects were found to be relatively increased compared to healthy individuals. The etiology of this pseudo-macroglossia could be attributed to the diminished craniofacial dimensions of the Down syndrome patients enhancing the false perception of an increased tongue

volume (Ghaith et al., 2019; Kaczorowska et al., 2019). Another distinctive characteristic that is worthwhile mentioning is the dryness of the lingual surface which is closely connected with the increased amount of oral breathing that Down syndrome patients exhibit (Shukla et al., 2014). Another region in the orofacial complex that presents morphological differences in individuals with Down syndrome is the hard palate. Although the length and height are similar to healthy controls it appears significantly narrower in relation to the transverse dimension (Abeleira et al., 2015). According to recently conducted research, Down syndrome patients present a normal palatal shape in the first months after birth, but with significantly decreased vertical, sagittal, and transversal dimensions compared to healthy controls (Klingel et al., 2017). Additionally, it has been suggested that morphological deviations such as the narrow shape and the increased depth of the palatal vault could be attained during growth and development (Klingel et al., 2017). In relation to the appearance of fissures in the lips of Down syndrome subjects, one study suggests that these fissures tend to appear more in the lower lip (Al-Maweri et al., 2015). The etiology of those fissures is still unknown, and it is characterized as multifactorial. Some researchers linked the appearance of these fissures to oral breathing and the existence of Candida albicans (Al-Maweri et al., 2015). However, Down syndrome patients often exhibit angular lip cheilitis, which causes significant inflamation of the lips and it is associated with many systemic or infectious conditions (Al-Maweri et al., 2015) (Bilgili et al., 2011, Lugović-Mihić et al., 2018). Finally, the intellectual impairment of Down syndrome subjects is frequently associated with decreased oral hygiene. Consequently, recurrent visits to the dental practitioners must be ensured for the maintenance of an acceptable and viable oral health, which would significantly improve the patient's quality of life (Kusumoto et al., 2020).



Picture 4: Intra-oral characteristics of a patient with Down syndrome (Photos courtesy of Dr. Huseyin Budak).

## 4.2. Cephalometrics

Cephalometrics is attributed to the assessment of cephalograms or the analysis and correlation of orofacial structures depicted in craniofacial radiographs. It has been a fundamental part of orthodontic science and an integral piece of treatment planning. Through the cephalometric analysis, potential treatment modalities are confirmed, and additional information is provided to the clinician frequently clarifying the clinical assessment of the patient.

### 4.2.1. Introduction to cephalometrics

The application of cephalometrics is aiming mainly at the following goals:

1. The classification of the skeletal and dental aspects of the malocclusion,
2. The assessment of the craniofacial anatomical structures before any potential treatment modalities,
3. The investigation of developmental and treatment changes in the patient's craniofacial complex,
4. The identification and evaluation of the severity of the existing problem.



Figure 8: Lateral and frontal cephalometric radiographs

Although some degree of asymmetry can be identified in the lateral cephalometric radiograph, another frontal radiograph is required in order to evaluate with more precision the asymmetry, especially in the transverse dimension.

### 4.2.2. Historical review of cephalometrics

Before the use of cephalometric radiographs, craniometry was implemented for the investigation of the growth and development of craniofacial structures. The origins of craniometry date back to the Hippocratic era of medicine in the 4$^{th}$ century Before Christ (BC) and craniometry still comprise a fundamental aspect of sciences such as anthropology, general and forensic medicine, as well as art (Finlay, 1980). It was the German Anthropological Society 1884 that established the Frankfort plane as a reference for the horizontal orientation of the skull, which was later modified and applied in cephalometrics (Finlay, 1980).

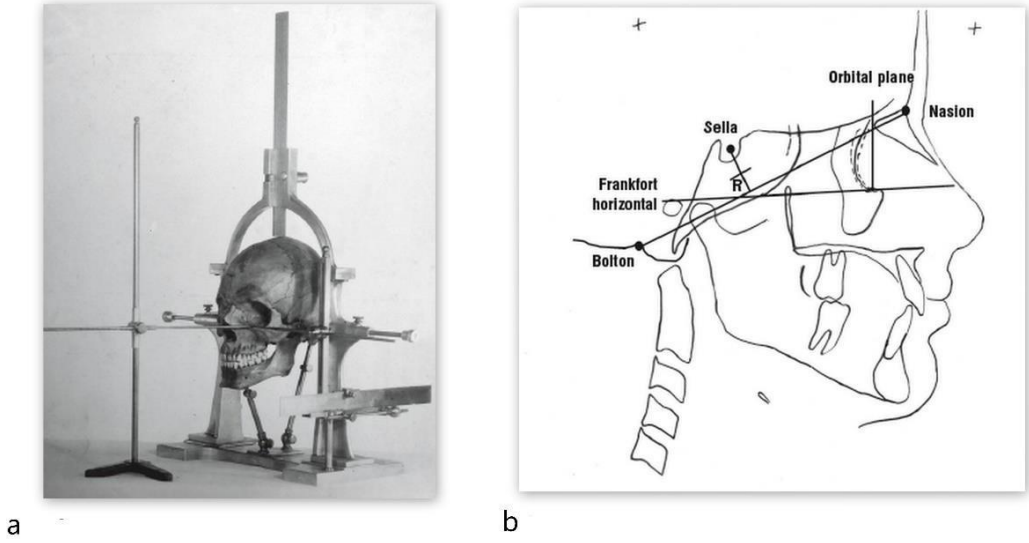


Figure 9: (a) Broadbent craniostat for standardizing skull position and measuring, (b) Frankfort horizontal, Bolton-nasion, and orbital planes (Kula, 2020).

In 1895 Wilhelm Conrad Roentgen discovered the x-rays marking a breakthrough point in the future of craniofacial imaging (Bercovich and Javitt, 2018). In the following

century, cephalometric analysis vastly improved through various landmark identification, development of planes of orientation, and multiple different analytic methods for the evaluation of the growth and development of the craniofacial complex (Kula, 2020).

### 4.2.3. Patient positioning

The head of the patient undertaking the lateral cephalogram is set with the left-hand side of the face next to the image receptor. The midsagittal plane must be located parallelly to the image receptor and the Frankfort plane parallel to the floor level (Broadbent, 1931). The cephalostat stabilizes the patient's head with the help of two ear rods and a nasion guide in order to minimize any involuntary movement. The radiation source is located 60 inches (approximately 1,5 m) from the midsagittal plane, whereas the distance between the receptor and the midsagittal plane must be 6 inches (approximately 15 cm) (Kula, 2020). The center of the radiation beam should pass through the patient's external auditory meatus. Finally, it is worthwhile mentioning that the anatomical structures located further from the receptor are presented with increased magnification compared to those close to the receptor due to projection geometry.

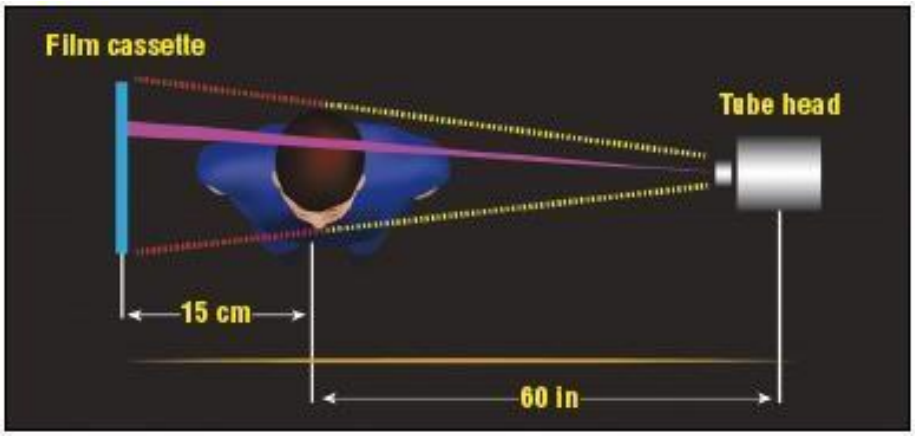


Figure 10: Patient positioning for the purposes of lateral cephalometric imaging (Kula, 2020).

### 4.2.4. Anatomical structures

#### 4.2.4.1. The cranial base

In terms of anatomy, the cranial base is consisted of three areas: the anterior, the middle, and the posterior cranial base. The anterior area contains the frontal, ethmoid, sphenoid, and sella turcica regions. Initially, the cranial base is formed by endochondral ossification where cartilage is replaced by osseous tissue during growth. Nevertheless, some growth centers of cartilaginous origin named synchondroses maintain their activity and exhibit ossification at various time points during growth. The anterior region of the cranial base completes its most considerable part of growth prior to other facial osseous structures.

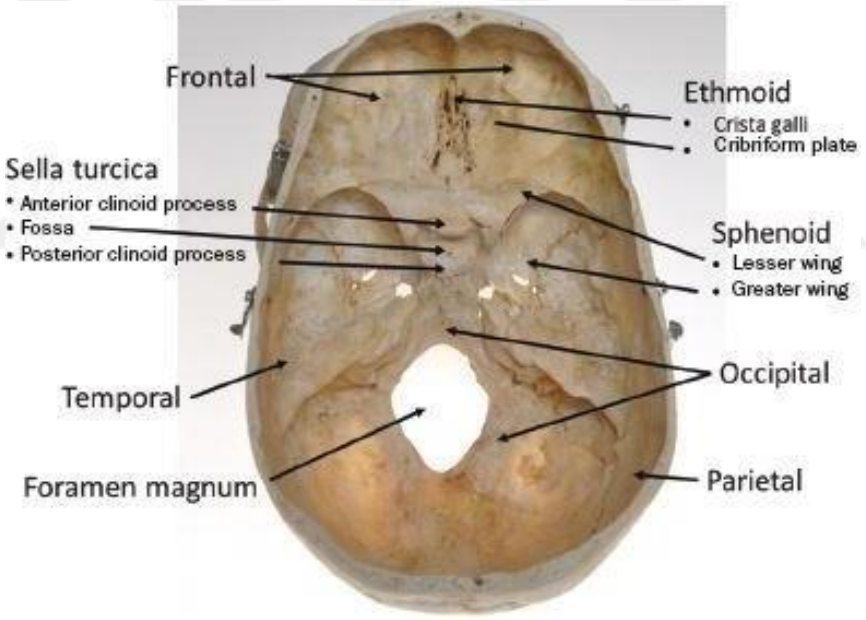


Figure 11: Intracranial anatomical structures (Kula, 2020).

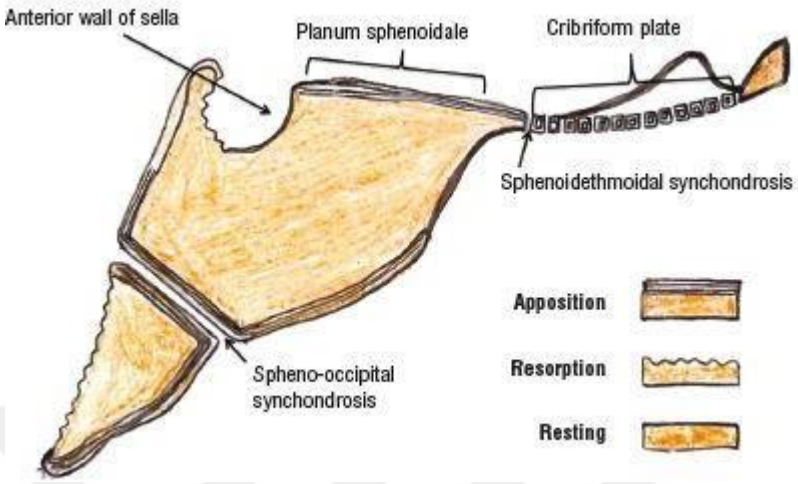


Figure 12: Superior view of the skull representing the regions of the cranial base exhibiting various degrees of stability. The regions with green are stable after 7 years of age. The region in pink presents minimal growth potential after the age of 6 years and completely no growth after 14 years (Kula, 2020).

According to Melsen the internal region of the frontal bone and the cribriform plate present stability after 6 and 7 years of age in both sagittal and vertical dimensions, with the anterior sella region exhibiting the anatomical structure with the most stability after 5 years of age (Melsen, 1971).

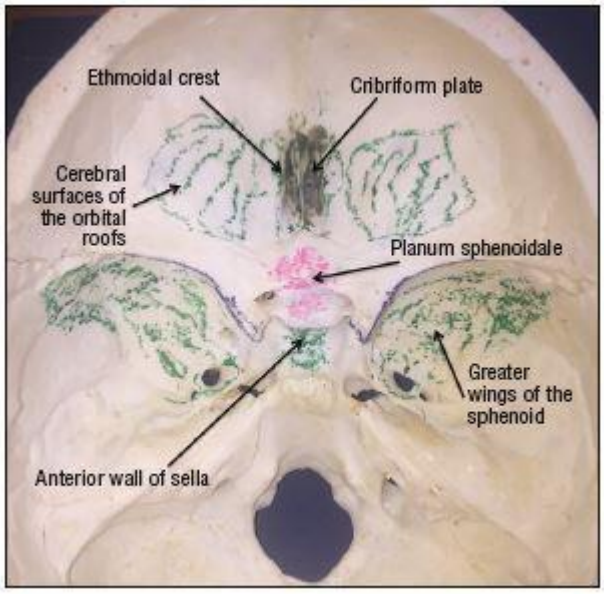


Figure 13: The midsagittal anatomical region of the cranial base (Kula, 2020).

According to research conducted by Arat et al., the basion is the anatomical landmark that expresses the least amount of stability, together with the nasion in both sagittal and vertical dimensions due to the growth and development of spheno-occipital synchondrosis and frontal sinus (Arat et al., 2010). Finally, according to a systematic review conducted by Afrand et al., the sphenoid and ethmoid areas fulfill their developmental capability prior to 7 and 4 years of age respectively, whereas the nasion moves anteriorly and sella turcica posteriorly due to frontal sinus growth (Afrand et al., 2014).

#### 4.2.4.2. Tracing of the cranial base

The tracing of the anterior cranial base begins from the posterior clinoid process, continues anteriorly outlining the sella turcica, moving up to the anterior clinoid process, passing to the superior region of the sphenoid bone and the ethmoid bones, to the posterior region of the frontal bone (Figure 14). Planum sphenoidale is formed by the superior regions of the ethmoid and the sphenoid bones. It is worthwhile mentioning that frequently planum sphenoidale is poorly differentiated due to the increased radiographic translucency of the ethmoid bone.

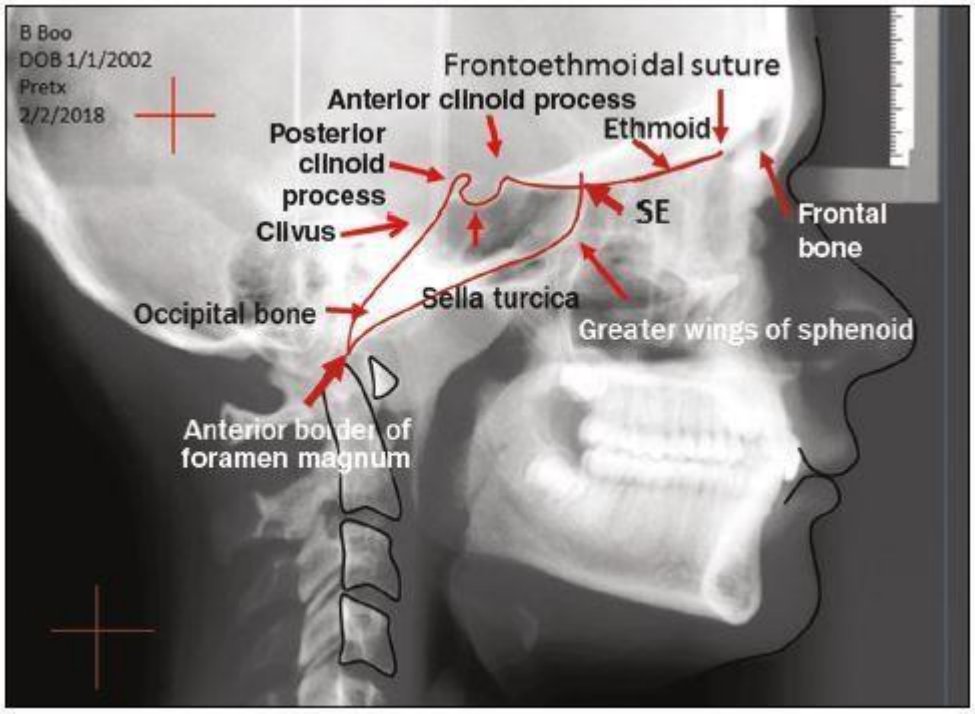


Figure 14: Anterior cranial base tracing, including occipital, sphenoid, and ethmoid bones (Kula, 2020).

The tracing of the posterior cranial base begins from the most inferiorly positioned point of the posterior clinoid process passing in a posterior and inferior direction from the sphenoid and occipital bone areas reaching the anterior region of the foramen magnum. The area between the posterior clinoid process and the foramen magnum is the clivus. Furthermore, the connection between the sphenoid and the occipital bones is named spheno-occipital synchondrosis and it consisted of cartilaginous tissue. The aforementioned synchondrosis is considered a growth site. Until the age of 13 years, the spheno-occipital synchondrosis is depicted as unossified radiographically, whereas later is ossified and appears closed. The radiographic finding of an open spheno-occipital synchondrosis indicates potential growth in the vertical as well as the sagittal levels. The most inferiorly positioned point of the occipital point is named basion, and it could be identified relatively easier by the demarcation of the most superior region of the odontoid process, which lays just a little inferiorly. The anterior region of the occipital bone is traced, as well as the sphenoid bone until the area of planum sphenoidale (Figure 15).

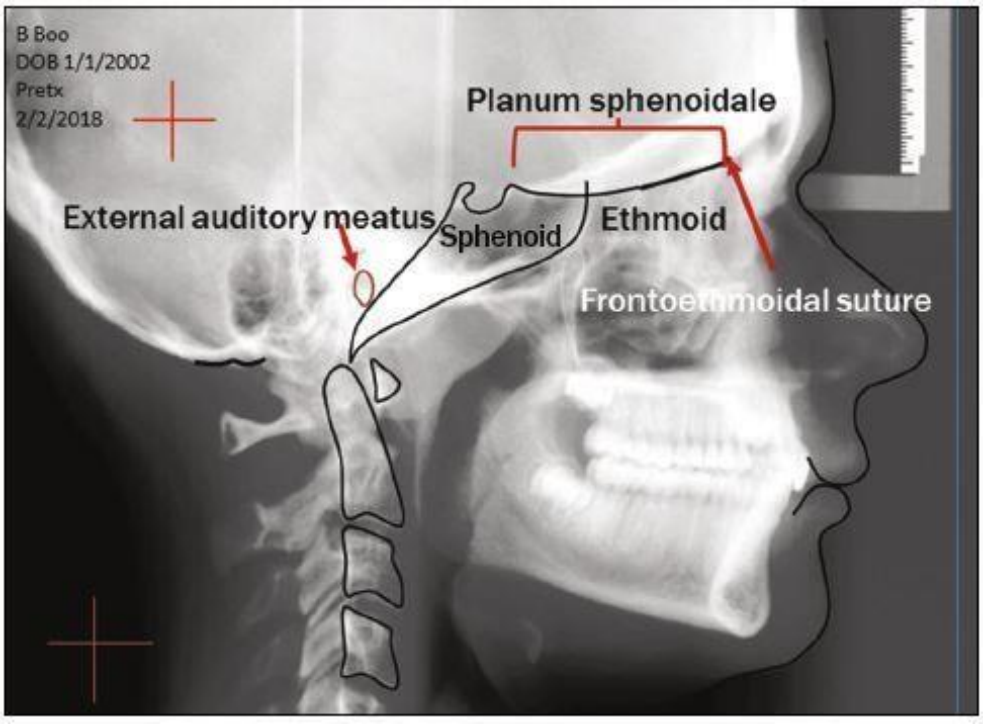


Figure 15: Tracing of the external auditory meatus. Identification of planum sphenoidale as the most superior part of sphenoid and ethmoid bones (Kula, 2020).

Moreover, on the occasion that the greater wings of the sphenoid bone appear as double, the tracing line must be in the mean distance between the two osseous structures. The opening of the external auditory meatus located in the temporal bone is traced (Figure 15). Usually, the external auditory canal is recognized as a round radiolucent region located posteriorly of the condyle and at a similar vertical level. It is worthwhile mentioning that in many patients two radiolucent regions are depicted radiographically making the precise identification considerably challenging. One radiolucent area is the internal auditory meatus, while the other is the external auditory canal.

#### 4.2.4.3. Sella turcica

Sella turcica is an anatomical structure commonly depicted in lateral cephalometric radiographs. It provides a plethora of diagnostic evidence often related to hypophyseal pathologic situations, as well as to syndromes affecting the craniofacial complex. Morphological alterations in the sella turcica region may indicate pathological situations often that go misdiagnosed or undiagnosed at all. Thus, the clinicians should be familiar with the depiction of sella turcica's anatomy in lateral cephalometric radiographs as well as the morphological variations of the region (Friedland and Meazzini, 1996; Feldkamp et al., 1999; Alkofide, 2001). According to the literature, the vertical dimensions of sella turcica range from 4 to 12 mm, whereas sagittal dimensions range from 5 to 16 mm (Silverman, 1957; Choi et al., 2001; Axelsson et al., 2004; Jones et al., 2005). Alterations in the morphological structure of the sella turcica usually accompany an underlying pathology and increases in size are the most common finding. The most frequent etiologic factors for changes in the sella turcica are intrasellar adenomas and empty sella syndrome (Weisberg et al., 1976; Dostálová et al., 2003; De Marinis et al., 2005). Other more scarce pathological conditions that could induce sella turcica enlargement are Rathke's cleft cysts and aneurysms (Swallow and Osborn, 1998). A considerable decrease in sella turcica size could be caused by primary hypopituitarism, growth hormone deficiency, Williams syndrome, and Sheehan's syndrome (Dejager et al., 1998; Axelsson et al., 2004). The majority of the aforementioned conditions may possibly lead to pituitary necrosis and hemorrhage which demands immediate care. Additionally, other pathological conditions

could affect the sella turcica dimensions such as myelomeningocele and Down, Williams, and Seckel syndromes (Russell and Kjaer, 1999; Kjaer et al., 2001; Axelsson et al., 2004). Finally, in previously conducted studies the sella shape has been subjectively classified as circular, oval, shallow, and J-shaped. Moreover, after evaluation of the anatomical structure of sella turcica, morphological variations have been reported such as the oblique anterior wall, sella turcica bridge, double contour of the floor, distortions, and pyramidal shape of the dorsum sella (Choi et al., 2001; Axelsson et al., 2004). It is worthwhile mentioning that sella bridging is found significantly more in patients characterized with craniofacial anomalies whose severity requires a combination of maxillofacial surgery and orthodontics (Becktor et al., 2000; Jones et al., 2005).

### 4.3. Geometric Morphometrics

Cephalometric analysis is frequently implemented for the description of shape. Several linear and angular measurements are commonly used for the description of the craniofacial complex aiming to analyze and classify the orofacial features of each subject. Thus, the clinician gains the ability to set particular treatment goals, choose between different types of treatment, and often improve the predictability of the available treatment modalities. Nevertheless, conventional cephalometric analyses present specific disadvantages regarding their suitability as a method for measuring shape because they depict only an incomplete and sectional definition of shape (Moyers and Bookstein, 1979). Furthermore, the reference structures such as the cranial base, Frankfort horizontal, etc. are often perplexed by bias. For instance, it is generally accepted that the angle between the sella, nasion, and A points (SNA) depicts the sagittal position of the maxilla due to the fact that the cranial base is thought-out “stable”. However, two of the points defining the aforementioned angle (sella, nasion) are defined in the cranial base, so the assumption that the stability of the SNA measurement is affected more from the cranial base rather than point A would seem more logical (Halazonetis, 2004). The nature of the conventional analyses and the bias regarding the reference structures lead to the following issues:

1. The results of the measuring process or their interpretation are frequently conflicting with each other.

2. Multiple measurements are often required for the precise analysis and diagnosis of every patient.
3. The comparison of two different patients based on those measurements is often superficial.
4. Classifying all the subjects based on a limited group of possible measurements might be biased by the initial selection.

Other morphometric modalities that undertake the aforementioned issues could be more precise for investigating biological shape patterns. Morphometric methods like Procrustes superimposition and principal components analysis (PCA) are increasingly used recently in various fields of biological sciences including orthodontics with significant success and precision providing indispensable data for the researchers (Bookstein, 1992; Halazonetis, 2004; Kouli et al., 2019; Andredaki et al., 2007).

### 4.3.1. Description of shape and Procrustes superimposition

The shape could be described as the geometric data that are remaining after the removal of any effects caused by translation, rotation, and scale (Halazonetis, 2004). For comparison of two shapes, their size is initially adjusted, and then they are superimposed. The remaining changes are attributed to the shape disparities. Those differences between the two shapes being investigated can be assessed by measuring the distance among the equivalent points of the superimposed shapes. In the majority of the studies implementing cephalometric analysis, the size aspects are being surpassed by using angular measurements. For example, when linear measurements are needed, size modification is commonly performed by scaling with reference to the size of a specific landmark (e.g., the cranial base) or in relation to age. However, this solution possesses some disadvantages due to the fact that the anatomical structure implemented for size adjustment might present significant differences among patients. An alternate approach could be scaling the cephalometric tracing with reference to the centroid size. The centroid of a shape is defined as the average of all landmark points (named as well as the “center of gravity” of the shape), whereas the centroid size is the square root of the sum of the

squared distances of each landmark point to the centroid (Halazonetis, 2004). Following the size adjustment, alignment of the shapes is needed in order to remove any translational and rotational effects. In the field of orthodontics, various methods of superimposing two cephalometric tracings are being used (Figure 16). The choice of the superimposition method is fundamental for interpreting the shape differences, which are being measured by the distances between the landmark points of the tracings which are being analyzed. In figure 16a the shape difference is increased compared to figure 16b, due to the fact that the sum of distances among equivalent points is increased. It is quite evident that the etiologic factor of the difference in the sum of distances attributes to the translational and rotational factors that have not been modified. Aiming for the optimal superimposition a mathematic resolution could be applied, which would minimize the distances between points by modifying translation and rotation accordingly. There is a variety of criteria that could be applied for accomplishing the aforementioned goal, but the most frequently implemented criterion for minimizing the sum of squared distances between points is Procrustes superimposition.

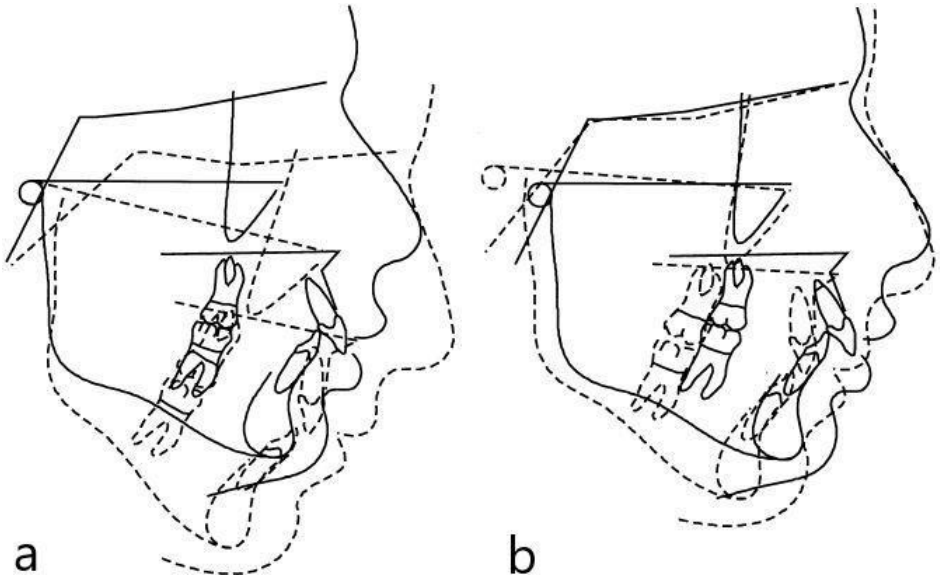


Figure 16: (a) Superimposition at arbitrary position and orientation, (b) Superimposition on anterior cranial base (Halazonetis, 2004).

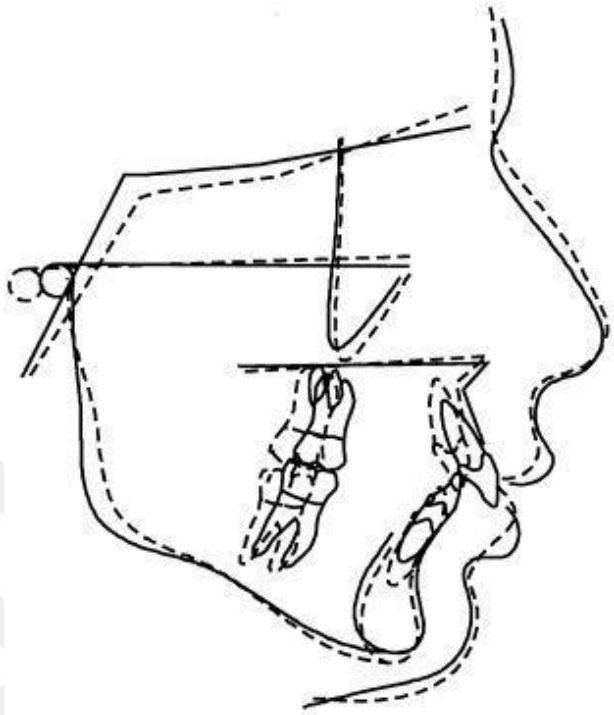

Figure 17: Tracings of figure 16 superimposed with the implementation of Procrustes method (Halazonetis, 2004).

Procrustes superimposition is a geometric morphometric method, which resizes two or more shapes in relation to the same centroid size, and finally aligns them minimizing the sum of the squared distances between points. Procrustes superimposition comprises a modality that aims to diminish the translational, rotational, and scaling effects in order to present genuine shape differences. This method diverges from the conventional cephalometric superimposition modalities in the following aspects:

1. The cephalometric tracing shapes are being resized aiming for optimal fitting.
2. All landmark points are being analyzed with equality.
3. No predefined conditions require that the corresponding landmark point should be coinciding.

In figure 17 the tracings of figure 16 are superimposed with the Procrustes method.

### 4.3.2. Shape variability and average shape considerations

As it is widely accepted when biological variables such as shape are analyzed, the average shape and the variability of shape of the investigated population need to be calculated. In Figure 18 an example of a sample of cephalometric tracings superimposed by Procrustes superimposition in combination with their average shape is exhibited. However, the most challenging aspect is the estimation of shape variability. The average is of limited use on its own, due to the fact that it does not exhibit the specific amount of dissimilarity between an individual patient and the average shape. In Figure 18 the sample's variability around the mean is presented by the scatter of the points. The location of every point may differ in x and y directions, and on many occasions, the number of the variables which depict variability may be extremely high.

#### 4.3.2.1. Principal component analysis (PCA)

A statistical process that can help with decreasing the number of variables is principal component analysis (PCA). This procedure is based on the fact that the points are dependent on one another due to the fact that they are part of a constant biological body. For example, a subject with increased vertical dimension is anticipated to have nasion point located superiorly to the average and the menton point inferiorly to the average. In contrast, a patient with decreased vertical dimensions will probably present reversed characteristics. Such correlations among the positions of the points are employed by principal component analysis to reach a particular set of variables which are called principal components (PCs).

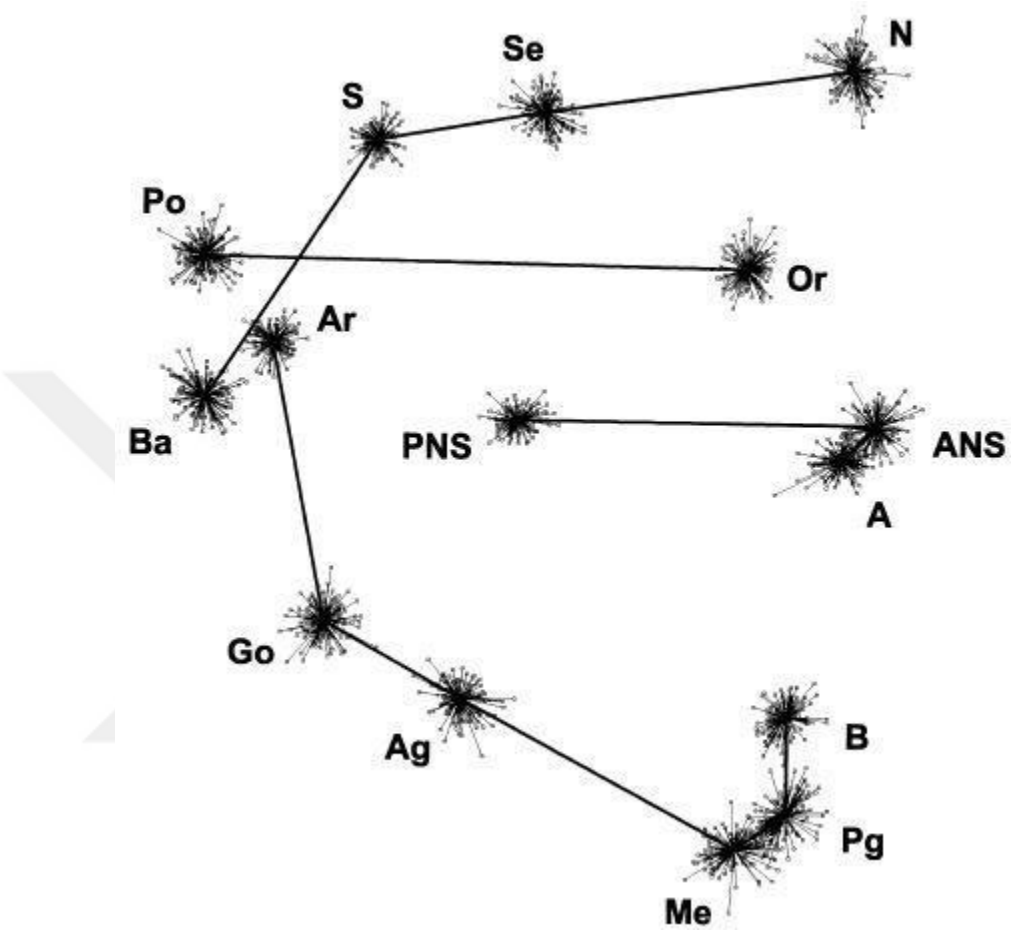


Figure 18: Average shape and scatter of a sample with multiple tracings. Procrustes superimposition has been implemented (Halazonetis, 2004).

Every principal component presents a particular pattern of shape. For example, the first component could exhibit the vertical facial dimension, while the second could represent the sagittal dimension (Halazonetis, 2004). Furthermore, the components of PCA are derived through statistical analysis and not from biological deliberations. Their properties could be summarized as follows:

1. They are not related statistically to each other.
2. Every component presents in decreasing order a segment of the sample's variability (the first component exhibits the greatest part of the variability, the second component the second highest, etc.).
3. Every component comprises a linear consolidation of the initial variables (the variability of each point is represented along the x and y-axis).

One of the biggest advantages of principal component analysis (PCA) is that the principal components (PCs) are arranged in order of decreasing significance. Thus, only the PCs which comprise the most significant section of the whole variability can be kept, and the rest can be abandoned. With this methodology the total number of variables which is often extremely large can be easily reduced, easing the task of the researcher. In figure 19 an example of the shape pattern is visualized with the help of principal component analysis. The average shape of the sample is depicted in the middle, as well as the shapes which were generated by the first three principal components to values equal to standard deviations in both directions (positive and negative) (Halazonetis, 2004; Andredaki et al., 2007). It is evident that the first PC represents the differences in the vertical dimension. The decreased values present an increased anterior facial height pattern, whereas high values visualize a decreased anterior facial height pattern. The second PC is related to the sagittal dimension of the maxilla. Class II pattern is characterized by lower values, while higher values correspond to Class III skeletal pattern. Finally, the third PC is associated with the gonial angle. A reduced value corresponds to a low gonial angle resulting in increased posterior facial height, while the opposite is depicted for high PC values (Halazonetis, 2004).

#### 4.3.2.2. Application of principal component analysis in cephalometric analysis

The shape of the craniofacial complex of a subject can be evaluated by the principal components (PCs) and by the placement of the subject in the optimal position of the population's shape-space. The first principal component depicts the overall shape pattern of the population, whereas the next PCs focus on more specific aspects.

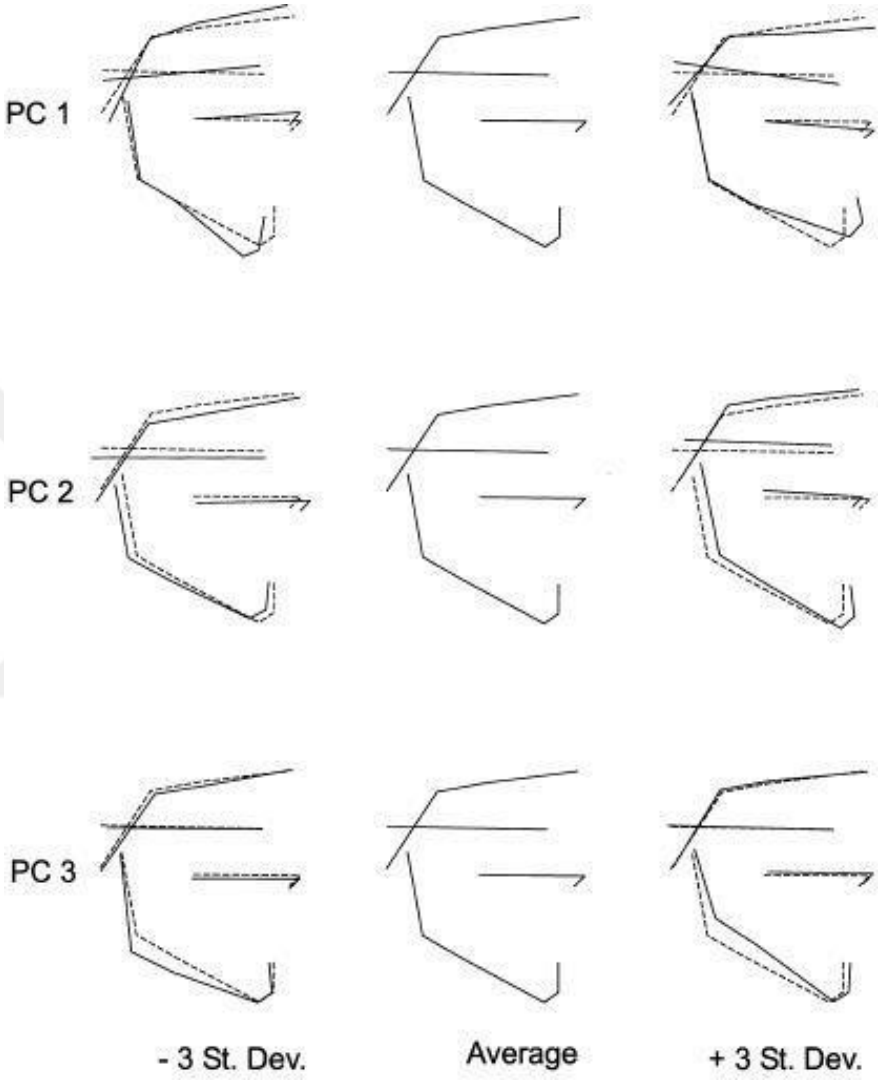


Figure 19: Shapes exhibiting the variance of the first three PCs. The average shape is warped with the application of each principal component equal to three standard deviations (Halazonetis, 2004).

In general terms, two or three PCs are enough for the overall classification. However, these are enough for the researcher to draw important conclusions regarding the craniofacial shape pattern of the investigated group of patients (Halazonetis, 2004).

# 5. MATERIALS AND METHODS

## 5.1. Patient Selection

For this retrospective study, lateral cephalometric radiographs of subjects with Down syndrome and healthy individuals treated in the Department of Orthodontics, Faculty of Dentistry, Marmara University were included.

The size of the sample for the present study was calculated by looking at the sella anterior height, sella midpoint height, sella area, and sella maximum height between subjects with Down syndrome and healthy controls, with differences in the mean diameter of 1,27 mm, 0,92 mm, 8,62 mm² and 0,99 mm respectively, and differences in the standard deviation of 0,04 mm, 0,04mm, 0,02 mm² and 0,02 mm respectively, alpha of 0,05 and power 80%. The necessary sample size was determined to be 24 subjects in each group. The inclusion criteria implemented for the present study were the following:

- Down syndrome group inclusion criteria:

1. No history of any surgical operation in the craniofacial complex,
2. None of the subjects were institutionalized,
3. Moderate to high cooperation with the clinician who was responsible for their orthodontic treatment,
4. Cephalometric radiographs of acceptable quality, Frankfort horizontal plane or intention parallel to the floor level, dentition positioned in central occlusion, obtained prior to any orthodontic treatment.

- Healthy control group inclusion criteria:

1. Dental and skeletal Class I relationships,
2. Exact matching for age and sex with the Down syndrome group

3. Availability of cephalometric radiographs obtained prior to the initiation of any orthodontic treatment,
4. Absence of any pathological growth conditions, hormonal treatment, signs of growth impairment (short stature),
5. Absence of cleft lip and/or palate, malformations, and syndromic diseases.

According to the aforementioned inclusion criteria, 24 patients (12 males and 12 females; mean age: 11,72 years) diagnosed with Down syndrome were compared with 24 healthy individuals (12 males and 12 females; mean age: 11,68 years). In agreement with the protocol of the Department of Orthodontics, Faculty of Dentistry, Marmara University all the subjects, their parents or their legal guardians included in the present study signed the informed consent forms. Finally, this study was approved by the Ethical Committee of the Institute of Health Sciences of Marmara University (07.10.2021, 2021-19, Istanbul/Turkey).

**5.2. Data Collection**

The cephalometric radiographs for this retrospective study as mentioned above were selected from the patient archive of the Department of Orthodontics, Faculty of Dentistry, Marmara University. Each patient undertook his/her cephalometric radiographic imaging in the Department of Radiology, Faculty of Dentistry, Marmara University according to a specific protocol in order to ensure sufficient precision and quality. The patients were set in an upright position and asked to look at their own eyes in a mirror located at a 2-meter distance in order to endure a natural head position. Moreover, the subjects were instructed to swallow and bite in maximum intercuspation in order to ensure that their mandible is located in centric occlusion. The subjects were asked to normalize their breathing and in a time period of 15 seconds after swallowing the lateral cephalometric radiograph was acquired ensuring a constant positioning of the mandible as well as the tongue.

Finally, if the positioning of the subject was judged as poor or any involuntary movement occurred which would compromise the quality of the radiograph the procedure was repeated one more time. If the participant failed to comply on the second try, the procedure

was aborted due to the fact that the obtainment of an unreliable cephalometric radiograph would not provide sufficient diagnostic information that would outweigh the risk-benefit ratio of exposing the subject to radiation. The orthopantomogram used for the acquisition of all the lateral cephalometric radiographs was the same (Promax, Planmeca Oy, 0080 Helsinki, Finland), whereas the radiographic techniques that were implemented were similar for the participants (75 kV, 4,1 seconds, 10 mA).

### 5.3. Data Assessment

The cephalometric radiographs of both subjects with Down syndrome and the control group were imported into the Nemoceph (Nemotec, Madrid, Spain) software in the department, and were adjusted for magnification and calibration prior to analyzing. Following the completion of the magnification and calibration processes the cephalometric radiographs were imported into Viewbox 4 cephalometric software (dHAL Software, Kifissia, Greece). The methodology of the present study was based on a combination of the methods of Andreadaki et al., and Antonarakis et al. (Figure 20) (Andredaki et al., 2007; Antonarakis et al., 2020).

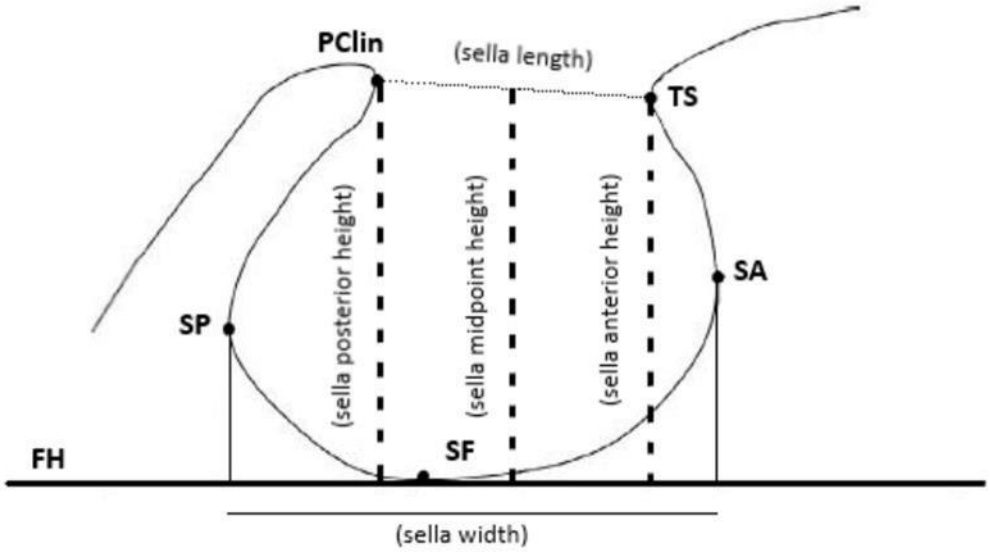


Figure 20: Tracing of sella turcica contour with the definition of the following anatomical landmarks and planes: posterior clinoid process (PClin), tuberculum sella (TS), sella posterior (SP), sella anterior (SA),

sella floor (SF), Frankfort plane (FH). The following linear measurements were calculated: sella width (SP to SA, parallel to FH), sella anterior height (TS to SF, perpendicular to FH), sella midpoint height (midpoint between PClin and TS to SF), sella posterior height (PClin to SF, perpendicular to FH), sella length (PClin to TS).

First of all, the contour of sella turcica was traced (Figure 21), starting from the posterior clinoid process (PClin) and reaching to tuberculum sella (TS). Nine extra points were outlined by the cephalometric software along the contour of sella turcica. Furthermore, within the sella turcica contour, the most posteriorly (SP: sella posterior) and anteriorly (SA: sella anterior) points were defined, as well as the most deeply located point (SF: sella floor). The aforementioned points were outlined by the cephalometric software by implementing the Frankfort horizontal plane (FH) as a reference plane.

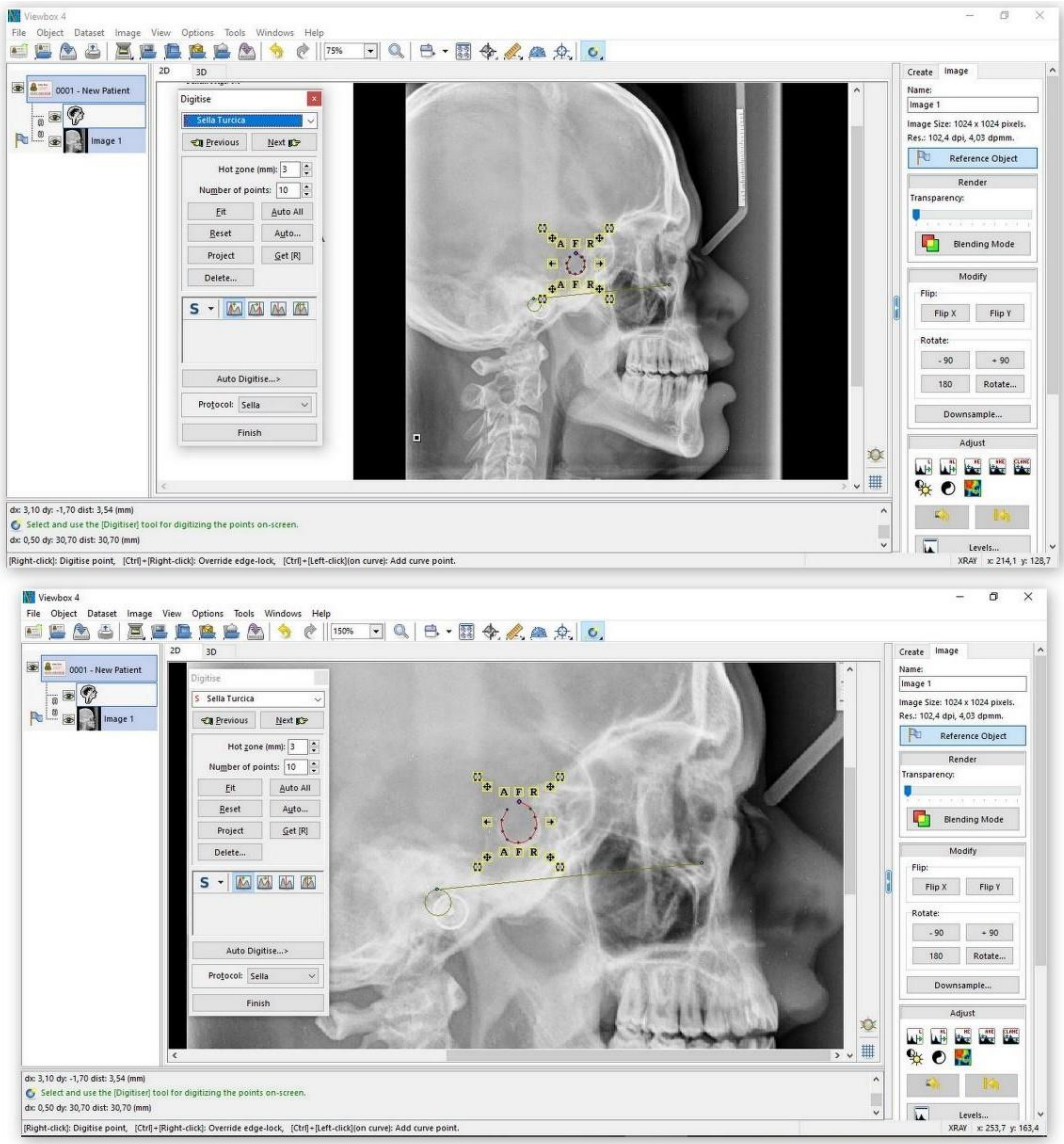


Figure 21: Initial tracing of sella turcica contour in Viewbox 4 software.

Furthermore, the following measurements were calculated (Figure 20):

1. Sella width: The largest sagittal dimension measured from sella posterior (SP) to sella anterior (SA) parallel to Frankfort horizontal plane (FH).
2. Sella anterior height: The distance from tuberculum sella (TS) to the sella floor (SF) perpendicular to FH.
3. Sella midpoint height: The distance from the midpoint between posterior clinoid process (PClin) to tuberculum sella (TS) to sella floor (SF) perpendicular to FH.
4. Sella height posterior: The distance from posterior clinoid process (PClin) to sella floor (SF) perpendicular to FH.
5. Sella length: The distance from posterior clinoid process (PClin) to tuberculum sella (TS).
6. Sella maximum height: The distance from the most superiorly located point to the sella floor (SF) perpendicular to FH.
7. Sella area: The area located within the contour of sella turcica and capped by a line from posterior clinoid process (PClin) reaching tuberculum sella (TS).

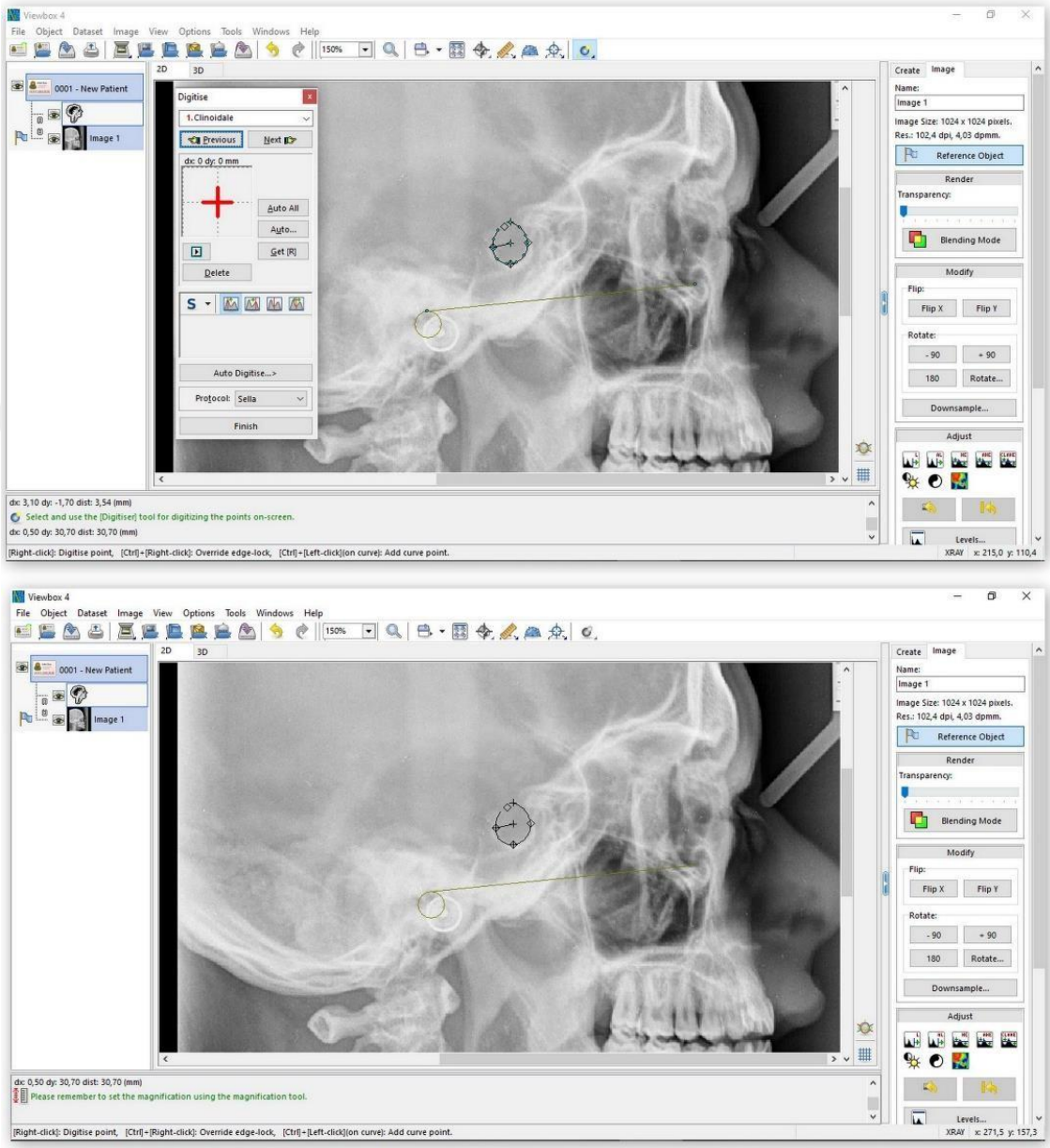


Figure 22: Finalizing tracing of the sella turcica contour in Viewbox 4 software.

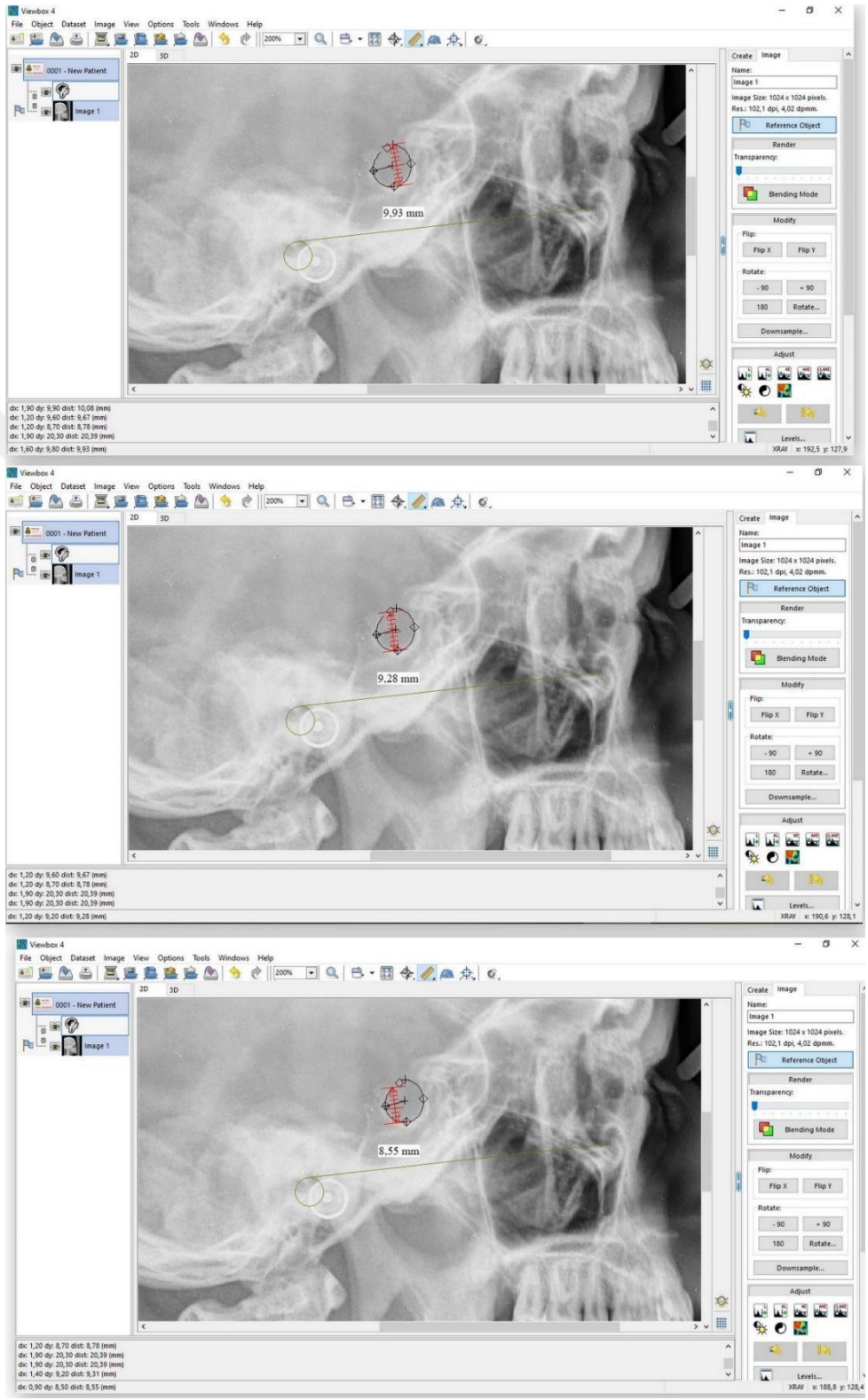


Figure 23: Measurement of the anterior, midpoint, and posterior sella height in Viewbox 4 software.

Furthermore, the tracing of sella turcica was extracted as shown in Figure 24.

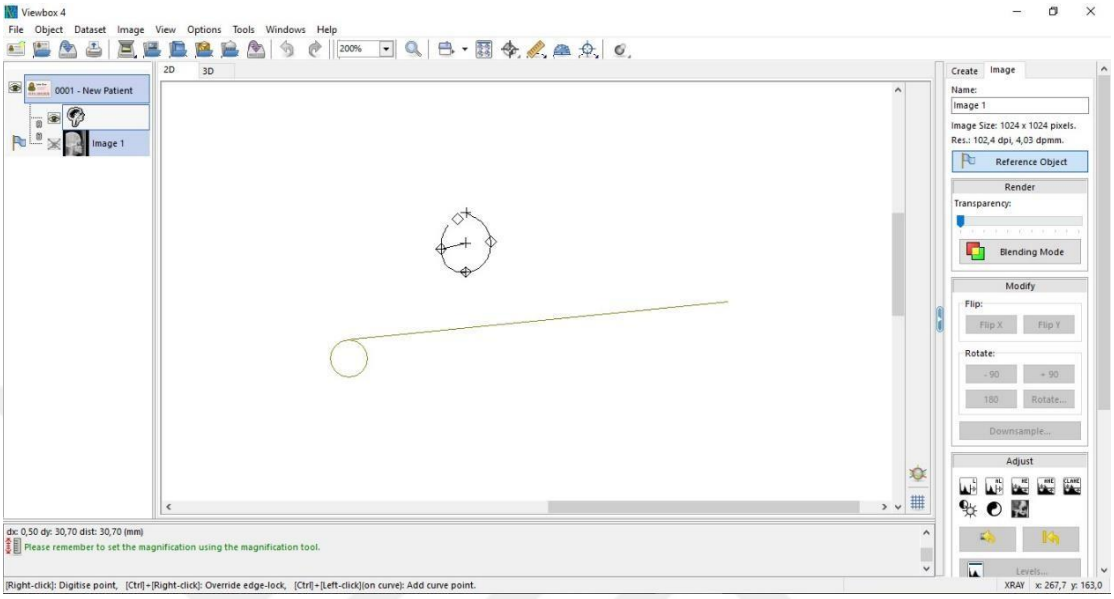


Figure 24: The extracted sella turcica tracing with the Frankfort horizontal plane (FH) as reference plane.

All the aforementioned measurements were calculated both manually (e.g. Figure 23) as well as automatically (Figure 25) from the software in order to enhance the precision of the present study.

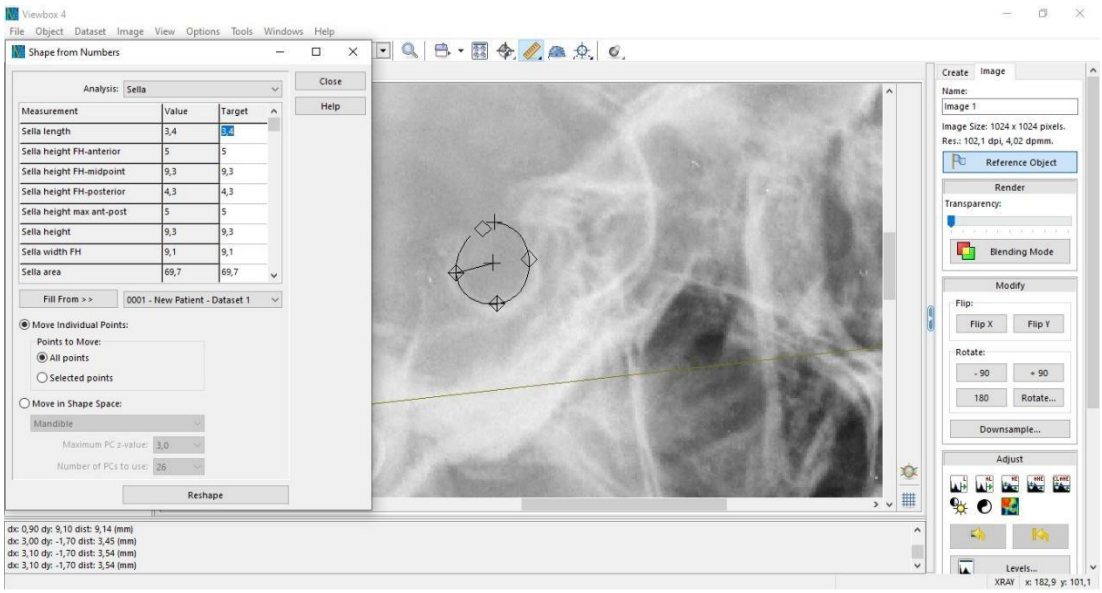


Figure 25: Automatic calculation of the sella turcica dimensions from Viewbox 4 software according to the anatomical landmarks defined.

After the cephalometric tracing and calculating the conventional measurements of both Down syndrome subjects and the control group, all the extracted tracings were used for the calculation of the average sella shape of the entire sample in both Down syndrome subjects and the healthy control group, separately.

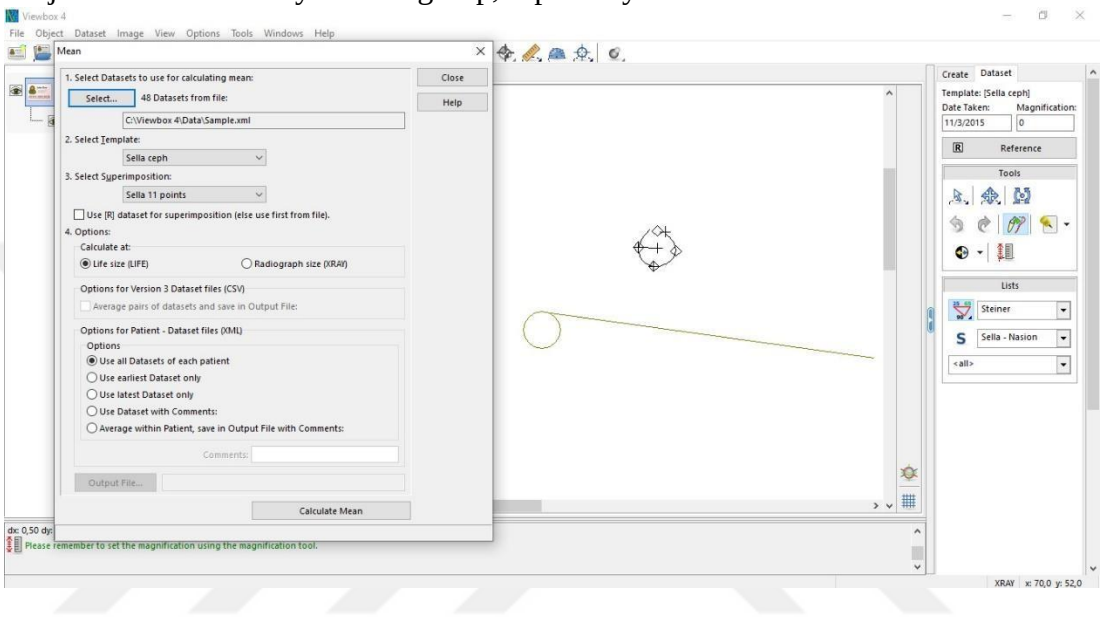


Figure 26: Calculation of the sella turcica average shape of the entire sample of the study with Viewbox 4 software.

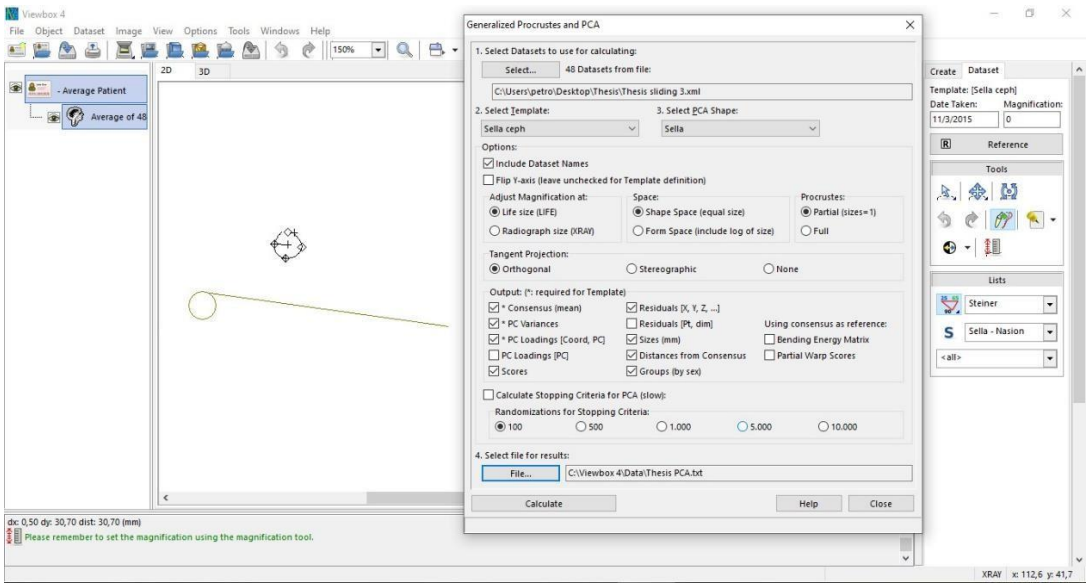


Figure 27: Sella shape morphometric analysis with the implementation of Procrustes superimposition and principal component analysis (PCA) in Viewbox 4 software.

The shape analysis of sella turcica was performed with the application of geometric morphometric methods and particularly with Procrustes superimposition and principal component analysis (PCA) through Viewbox 4 software (Figure 27) (Halazonetis, 2004; Andredaki et al., 2007). Initially, Procrustes superimposition was implemented for the registration of all the tracings depicting the contour of sella turcica in order the calculation of the average shape for the Down syndrome subject group and the control group. Moreover, principal component analysis (PCA) was used to the point coordinate residuals for the extraction of the principal components (PCs). Finally for every cephalometric tracing the centroid size calculation was carried out.

### 5.4. Statistical Analysis

Python 3.7 Software (package stats from SciPy v1.6.0 Library) was implemented for conducting the statistical analysis of our data. Independent sample t-tests were applied for the comparison of differences in sella turcica dimensions. Furthermore, dissimilarities between the shapes of sella turcica in subjects with Down syndrome in comparison with the overall population of the present study were attained by permutation tests. These tests were implemented to calculate the Procrustes distance among groups with the Procrustes distance between group means and were performed by the Viewbox 4 software. The error of the present study method was assessed by repeating the cephalometric analysis of the radiographs by the same examiner 2 weeks after the initial measurements. The systematic error was investigated by the application of paired t-tests, whereas the random error was calculated by the implementation of Dahlberg's formula as shown in Figure 28 (Houston, 1983). Statistical significance was set at $p<0,05$.

$$error = \sqrt{\frac{\sum d^2}{2n}}$$

Figure 28: Dahlberg's formula implemented for error calculation in the present study (Houston, 1983).

# 6. RESULTS

## 6.1. Sample Demographics

The present study is consisted of 24 patients with Down syndrome (12 males and 12 females) aged between 8 and 13 years (mean age of 11,72 years), and 24 (12 males and 12 females), (mean age of 11,68 years) gender and age-matched healthy subjects serving as a control group.

## 6.2. Sella Size Analysis

In Table 1, the descriptive statistical analysis of the conventional measurements implemented for the sella size investigation is depicted. Statistically significant differences were found between Down syndrome subjects and healthy controls in relation to sella anterior height, sella midpoint height, sella maximum height, and sella area. Furthermore, all the aforementioned values were significantly increased in the Down syndrome subjects.

**Table 1:** Sella size statistical comparison of Down syndrome subjects with healthy controls

| | **Control group** | | | **Down Syndrome group** | | | |
|---|---|---|---|---|---|---|---|
| | **Mean±SD** | **Min.** | **Max.** | **Mean±SD** | **Min.** | **Max.** | **P value** |
| Sella anterior height (mm) | 6,6±1,1 | 4,6 | 8,8 | 7,9±1,2 | 4,4 | 10,2 | **<0,001*** ** |
| Sella midpoint height (mm) | 6,8±1,1 | 4,8 | 8,7 | 7,7±1,1 | 4,6 | 10,1 | **0,008** ** |
| Sella posterior height (mm) | 7±1,2 | 4,8 | 9,3 | 7,6±1,3 | 4,9 | 9,8 | 0,1 |
| Sella maximum height (mm) | 7,3±1,2 | 4,9 | 9,3 | 8,3±1,2 | 4,9 | 10,2 | **0,007** ** |
| Sella width (mm) | 7,9±1,6 | 5,4 | 11 | 8±1,1 | 4,5 | 9,9 | 0,78 |
| Sella length (mm) | 3,3±1,3 | 1,1 | 5,7 | 3,7±1,2 | 0,6 | 5,6 | 0,29 |
| Sella area ($mm^2$) | 41,3±12,1 | 15,7 | 66,9 | 49,9±12,2 | 15,7 | 70,9 | **0,018*** |

*Independent sample t-tests*, *p <0,05, ** p <0,01, *** p <0,001

### 6.3. Sella Shape Analysis

Principal component analysis (PCA) generated an amount of 22 principal components (PCs) for the 11 points that were implemented for the tracing of the sella turcica contour. The first three principal components (PCs) accounted for 85,8% of the variability of the total samples as shown in Table 2.

**Table 2:** Variance and cumulative variance of the first 10 PCs of shape in percentages.

| Principal Component (PC) | Variance (%) | Cumulative variance (%) |
|---|---|---|
| PC1 | 36,8 | 36,8 |
| PC2 | 30,6 | 67,4 |
| PC3 | 18,4 | 85,8 |
| PC4 | 6,9 | 92,7 |
| PC5 | 3 | 95,8 |
| PC6 | 2,1 | 97,9 |
| PC7 | 0,8 | 98,7 |
| PC8 | 0,5 | 99,3 |
| PC9 | 0,3 | 99,6 |
| PC10 | 0,1 | 99,7 |

In the present study, the first three principal components were investigated to a greater extent, due to the fact that they were the only PCs that were located clearly above the scree point when the screen plot was assessed (Figure 29).

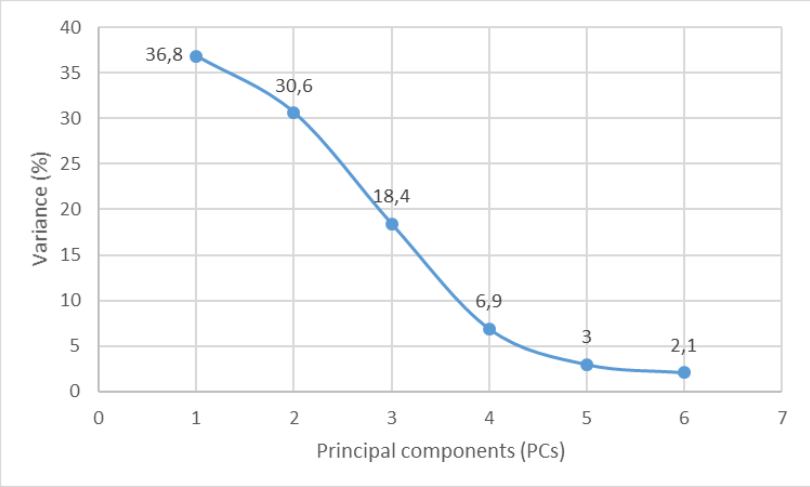


Figure 29: Scree plot of variance and principal components.

Principal component analysis (PCA) depicted a statistically significant difference (P=0,0489, 10 000 permutations) in sella shape between patients with Down syndrome and healthy controls as shown in Figure 30 and Figure 31

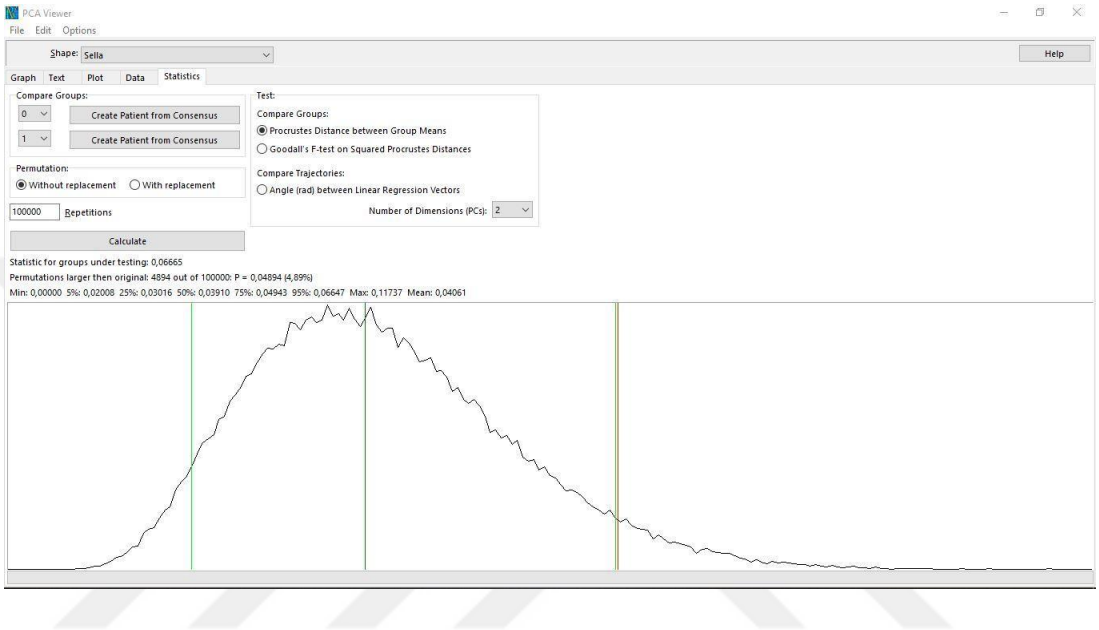


Figure 30: Statistical investigation of principal component analysis of the sample in Viewbox 4 software.

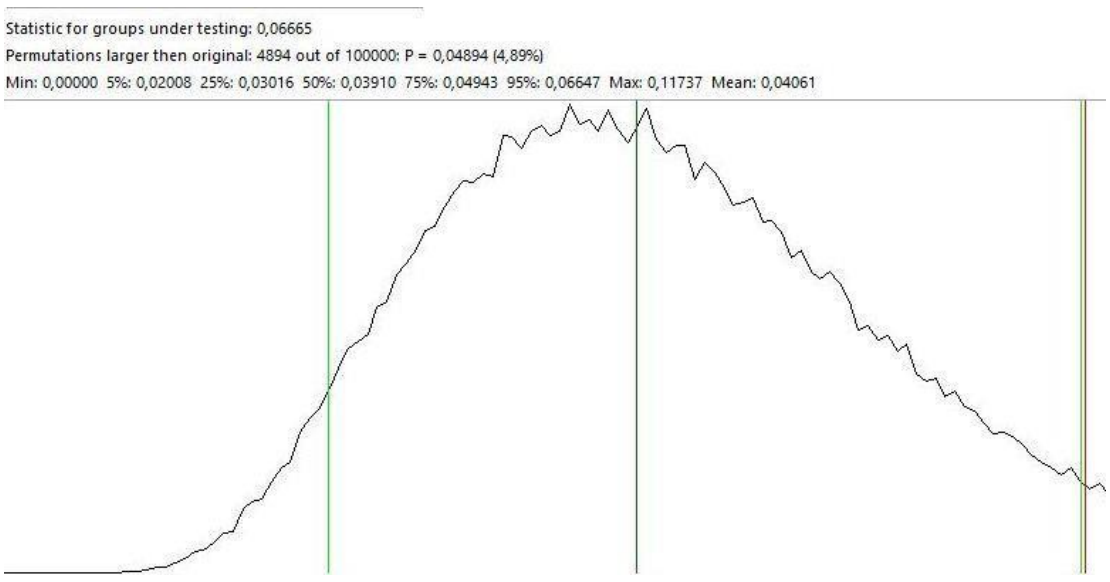


Figure 31: Statistical investigation of principal component analysis of the sample in Viewbox 4 software with increased magnification.

The differences in sella shape between the Down syndrome patients and the control group are visualized as well in the PCA plots in Figure 32

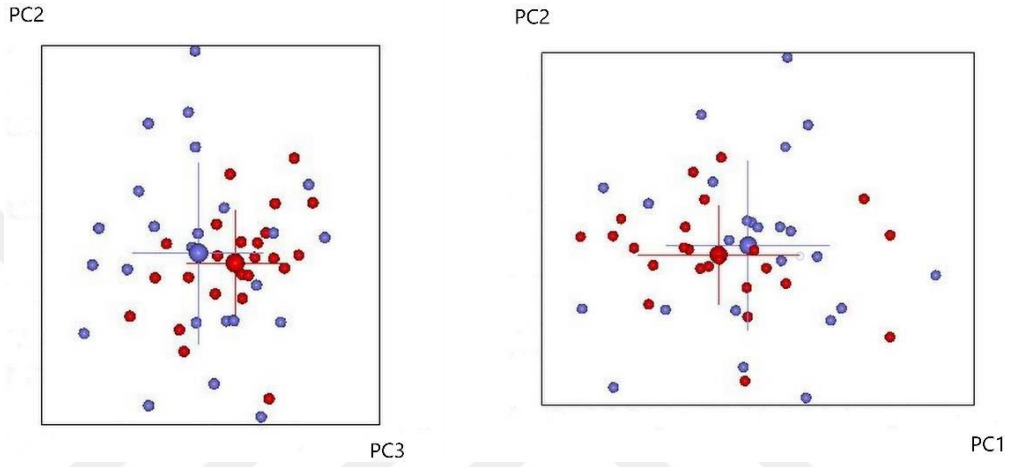


Figure 32: Principal component analysis (PCA) plot for PC1 - PC2 and PC2 – PC3. (Red: Down syndrome subjects, Blue: control group) generated from Viewbox 4 software.

Furthermore, the average sella shape for both the Down syndrome and the control groups as produced from Procrustes superimposition is depicted in Figure 33

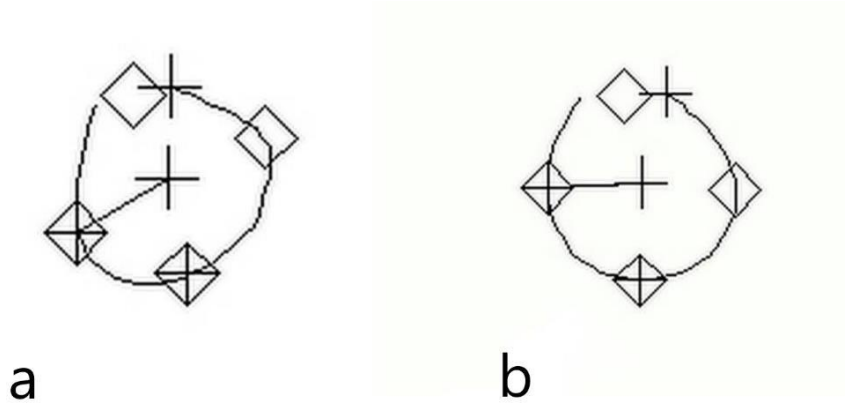


Figure 33: Average sella shape of (a) control group, and (b) Down syndrome group

Finally, a graphic representation of the first three principal components (PCs) of the whole sample is depicted in Figure 34 The effect of every principal component on the sella shape is visualized on every row by three standard deviations (SD) in both directions.

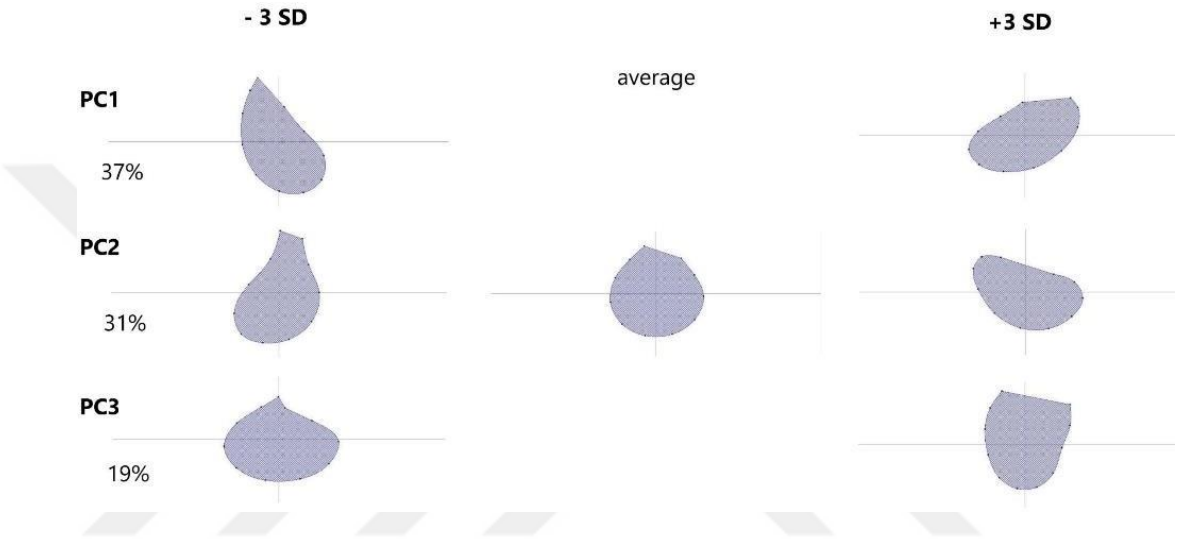


Figure 34: Variability of sella turcica shape of the whole sample as affected from the first three PCs. Average shape is located in the center and the effects of each PC on sella shape in the extremes by 3 standard deviations (+/- 3 SD) on the left and right.

# 7. DISCUSSION and CONCLUSION

The present study presents a comparison regarding the dimensions and shape of sella turcica between Down syndrome subjects and healthy controls where both the height, and the area seem to be increased in Down syndrome patients, as well as the shape and the morphology were found to be different. According to the literature, numerous researchers studied the craniofacial morphology of Down syndrome subjects but there are only two studies up to this date that investigated the morphology of sella turcica (Kjaer and Fischer-Hansen, 1995; Quintanilla et al., 2002; Korayem and AlKofide, 2015; Allareddy et al., 2016; Hasan et al., 2019). However, the existing literature is scarce regarding the evaluation of the shape of sella turcica in patients diagnosed with Down syndrome. To our knowledge, the present study is the only one up to this date that investigated the shape of sella turcica by implementing geometric morphometric techniques.

## 7.1. Sella Dimensions Related to Systemic Conditions

Although sella turcica and pituitary gland begin to form during the $7^{th}$ week of embryonic life, the initiation of pituitary gland formation precedes the one of sella. It needs to be highlighted that any abnormality occurring in this region during embryonic growth, persists for the entire life of the individual (Kjaer et al., 1998; Murray, 2002; Kjaer, 2015). This fact is evident during prenatal investigations of sella turcica in subjects diagnosed with conditions such as lumbosacral myelomeningocele, Down syndrome, and fragile X syndrome, where the same disturbances are evident after birth (Kjaer et al., 1998; Hjalgrim et al., 2000; Kjaer and Hansen, 2000). Moreover, abnormalities in both sella turcica and the pituitary gland are evident postnatally in individuals diagnosed with holoprosencephaly (Kjaer and Fischer-Hansen, 1995). Still, it is not clear in the existing literature if disturbances in the dimensions or shape of sella turcica in subjects with Down syndrome affect the activity of the pituitary gland. However, there have been reports of hypothyroidism in patients with Down syndrome with increased levels of thyroid-stimulating hormone (TSH) and thyroid microsomal antibodies (Smith, 1976; Dinani and Carpenter, 1990; Abdullah et al., 1994; Mıhçı et al., 2010). Furthermore, increased serum

androgen levels were reported in males, as well as greater serum estrogen, prolactin, and gonadotropin were detected in females in comparison to the healthy population (Hasen et al., 1980; Hestnes et al., 1991; Sasagawa et al., 1993).

### 7.2 Discussion of the materials and methods

According to recently conducted research regarding the dimensions of sella turica in subjects with Down syndrome, the present is the only one which implemented geometric morphometric techniques such as Procrustes superimposition and principal component analysis. These techniques present some considerable advantages, which are discussed, bellow (Halazonetis, 2004):

1. Evaluation of the craniofacial shape with a decreased amount of measurements, which are not conflicting due to the fact they are not statistically related with each other.
2. Morphometric techniques are relatively insensitive to errors in the identification of landmarks.
3. The degree of variation from the average can be evaluated with more ease and precision.
4. The shape between subjects can be compared with greater ease (with Procrustes distance).
5. A more precise selection of subjects for research projects in relation to homogeneity of the sample.

The previously mentioned advantages of the geometric morphometric modalities could enhance cephalometric analysis and enable the researcher to reach more precise and clinically valuable conclusions.

## 7.3. Discussion of the Results

### 7.3.1. Sella Size

According to Korayem and AlKofide, sella depth (which is analogous to sella height in the present research) and sella diameter were significantly increased in patients with Down syndrome, whereas sella length did not differ from healthy controls (Korayem and AlKofide, 2015). These results come partially in agreement with the present study, in relation to the sella height values (anterior, midpoint, and maximum height) which were significantly increased, as well as with the sella length which did not present any significant difference. However, the differentiation in the methods which were incorporated for measuring the sella diameter, which differed significantly between the groups according to the study of Korayem and Alkofide, the sella width did not exhibit any significant differences between the subjects of the present study could lead to a clear conclusion regarding the aforementioned parameters (Korayem and AlKofide, 2015). In 2019, Hasan et al. investigated three-dimensionally the morphology of sella turcica in Malay subjects by assessing computed tomography scans (Hasan et al., 2019). They reported significant differences between patients with Down syndrome and healthy controls in the majority of the measurements they conducted except for sella anterior and midpoint height, as well as sella area. However, it is worthwhile mentioning that in the study of Hasan et al. the subjects presented significantly decreased sella dimensions compared with the healthy controls (Hasan et al., 2019), in contrast with the present study where the Down syndrome group presented significantly increased sella dimensions in comparison with the healthy population. Moreover, Suri et al. investigated the craniofacial complex of individuals with Down syndrome and specifically the sagittal length of the pituitary fossa, but the method regarding the determination of this dimension is not clearly explained by the authors (Suri et al., 2010). Also, neither the depth nor the width of sella turcica was investigated in the aforementioned study (Suri et al., 2010). When sella turcica was examined in subjects with other pathological conditions either syndromic (e.g., Williams syndrome) or with multifactorial etiology (e.g., cleft lip and palate) significant dimensional differences were evident (Axelsson et al., 2004; Antonarakis et al., 2020). On

the contrary to the present study, sella turcica in the aformentioned conditions presented decreased sized in comparison with healthy controls (Axelsson et al., 2004; Antonarakis et al., 2020).

### 7.3.2 Sella Shape

The shape of sella turcica in subjects with Down syndrome has been investigated in the studies of Russel and Kjaer, Korayem and AlKofide, and Hasan et al. according to the literature (Russell and Kjaer, 1999; Korayem and AlKofide, 2015; Hasan et al., 2019). The aforementioned studies presented significant differences in the sella shape of Down syndrome subjects compared to healthy controls which come in agreement with the results of the present study. However, a direct comparison of our results is difficult due to the differences in the methodology incorporated for the evaluation of sella shape. It is worthwhile mentioning that these studies incorporated more subjective criteria for the assessment of the shape variability and abnormalities in comparison with the present study where a geometric morphometric evaluation was implemented, which is considered more objective. Thus, the choice of applying geometric morphometrics for shape investigation in the present study was made aiming for an evaluation with less bias, increased objectivity, and easier repeatability if incorporated by researchers in future studies. Finally, it is interesting that the results related to the principal components (PCs) present differences from the studies on sella shape of Antonarakis et al. and Andreadaki et al. on unilateral cleft lip and palate subjects and non-cleft and non-syndromic individuals respectively (Andredaki et al., 2007; Antonarakis et al., 2020). In the first study conducted by Antonarakis et al. the variance of PC1, PC2 and PC3 were 57,8 %, 26,9%, and 8,6% respectively, whereas Andreadaki et al. presented similar values (Andredaki et al., 2007; Antonarakis et al., 2020). Interestingly in the present study the first three PC presented more evenly distributed variance.

Sella turcica size and shape of subjects with Down syndrome differed significantly from healthy controls, however, the clinical significance of the findings of the present study needs to be further investigated. According to a recently conducted research the patients with Down syndrome present distinctive characteristics of the morphology of the

craniofacial complex such as Angle Class III skeletal malocclusion (mainly due to maxillary hypoplasia and midface deficiency) and increased lower anterior facial height (Allareddy et al., 2016). So, the size or the shape of sella turcica in such individuals might be associated with maxillofacial growth in the sagittal and/or vertical dimensions. Nonetheless, this hypothesis still needs to be elucidated by further investigations. Appraisal of the growing tendency of the craniofacial complex in individuals with Down syndrome could be valuable for improving treatment planning, prognosis, and outcome, and the implementation of sella turcica as an index for the potential growth tendency could serve as an invaluable tool in the hands of the clinician. Even if the increased dimensions or the differentiated shape of sella turcica of Down syndrome subjects are attributed to the variations of the anatomical structures when compared to healthy controls, or due to pathological conditions of the pituitary gland further investigation is necessary. Future studies with an increased sample size of both Down syndrome subjects, and healthy controls, with different imaging techniques such as magnetic resonance imaging (MRI) or computed tomography (CT), accompanied by geometric morphometric analysis and endocrinological investigations could elucidate the previously mentioned questions.

### 7.4. Conclusion

- Subjects with Down syndrome present significantly increased sella turcica dimensions when compared with age- and gender-matched healthy population in the aspects of sella anterior height, sella midpoint height, sella maximum height and sella area.
- The application of geometric morphometric techniques for the shape evaluation of sella turcica in subjects with Down syndrome presented significantly different shape pattern of the sella area when compared with age- and gender-matched healthy population.
- Future studies with an increased sample size of both Down syndrome subjects, and healthy controls, with different imaging techniques such as magnetic resonance imaging (MRI) or computed tomography (CT), accompanied by geometric

morphometric analysis and endocrinological investigations could provide more insight in the understanding of the morphological variations of sella turcica regions.

## 8. REFERENCES


Abdul Rahim FS, Mohamed AM, Nor MM, Saub R. Malocclusion and orthodontic treatment need evaluated among subjects with Down syndrome using the Dental Aesthetic Index (DAI). Angle Orthod. 2014;84:600-606.

Abdullah MA, Salman H, Al-Habib S, Ghareeb A, Abanamy A. Antithyroid antibodies and thyroid dysfunction in Saudi children with Down syndrome. Ann Saudi Med. 1994;14:283-285.

Abeleira MT, Outumuro M, Diniz M. Morphometry of the hard palate in Down's syndrome through CBCT-image analysis. Orthod Craniofac Res. 2015;18:212-220.

Afrand M, Ling CP, Khosrotehrani S, Flores-Mir C, Lagravère-Vich MO. Anterior cranial-base time-related changes: A systematic review. Am J Orthod Dentofacial Orthop. 2014;146:21-32.e26.

Al-Maweri SA, Tarakji B, Al-Sufyani GA, Al-Shamiri HM, Gazal G. Lip and oral lesions in children with Down syndrome. A controlled study. J Clin Exp Dent. 2015;7:e284-288.

Alió J, Lorenzo J, Iglesias MC, Manso FJ, Ramírez EM. Longitudinal maxillary growth in Down syndrome patients. Angle Orthod. 2011;81:253-259.

Alkhadra T. Characteristic of Malocclusion among Saudi Special Need Group Children. J Contemp Dent Pract. 2017;18:959-963.

Alkofide E. Pituitary adenoma: a cephalometric finding. Am J Orthod Dentofacial Orthop. 2001;120:559-562.

Alkofide EA. Sella turcica morphology and dimensions in cleft subjects. Cleft Palate Craniofac J. 2008;45:647-653.

Allareddy V, Ching N, Macklin EA, Voelz L, Weintraub G, Davidson E, Prock LA, Rosen D, Brunn R, Skotko BG. Craniofacial features as assessed by lateral cephalometric measurements in children with Down syndrome. Prog Orthod. 2016;17:35.

Andredaki M, Koumantanou A, Dorotheou D, Halazonetis DJ. A cephalometric morphometric study of the sella turcica. Eur J Orthod. 2007;29:449-456.

Antonarakis GS, Huanca Ghislanzoni L, La Scala GC, Fisher DM. Sella turcica morphometrics in children with unilateral cleft lip and palate. Orthod Craniofac Res. 2020;23:398-403.

Arat ZM, Türkkahraman H, English JD, Gallerano RL, Boley JC. Longitudinal growth changes of the cranial base from puberty to adulthood. A comparison of different superimposition methods. Angle Orthod. 2010;80:537-544.

Axelsson S, Storhaug K, Kjaer I. Post-natal size and morphology of the sella turcica in Williams syndrome. Eur J Orthod. 2004;26:613-621.

Axelsson S, Storhaug K, Kjaer I. Post-natal size and morphology of the sella turcica. Longitudinal cephalometric standards for Norwegians between 6 and 21 years of age. Eur J Orthod. 2004;26:597-604.

Becktor JP, Einersen S, Kjaer I. A sella turcica bridge in subjects with severe craniofacial deviations. Eur J Orthod. 2000;22:69-74.

Bell EJ, Kaidonis J, Townsend GC. Tooth wear in children with Down syndrome. Aust Dent J. 2002;47:30-35.

Bercovich E, Javitt MC. Medical Imaging: From Roentgen to the Digital Revolution, and Beyond. Rambam Maimonides Med J. 2018;9.

Bilgili SG, Akdeniz N, Karadag AS, Akbayram S, Calka O, Ozkol HU. Mucocutaneous disorders in children with down syndrome: case-controlled study. Genet Couns. 2011;22:385-392.

Bookstein FL. Morphometric Tools for Landmark Data: Geometry and Biology. Cambridge, Cambridge University Press. 1992;22:385-392.

Broadbent BH. A new x-ray technique and its application to orthodontia. Angle Orthod. 1931;1:45-66.

Caine A, Maltby AE, Parkin CA, Waters JJ, Crolla JA. Prenatal detection of Down's syndrome by rapid aneuploidy testing for chromosomes 13, 18, and 21 by FISH or PCR without a full karyotype: a cytogenetic risk assessment. Lancet. 2005;366:123-128.

Carey JC. Syndromes of the head and neck. Robert J. Gorlin, M. Michael Cohen, Jr., and L. Stefan Levin. New York: Oxford University Press, 1990, 977 pp. Am J Med Genet. 1992;42:144-144.

Choi WJ, Hwang EH, Lee SR. The study of shape and size of normal sella turcica in cephalometric radiographs. Korean Journal of Oral and Maxillofacial Radiology. 2001;31:43-49.

Clarke CM, Ford CE, Edwards JH, Smallpeice V. 21 Trisomy/normal mosaicism in an intelligent child with some mongoloid characters. Lancet. 1963;2:1229.

Cuoghi OA, Topolski F, Perciliano de Faria L, Occhiena CM, Ferreira ND, Ferlin CR, Rogério de Mendonça M. Prevalence of Dental Anomalies in Permanent Dentition of Brazilian Individuals with Down Syndrome. Open Dent J. 2016;10469-473.

Davidovich E, Aframian DJ, Shapira J, Peretz B. A comparison of the sialochemistry, oral pH, and oral health status of Down syndrome children to healthy children. Int J Paediatr Dent. 2010;20:235-241.

De Marinis L, Bonadonna S, Bianchi A, Maira G, Giustina A. Primary empty sella. J Clin Endocrinol Metab. 2005;90:5471-5477.

de Moraes ME, de Moraes LC, Dotto GN, Dotto PP, dos Santos LR. Dental anomalies in patients with Down syndrome. Braz Dent J. 2007;18:346-350.

Dejager S, Gerber S, Foubert L, Turpin G. Sheehan's syndrome: differential diagnosis in the acute phase. J Intern Med. 1998;244:261-266.

Desai SS. Down syndrome: a review of the literature. Oral Surg Oral Med Oral Pathol Oral Radiol Endod. 1997;84:279-285.

Diéguez-Pérez M, de Nova-García MJ, Mourelle-Martínez MR, Bartolomé-Villar B. Oral health in children with physical (Cerebral Palsy) and intellectual (Down Syndrome) disabilities: Systematic review I. J Clin Exp Dent. 2016;8:e337-343.

Dinani S, Carpenter S. Down's syndrome and thyroid disorder. J Ment Defic Res. 1990;34 187-193.

Dostálová S, Sonka K, Smahel Z, Weiss V, Marek J. Cephalometric assessment of cranial abnormalities in patients with acromegaly. J Craniomaxillofac Surg. 2003;31:80-87.

Down JL. Observations on an ethnic classification of idiots. 1866. Ment Retard. 1995;33:54-56.

Eggermann T, Schönherr N, Spengler S, Jäger S, Denecke B, Binder G, Baudis M. Identification of a 21q22 duplication in a Silver-Russell syndrome patient further narrows down the Down syndrome critical region. Am J Med Genet A. 2010;152a:356-359.

Feldkamp J, Santen R, Harms E, Aulich A, Mödder U, Scherbaum WA. Incidentally discovered pituitary lesions: high frequency of macroadenomas and hormone-secreting adenomas - results of a prospective study. Clin Endocrinol (Oxf). 1999;51:109-113.

Finlay LM. Craniometry and cephalometry: a history prior to the advent of radiography. Angle Orthod. 1980;50:312-321.

Foersch M, Jacobs C, Wriedt S, Hechtner M, Wehrbein H. Effectiveness of maxillary protraction using facemask with or without maxillary expansion: a systematic review and meta-analysis. Clin Oral Investig. 2015;19:1181-1192.

Friedland B, Meazzini MC. Incidental finding of an enlarged sella turcica on a lateral cephalogram. Am J Orthod Dentofacial Orthop. 1996;110:508-512.

Gardner RJM, Sutherland GR, Shaffer LG. Chromosome Abnormalities and Genetic Counseling. Oxford University Press. 2012;22:385-392.

Ghaith B, Al Halabi M, Khamis AH, Kowash M. Oral Health Status among Children with Down Syndrome in Dubai, United Arab Emirates. J Int Soc Prev Community Dent. 2019;9:232-239.

Halazonetis DJ. Morphometrics for cephalometric diagnosis. Am J Orthod Dentofacial Orthop. 2004;125:571-581.

Hall B. Mongolism in Newborn Infants:An Examination of the Criteria for Recognition and Some Speculations on the Pathogenic Activity of the Chromosomal Abnormality. Clin Pediatr (Phila) .1966;5:4-12.

Hamerton JL - Autosomal abnormalities–Group g. Human Cytogenetics. J. L. Hamerton, Academic Press. 1971**:**196-275.

Hasan HA, Hameed HA, Alam MK, Yusof A, Murakami H, Kubo K, Maeda H. Sella Turcica Morphology Phenotyping in Malay Subjects with Down's Syndrome. Journal of Hard Tissue Biology. 2019;28:259-264.

Hasen J, Boyar RM, Shapiro LR. Gonadal function in trisomy 21. Horm Res. 1980;12:345-350.

Hestnes A, Stovner LJ, Husøy Ø, Følling I, Fougner KJ, Sjaastad O. Hormonal and biochemical disturbances in Down's syndrome. Journal of Intellectual Disability Research. 1991;35:179-193.

Hjalgrim H, Fisher Hansen B, Brøndum-Nielsen K, Nolting D, Kjær I. Aspects of skeletal development in fragile X syndrome fetuses. Am J Med Genet. 2000;95:123-129.

Horbelt CV. Down syndrome: a review of common physical and oral characteristics. Gen Dent. 2007;55:399-402.

Houston WJ. The analysis of errors in orthodontic measurements. Am J Orthod. 1983;83:382-390.

Hyder M, Tanboga I, Kalyoncu I, Arain H, Marks L. Are Down syndrome children more vulnerable to tooth wear? J Intellect Disabil Res, 2019;63:1324-1333.

Jones RM, Faqir A, Millett DT, Moos KF, McHugh S. Bridging and dimensions of sella turcica in subjects treated by surgical-orthodontic means or orthodontics only. Angle Orthod. 2005;75:714-718.

Kaczorowska N, Kaczorowski K, Laskowska J, Mikulewicz M. Down syndrome as a cause of abnormalities in the craniofacial region: A systematic literature review. Adv Clin Exp Med. 2019;28:1587-1592.

Kjær I. Sella turcica morphology and the pituitary gland-a new contribution to craniofacial diagnostics based on histology and neuroradiology. Eur J Orthod. 2015;37:28-36.

Kjaer I, Fischer-Hansen B. The adenohypophysis and the cranial base in early human development. J Craniofac Genet Dev Biol. 1995;15:157-161.

Kjaer I, Fischer-Hansen B. Human fetal pituitary gland in holoprosencephaly and anencephaly. J Craniofac Genet Dev Biol. 1995;15:222-229.

Kjaer I, Hansen BF. The prenatal pituitary gland--hidden and forgotten. Pediatr Neurol. 2000;22:155-156.

Kjaer I, Hansen N, Becktor KB, Birkebaek N, Balslev T. Craniofacial morphology, dentition, and skeletal maturity in four siblings with Seckel syndrome. Cleft Palate Craniofac J. 2001;38:645-651.

Kjaer I, Keeling JW, Fischer Hansen B, Becktor KB. Midline skeletodental morphology in holoprosencephaly. Cleft Palate Craniofac J. 2002;39:357-363.

Kjaer I, Keeling JW, Reintoft I, Hjalgrim H, Nolting D, Fischer Hansen B. Pituitary gland and sella turcica in human trisomy 18 fetuses. Am J Med Genet. 1998;76:87-92.

Kjaer I, Keeling JW, Reintoft I, Nolting D, Fischer Hansen B. Pituitary gland and sella turcica in human trisomy 21 fetuses related to axial skeletal development. Am J Med Genet. 1998;80:494-500.

Kjaer I, Wagner A, Madsen P, Blichfeldt S, Rasmussen K, Russell B. The sella turcica in children with lumbosacral myelomeningocele. Eur J Orthod. 1998;20:443-448.

Klingel D, Hohoff A, Kwiecien R, Wiechmann D, Stamm T. Growth of the hard palate in infants with Down syndrome compared with healthy infants—A retrospective case control study. PLOS ONE. 2017;12:e0182728.

Korayem M, AlKofide E. Size and shape of the sella turcica in subjects with Down syndrome. Orthod Craniofac Res. 2015;18:43-50.

Korayem MA, AlKofide EA. Characteristics of Down syndrome subjects in a Saudi sample. Angle Orthod. 2014;84:30-37.

Korbel JO, et al. The genetic architecture of Down syndrome phenotypes revealed by high-resolution analysis of human segmental trisomies. Proc Natl Acad Sci USA. 2009;106:12031-12036.

Kouli A, Papagiannis A, Konstantoni N, Halazonetis DJ, Konstantonis D. A geometric morphometric evaluation of hard and soft tissue profile changes in borderline extraction versus non-extraction patients. Eur J Orthod. 2019;41:264-272.

Kula KGA. Cephalometry in Orthodontics 2D and 3D. 2020;22:385-392.

Kumar VCRSRSL. Robbins basic pathology. Philadelphia, Penns., Saunders. 2003;22:286-297.

Kusumoto Y, Imai K, Ohyama Y, Fukayama H, Shinozuka O. Oral management of a patient with down syndrome and agammaglobulinemia: a case report. BMC Oral Health. 2020;20:71.

Lejeune J, Turpin R, Gautier M. [Mongolism; a chromosomal disease (trisomy)]. Bull Acad Natl Med. 1959;143:256-265.

Lilienfeld AM. Epidemiology of mongolism by Abraham M. Lilienfeld with the assistance of Charlotte H. Benesch. Baltimore, Johns Hopkins Press. 1969

Lugović-Mihić L, Pilipović K, Crnarić I, Šitum M, Duvančić T. Differential Diagnosis of Cheilitis - How to Classify Cheilitis? Acta Clin Croat. 2018;57:342-351.

Marques LS, Alcântara CE, Pereira LJ, Ramos-Jorge ML. Down syndrome: a risk factor for malocclusion severity? Braz Oral Res. 2015;2944.

Melsen B. The postnatal growth of the cranial base in Macaca rhesus analyzed by the implant method. Tandlaegebladet. 1971;75:1320-1329.

Metzker ML. Sequencing technologies — the next generation. Nat Rev Genet. 2010;11:31-46.

Mıhçı E, Akçurin G, Eren E, Kardelen F, Akçurin S, Keser I, Ertuğ H. Evaluation of congenital heart diseases and thyroid abnormalities in children with Down syndrome. Anadolu Kardiyol Derg. 2010;10:440-445.

Morinushi T, Lopatin DE, Nakao R, Kinjyo S. A comparison of the gingival health of children with Down syndrome to healthy children residing in an institution. Spec Care Dentist. 2006;26:13-19.

Moyers RE, Bookstein FL. The inappropriateness of conventional cephalometrics. Am J Orthod. 1979;75:599-617.

Mubayrik AB. The Dental Needs and Treatment of Patients with Down Syndrome. Dent Clin North Am. 2016;60:613-626.

Murray J. Gene/environment causes of cleft lip and/or palate. Clin Genet. 2002;61:248-256.

Myrelid Å, Bergman S, Elfvik Strömberg M, Jonsson B, Nyberg F, Gustafsson J, Annerén G. Late effects of early growth hormone treatment in Down syndrome. Acta Paediatr. 2010;99:763-769.

Nuernberg MAA, Ivanaga CA, Haas AN, Aranega AM, Casarin RCV, Caminaga RMS, Garcia VG, Theodoro LH. Periodontal status of individuals with Down syndrome: sociodemographic, behavioural and family perception influence. J Intellect Disabil Res. 2019;63:1181-1192.

Nussbaum RL. Thompson & Thompson genetics in medicine. 2016;22:385-392.

Oliveira AC, Paiva SM, Martins MT, Torres CS, Pordeus IA. Prevalence and determinant factors of malocclusion in children with special needs. Eur J Orthod. 2011;33:413-418.

Petit FM, Hébert M, Picone O, Brisset S, Maurin ML, Parisot F, Capel L, Benattar C, Sénat MV, Tachdjian G, Labrune P. A new mutation in the AFP gene responsible for a total absence of alpha feto-protein on second trimester maternal serum screening for Down syndrome. Eur J Hum Genet. 2009;17:387-390.

Polani PE, Briggs JH, Ford CE, Clarke CM, Berg JM. A Mongol girl with 46 chromosomes. Lancet. 1960;1:721-724.

Quintanilla JS, Biedma BM, Rodríguez MQ, Mora MT, Cunqueiro MM, Pazos MA. Cephalometrics in children with Down's syndrome. Pediatr Radiol. 2002;32:635-643.

Reardon W. The Bedside Dysmorphologist. Oxford University Press. 2015;22:183-292.

Regezi J. Oral pathology : clinical pathologic correlations. 2017;22:375-391.

Russell BG, Kjaer I. Postnatal structure of the sella turcica in Down syndrome. Am J Med Genet. 1999;87:183-188.

Sadler TW. Langman's medical embryology. Baltimore, Williams & Wilkins. 1995;22:182-196.

Sasagawa I, Nakada T, Hashimoto T, Ishigooka M, Izumiya K, Kubota Y, Tomaru M. Hormone profiles and contralateral testicular histology in Down's syndrome with unilateral testicular tumor. Arch Androl. 1993;30:93-98.

Seguin, E., Brain, W. R. B., Down, J. L. H., Traitement moral, hygiène et éducation des idiots et des autres enfants arriérés ou retardés dans leur devéloppement, agités de mouvements involontiares, débiles, muets non-sourds, bègues, etc. Medical Heritage Library. Paris: J.B. Baillière, 1846. p:92-99

Shukla D, Bablani D, Chowdhry A, Thapar R, Gupta P, Mishra S. Dentofacial and cranial changes in down syndrome. Osong Public Health Res Perspect. 2014;5:339-344.

Silva M, Lyra MCA, Almeida HCR, Alencar Filho AV, Heimer MV, Rosenblatt A. Caries experience in children and adolescents with Down Syndrome: A systematic review and meta-analysis. Arch Oral Biol. 2020;115

Silverman FN. Roentgen standards fo-size of the pituitary fossa from infancy through adolescence. Am J Roentgenol Radium Ther Nucl Med. 1957;78:451-460.

Smith GF. Down's anomaly / G.F. Smith, J.M. Berg. Edinburgh ; New York : New York, Churchill Livingstone ; distributed in the U.S.A. by Longman. 1976;30:93-98.

Suri S, Tompson BD, Atenafu E. Prevalence and patterns of permanent tooth agenesis in Down syndrome and their association with craniofacial morphology. Angle Orthod. 2011;81:260-269.

Suri S, Tompson BD, Cornfoot L. Cranial base, maxillary and mandibular morphology in Down syndrome. Angle Orthod. 2010;80:861-869.

Swallow CE, Osborn AG. Imaging of sella and parasellar disease. Semin Ultrasound CT MR. 1998;19:257-271.

van Marrewijk DJ, van Stiphout MA, Reuland-Bosma W, Bronkhorst EM, Ongkosuwito EM. The relationship between craniofacial development and hypodontia in patients with Down syndrome. Eur J Orthod. 2016;38:178-183.

Waterson J. The child with multiple birth defects M. Michael Cohen, Jr. Raven Press, New York, 1982, 189 pp. Teratology. 1983;28:473-473.

Weichert J, Gembicki M, Ribbat-Idel J, Hartge DR. Assessment of Midfacial Hypoplasia in Down Syndrome Fetuses - Validity of a Two-Line Approach and Introduction of a Novel Angle (Maxilla-Mandible-Nasion Angle). Ultrasound Int Open. 2016;2:E58-62.

Weisberg LA, Zimmerman EA, Frantz AG. Diagnosis and evaluation of patients with an enlarged sella turcica. Am J Med. 1976;61:590-596.

Willatt L, Morgan SM. Shaffer LG, Slovak ML, Campbell LJ (2009): ISCN 2009 an international system for human cytogenetic nomenclature. Hum Genet. 2009;126:603.

# 9. ENCLOSURES

## 9.1 Enc. 1

## 10. CURRICULUM VITAE