Selcuk Dental Journal 12/2 (Ağustos 2025): 273-277

Research / Araştırma Makalesi

A Novel Approach to Dental Plaque Scoring: Digital Imaging Techniques

Dental Plak Skorlamasına Yeni Bir Yaklaşım: Dijital Görüntüleme Teknikleri

Simge MEŞELİ[a], **Bora KORKUT**[a], **Dilek TAĞTEKİN**[a]

[a]Marmara University, Faculty of Dentistry, Department of Restorative Dentistry, İstanbul, Türkiye
[a]Marmara Üniversitesi, Diş Hekimliği Fakültesi, Restoratif Diş Tedavisi AD, İstanbul, Türkiye

ABSTRACT

Aim: This study aimed to quantitatively compare clinical plaque scores with dental plaque areas measured on images obtained by digital photography and intraoral scanner by using a specific software program.
Materials and Methods: Clinical dental plaque scoring was measured according to the "Turesky Modified Quigley Hein Plaque Index" after dental plaque staining (Tri Plaque ID Gel, GC Corp.) to evaluate the oral hygiene of 20 patients. Following the clinical scoring procedure, intraoral photographs of the patients were taken using standardized dental photography equipment (EOS 700D, Canon Inc.), and the scan images were recorded by an intraoral scanner (iTero Element Flex, Align Tech.). In the data obtained, the dental plaque area on the labial surface of 66 anterior teeth was measured with the Image J software (National Institute for Health, Bethesda, USA), and the ratio of dental plaque area to the visible surface area of the tooth was measured. Spearman and Pearson Correlation Analysis were used to compare plaque area in intraoral photographs and scans and correlated them with clinical scores ($p<0.05$).

Results: The agreement between plaque area measured on intraoral scanner images and intraoral dental photographs was found to be positive and high (0.999; $p<0.001$). Additionally, a positive and high agreement was detected between the dental plaque scores obtained in the clinic and the plaque area measured on the intraoral scanner images (0.937; $p<0.001$). Similarly, a positive and high agreement was detected between the dental plaque scores obtained in the clinic and the dental plaque area measured on the photographs (0.941; $p<0.001$).

Conclusion: Under the conditions of the study, dental plaque areas measured by intraoral scans and dental photographs were determined to be compatible with each other. The mentioned digital clinical imaging methods might be clinical alternatives to the conventional dental plaque scoring techniques. Study protocol registered in www.clinicaltrials.gov Clinical trial number: NCT06443853.

Keywords: Dental plaque; Staining, dental plaque; Scoring, dental plaque; Photography, dental; Imaging, three-dimensional, Intraoral scanning

ÖZ

Amaç: Bu çalışmada bir dijital fotoğraf makinesi ve bir ağız içi tarayıcı kullanılarak elde edilen görüntüler üzerinde ölçülen klinik plak skorlarının, spesifik bir yazılım programı ile ölçülen dental plak alanları ile kantitatif olarak karşılaştırılması amaçlanmaktadır.

Gereç ve Yöntemler: 20 hastanın ağız hijyenini değerlendirmek amacıyla dental plak boyama (Tri Plaque ID Gel, GC Corp.) sonrası "Turesky Modifiye Quigley Hein Plak İndeksi'ne göre klinik dental plak skorlaması yapıldı. Klinik skorlamanın ardından hastaların aynı standartlardaki dental fotoğraf ekipmanları kullanılarak ağız içi fotoğrafları çekildi (EOS 700D, Canon Inc.) ve ağız içi tarayıcı ile tarama görüntüleri alındı (iTero Element Flex, Align Tech.). Elde edilen verilerde 66 adet ön dişin labial yüzeyindeki dental plak alanı Image J yazılımı (Ulusal Sağlık Enstitüleri, Bethesda, ABD) ile ölçüldü ve dental plak alanının dişin görünen yüzey alanına oranı ölçüldü. Ağız içi fotoğraf ve taramalardaki plak alanını karşılaştırmak ve klinik skorlarla ilişkilendirmek için Spearman ve Pearson Korelasyon Analizi kullanıldı ($p<0,05$).

Bulgular: Dişler üzerinde ölçülen plak alanı açısından, ağız içi tarayıcı görüntüleri ile ağız içi fotoğrafları arasında pozitif yönlü yüksek bir korelasyonu bulundu (0,999; $p<0,001$). Ayrıca klinikte elde edilen dental plak skorları ile ağız içi tarayıcı görüntülerinde ölçülen plak alanı arasında da pozitif yönlü yüksek bir korelasyon tespit edildi (0.937; $p<0,001$). Benzer şekilde klinikte elde edilen dental plak skorları ile fotoğraflarda ölçülen plak alanı arasında pozitif yönlü yüksek bir korelasyon tespit edildi (0,941; $p<0,001$).

Sonuç: Çalışma koşulları altında, ağız içi taramalar ve diş fotoğraflarıyla ölçülen dental plak alanlarının birbirleriyle uyumlu olduğu belirlenmiştir. Bahsedilen dijital klinik görüntüleme yöntemleri, geleneksel dental plak puanlama tekniklerine klinik alternatifler olabilir. Çalışma protokolü www.clinicaltrials.gov adresinde kayıtlıdır. Klinik çalışma numarası: NCT06443853.

Anahtar Kelimeler: Diş plağı; Lekelenme, diş plağı; Puanlama, diş plağı; Fotoğrafçılık, diş; Görüntüleme, üç boyutlu, Ağız içi tarama

INTRODUCTION

Dental plaque is the leading cause of caries and periodontal diseases.[1] Therefore, the removal of dental plaque is necessary to maintain oral health.[2] It is the responsibility of clinicians to identify areas of dental plaque adhesion on the teeth surfaces, to show plaque areas to patients, and to ensure that their teeth are brushed more properly. Traditionally, plaque indices are used to determine the oral hygiene status of the patients.[3,4] However, differences among operator can be observed in obtained results using plaque indices.

Although dental plaque is a colorless formation, it can become visible with staining agents.[5,6] After the plaque staining process, the patient's oral hygiene status can be viewed and recorded. Digital cameras have been used to record intraoral images for years. With the development of digital dentistry, it has become possible to take 3D intraoral records with intraoral scanners. In recent years, studies have shown that intraoral scanner images taken after plaque staining can be used instead of clinical scoring to determine the patient's oral hygiene status.[7-10] Although there are studies in the literature comparing the dental plaque scores recorded on the intraoral scanner and digital camera images, there isn't any study comparing stained plaque areas on the images through a software program.

This study aimed to compare dental plaque areas measured on images taken by digital camera and intraoral scanner and to evaluate these areas with clinical plaque scores with the help of a software program and provide a novel plaque index to score dental plaque on the taken intraoral images. The null hypothesis of this study was that dental plaque scores measured through digital camera and intraoral scanner images can replace clinical visual scoring.

METHODS

Ethics Statement

This study was received approval from the local ethics committee (Approval no: 09.2024.194), and was carried out with the adequate understanding and written consent of the volunteers. Study protocol registered in www.clinicaltrials.gov Clinical trial number: NCT06443853.

Gönderilme Tarihi/Received: 25 Eylül, 2024
Kabul Tarihi/Accepted: 13 Mart, 2025
Yayınlanma Tarihi/Published: 22 Ağustos, 2025
Atıf Bilgisi/Cite this article as: Meşeli S, Korkurt B, Tağtekin D. A Novel Approach to Dental Plaque Scoring: Digital Imaging Techniques. Selcuk Dent J 2025;12(2): 273-277 Doi: 10.15311/ selcukdentj.1555618

Sorumlu yazar/Corresponding Author: Simge MEŞELİ
E-mail: dtsimgemeseli@gmail.com
Doi: 10.15311/ selcukdentj.1555618

Inclusion/Exclusion Criteria

This clinical study was conducted at the Restorative Dentistry Department, Faculty of Dentistry, Marmara University, Türkiye. The study included 20 patients between the ages of 18 to 45. Among the patients with orthodontic brackets, severe tooth crowding that could not be visually verified on images and fixed or implant restorations were excluded from the study. Central, lateral and canine teeth of the volunteer, which can be easily seen on the images, were included in the study.

Study Design

The sample size was calculated using the G*Power software version 3.1.9.7 (Heinrich-Heine-University, Dusseldorf, Germany)[11]. Based on a previous sample study[12], it was decided to include at least 58 teeth in the study with correlation $\rho H1=0.573$, $\alpha=0.05$ and 95% test power.

After the surface of the teeth of the individuals included in the study was stained with a plaque-disclosing solution (Tri Plaque ID Gel, GC Corporation, Tokyo, Japan), the presence of plaque on the surface of the central, lateral and canine teeth was evaluated clinically by visual examination using the Modified Quigley Hein Plaque Index (TMQHPI). Intraoral photographs of 20 volunteers were taken by using a digital camera (Canon EOS 700D; 100 mm macro lens, Canon Inc., Tokyo, Japan; dual flash, YongNuo YN24EX, Tokyo, Japan), and 3D images were recorded by an intraoral scanner (iTero Element Flex, Align Technologies, San Jose, California, USA). Photograph and intraoral scanner images were overlapped, and pixel dimensions were synchronized using the Keynote 8.2 (Apple Inc., USA) software program.

After the synchronization, all the recorded images were transferred to the Image J V1.53 (National Institute for Health, Bethesda, USA) software program and processed (**Figure 1 and Figure 2**). In the present study, the Image J V1.53 software program was used to calculate the stained dental plaque covered areas on the tooth surface. The dental plaque-covered areas and the total tooth surface areas were marked using the software manually. Then, the marked areas were calculated in square pixels. The measurements were made for the 66 teeth of 20 volunteers, which can be easily seen on the images. The percentage ratio between the intraoral scan plaque area and the tooth surface area, and between the dental photograph plaque area and the tooth surface area were calculated per tooth and recorded. The measurements were performed by a single dental clinician (S.M.) with more than 15 years of experience in oral hygiene.

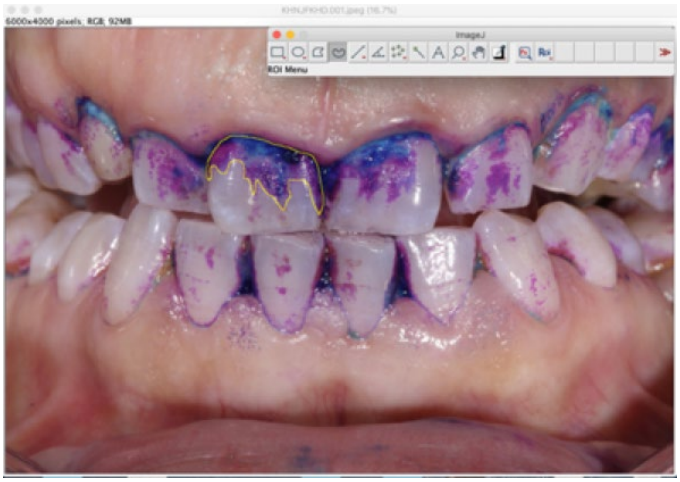

Figure 1. Digital photography image of the volunteer on the Image J software program

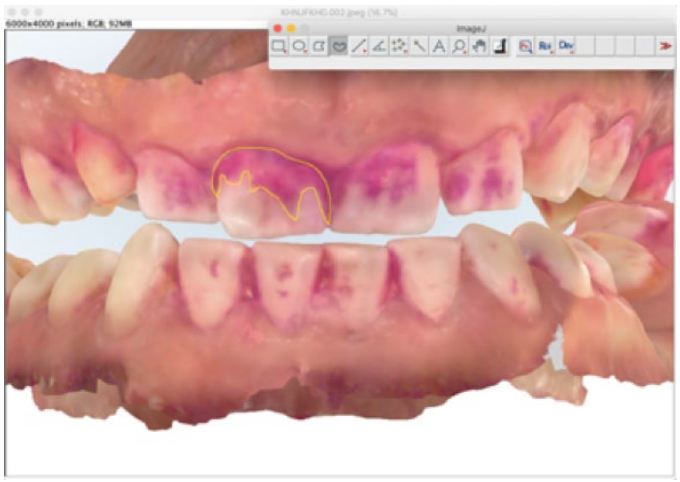

Figure 2. Intraoral scanner image of the same volunteer on the Image J software program

In the study, the dental plaque area-tooth surface area percentage corresponding to each TMQHPI score was calculated. The clinical score of 1 in TMQHPI corresponded to < 8% in both dental image- and intraoral scan-tooth surface plaque percentages. In addition, the clinical score of 2 in TMQHPI corresponded to 9-26% in the dental image-tooth surface plaque percentage, while the score of 3 corresponded to 27-32%, the score of 4 corresponded to 33-54%, and the score of 5 corresponded to 55-100%. the clinical score of 2 in TMQHPI corresponded to 9-28% in the intraoral scan-tooth surface plaque percentage, while the score of 3 corresponded to 29-33%, the score of 4 corresponded to 34-56%, and the score of 5 corresponded to 57-100.

A new Dental Plaque Index (DPI) was created based on the dental plaque area percentages corresponding to the TMQHPI scores. The tooth area which scored 1 and 2 according to TMQHPI was named as 1 according to DPI, 3 and 4 (TMQHPI) was named as 2 according to DPI, and the area scored 5 (TMQHPI) was named as 3 according to DPI (**Figure 3 and Figure 4**). The percentage of dental plaque area-tooth surface area corresponding to TMQHPI scores and the created DPI are shown in **Table 1**.

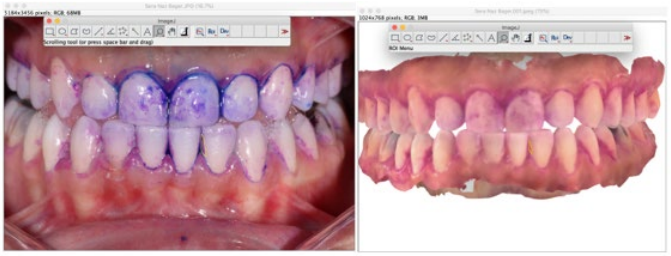

Figure 3. a) Digital photography image b) intraoral scanner image of the volunteer A on the Image J software program. Dental plaque coated area of the tooth number 32 was scored as 1 according to TMQHPI and DPI.

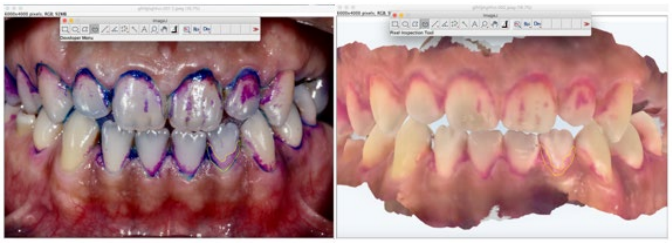

Figure 4. a) Digital photography image b) intraoral scanner image of the volunteer B on the Image J software program. Dental plaque coated area of the tooth number 32 was scored as 3 according to TMQHPI and as 2 according to DPI.

Table 1. The Percentage Ratio of Dental Plaque/Tooth Surface Area Corresponding to the Turesky Modified Quigley Hein Plaque Index and the Digital Plaque Index

Photograph		Intraoral scanner		TMQHPI	Total
plaque/ tooth surface area (%)	Digital Plaque Index	plaque/ tooth surface area (%)	Digital Plaque Index		
≤8	1	≤8	1	1	21
9-26		9-28		2	21
27-32	2	29-33	2	3	14
33-54		34-56		4	5
55-100	3	57-100	3	5	5

STATISTICALLY ANALYSES

In this study, the Pearson correlation coefficient technique was employed for analyzing the agreement of intraoral scanner plaque area and digital photography plaque area, and also intraoral scanner plaque area/ tooth surface area ratio and TMQHPI plaque scores. The Spearman correlation coefficient technique was employed for analyzing the agreement of digital photography plaque area/ tooth surface area ratio and TMQHPI plaque scores, and also intraoral scanner plaque area/ tooth surface area ratio and TMQHPI plaque scores. The deemed significance was set at $p<0.05$.

RESULTS

Dental plaque area on the intraoral scanner image and the dental plaque area on the photograph agreement was 0.999 ($p<0.001$) Pearson correlation coefficient. The agreement between the dental plaque percentage ratio of the intraoral photograph-tooth surface and TMQHPI was 0.941 ($p<0.001$) Spearman correlation coefficient. The agreement between the dental plaque percentage ratio of intraoral scanner-tooth surface and TMQHPI was 0.937 ($p<0.001$) Spearman correlation coefficient.

DISCUSSION

This study investigates the agreement of clinical dental plaque scores with the dental plaque areas measured on digital camera and intraoral scanner images. According to the results, positive and high agreement was observed between the clinical dental plaque scores and marked plaque areas in intraoral scans and dental images. Therefore, the hypothesis of the study was accepted.

It is stated that plaque staining solutions used to determine the oral hygiene of patients facilitate the detection of plaque.[13,14] Therefore, in the present study, plaque scoring and measurements on dental images were made after applying the dental plaque staining agent. Traditionally, plaque indices are used to detect plaque and determine the oral hygiene status of patients. Among these indices, TMQHPI was preferred in this study because it is frequently used in the clinic and can be scored according to the size of the dental plaque area of the tooth surface.[6] In recent years, studies comparing plaque scoring performed via intraoral imaging systems with clinical plaque scoring have appeared in the literature. Among these studies, Doi et al.[7] showed that the scores obtained in the images taken with an intraoral scanner after plaque staining were higher than the clinical visual scoring and used O'Leary Plaque Index to record presence or absence of stained dental plaque. In the present study, TMQHPI was used to measure dental plaque areas, because this plaque index shows not only the presence but also the width of dental plaque. In another recent study, Doi et al.[10] declared that dental plaque measurements could be more accurate by using an intraoral scanner. Giese-Kraft et al.[8] compared clinical visual plaque scoring with a 2D intraoral camera and 3D intraoral scanner and found that dental plaque could be detected reliably with both imaging methods, and they also stated that 2D imaging was more time-consuming. Meşeli et al.[9] showed that intraoral scanner image and digital photography plaque scores were similar to clinical visual plaque scores after-staining. In the present study, in addition to previous studies, the agreement between digital photography images, intraoral scans, and traditional clinical visual scores was investigated by a software program, and a new digital plaque scoring index (DPI) was proposed accordingly. Intraoral scanners have been widely used in intraoral imaging in dental clinics recently. This digital imaging system allows a more detailed examination of the intraoral environment by providing a 3D data.[15,16] The images obtained with the intraoral scanner can be rotated and enlarged with the software used and can easily display even areas that are difficult to diagnose. In addition, it becomes easier to inform patients about the intraoral images obtained, thus increasing patients' awareness of their oral hygiene status. Besides the direct 3D imaging, some of these devices also have caries diagnosis modes, via the addition of fluorescence and trans-illumination features.[17-19] Using a new digital plaque scoring system, oral hygiene status can be determined digitally along with caries detection on intraoral scanners. While developing the digital plaque scoring index, TMQHPI was used for comparison of dental plaque areas, which works based on dental plaque width. TMQHPI is recognized as a reliable index for measuring plaque, using an estimate of the area of the tooth covered by dental plaque. The ratio of the area covered by plaque to the tooth surface was calculated as a percentage, and the corresponding TMQHPI score was recorded. TMQHPI scores are 1 to 5. Based on the TMQHPI data, a new DPI was created with the scores between 1 and 3 (**Table 1**).

Image J is a Java-based image processing program developed at the National Institutes of Health and the Optical and Computational Instrumentation Laboratory. It is used in many studies in dentistry.[20-22] In addition to previous studies[7-10], the use of the Image J software in the study allowed the comparison of not only dental plaque scores but also dental plaque areas in different imaging methods. The dental plaque area-tooth surface percentage ratio corresponding to each TMQHPI score could be measured with using the Image J software.

The most important limitation of this study was that while intraoral scanner and digital photography images were transferred to the program, resolution loss occurs and the process required a long chair-side time. However, the loss of resolution in the images was not significant enough to obstruct measurements on the images. Another limitation was that dental plaque areas on the images were compared only on the labial surface of the central, lateral, and canine teeth because of the accessibility and visibility. Further studies can be conducted to investigate the agreement between the clinical visual and digital imaging scores in dental plaque calculation on all surfaces of the teeth.

CONCLUSION

Within the limitations of this study, dental plaque scores obtained by using the intraoral scanner and digital photography were found to be compatible with traditional clinical visual plaque scoring. It might be clinically useful to determine the patient's oral hygiene status by adding a digital dental plaque scoring system to the current intraoral scanners.

Değerlendirme / Peer-Review

İki Dış Hakem / Çift Taraflı Körleme

Etik Beyan / Ethical statement

Bu makale, Restoratif Diş Hekimliği Derneği 24. Uluslararası Bilimsel Kongresi'nde sözlü olarak sunulan ancak tam metni yayımlanmayan "Can Imaging Methods Be an Alternative to Clinical Dental Plaque Scoring?" adlı tebliğin içeriği geliştirilerek ve kısmen değiştirilerek üretilmiş hâlidir.

Bu çalışmanın hazırlanma sürecinde bilimsel ve etik ilkelere uyulduğu ve yararlanılan tüm çalışmaların kaynakçada belirtildiği beyan olunur.

This article is a partially modified and developed version of the paper titled "Can Imaging Methods Be An Alternative To Clinical Dental Plaque Scoring?" which was presented orally at the 24th International Scientific Congress of the Association of Restorative Dentistry but whose full text was not published.

It is declared that during the preparation process of this study, scientific and ethical principles were followed and all the studies benefited are stated in the bibliography.

Benzerlik Taraması / Similarity scan

Yapıldı – ithenticate

Etik Bildirim / Ethical statement

dishekimligidergisi@selcuk.edu.tr

Çıkar Çatışması / Conflict of interest

Çıkar çatışması beyan edilmemiştir.

Telif Hakkı & Lisans / Copyright & License

Yazarlar dergide yayınlanan çalışmalarının telif hakkına sahiptirler ve çalışmaları CC BY-NC 4.0 lisansı altında yayımlanmaktadır.

Finansman / Grant Support

Yazarlar bu çalışma için finansal destek almadığını beyan etmiştir. | The authors declared that this study has received no financial support.

Yazar Katkıları / Author Contributions

Çalışmanın Tasarlanması | Design of Study: SM (%35), BK (%30), DT (%35)
Veri Toplanması | Data Acquisition: SM (%40), BK (%30), DT (%30)
Veri Analizi | Data Analysis: SM (%40), BK (%30), DT (%30)
Makalenin Yazımı | Writing up: SM (%50), BK (%25), DT (%25)
Makale Gönderimi ve Revizyonu | Submission and Revision: SM (%30), BK (%35), DT (%35)

REFERENCES

1. Larsen T, Fiehn NE. Dental biofilm infections–an update. Apmis. 2017;125(4):376-84.
2. Figuero E, Nobrega DF, García-Gargallo M, Tenuta LM, Herrera D, Carvalho JC. Mechanical and chemical plaque control in the simultaneous management of gingivitis and caries: a systematic review. J Clin Periodontol. 2017;44: S116-S34.
3. Brown LJ, Löe H. Prevalence, extent, severity and progression of periodontal disease. Periodontol 2000. 1993;2(1):57-71.
4. Turesky S. Reduced plaque formation by the chloromethyl analogue of victamine C. J Periodontol. 1970; 41:41-3.
5. Datta D, Kumar S, Narayanan A, Selvamary AL, Sujatha A. Disclosing solutions used in dentistry. World J Pharm Res. 2017;6(6):1648-56.
6. Brostek A, Walsh L. Minimal intervention dentistry in general practice. Oral Health Dent Manag. 2014;13(2):285-94.
7. Doi K, Yoshiga C, Kobatake R, Kawagoe M, Wakamatsu K, Tsuga K. Use of an intraoral scanner to evaluate oral health. J. Oral Sci., 2021:21-0048.
8. Giese-Kraft K, Jung K, Schlueter N, Vach K, Ganss C. Detecting and monitoring dental plaque levels with digital 2D and 3D imaging techniques. PLoS One. 2022;17(2):e0263722.
9. Meseli S, Ekenel S, Korkut B, Aksu B, Tagtekin D, Yanikoglu F. Clinical assessment of various imaging systems for dental plaque scoring after the use of 3 different toothpastes. ISD. 2023;53(3):209.
10. Doi K, Yoshiga C, Oue H, Kobatake R, Kawagoe M, Umehara H, et al. Comparison of plaque control record measurements obtained using intraoral scanner and direct visualization. Clin Exp Health Sci. 2024;10(1):e852.
11. Faul F, Erdfelder E, Buchner A, Lang AG. Statistical Power Analyses Using G*Power 3.1: Tests for correlation and regression analyses. Behaviour Research Methods. 41 no: 4, 2009; 1149-1160.
12. Meseli S, Korkut B, Tagtekin D. DMFT-Related Dental Plaque Scoring by Using Different Imaging Systems. JERD. 2024.
13. Chetruș V, Ion I. Dental plaque-classification, formation, and identification. Int. J Med. Dent. 2013;3(2):139-43.
14. Ntovas P, Michou S, Benetti A, Bakhshandeh A, Ekstrand K, Rahiotis C, et al. Occlusal caries detection on 3D models obtained with an intraoral scanner. A validation study. J Dent. 2023; 131:104457.
15. Hou X, Xu X, Zhao M, Kong J, Wang M, Lee ES, et al. An overview of three-dimensional imaging devices in dentistry. JERD. 2022;34(8):1179-96.
16. Kihara H, Hatakeyama W, Komine F, Takafuji K, Takahashi T, Yokota J, et al. Accuracy and practicality of intraoral scanner in dentistry: A literature review. JPR. 2020;64(2):109-13.
17. Litzenburger F, Heck K, Kaisarly D, Kunzelmann K-H. Diagnostic validity of early proximal caries detection using near-infrared imaging technology on 3D range data of posterior teeth. Clin. Oral Investig. 2022:1-11.
18. Kanar Ö, Tağtekin D, Korkut B. Accuracy of an intraoral scanner with near-infrared imaging feature in detection of interproximal caries of permanent teeth: An in vivo validation. JERD. 2024.
19. Lin WS, Alfaraj A, Lippert F, Yang CC. Performance of the caries diagnosis feature of intraoral scanners and near-infrared imaging technology—A narrative review. J Prosthodont. 2023;32(S2):114-24.
20. Colpani JT, Borba M, Della Bona Á. Evaluation of marginal and internal fit of ceramic crown copings. Dent. Mater. J. 2013;29(2):174-80.
21. Zhu N, Chatzistavrou X, Ge L, Qin M, Papagerakis P, Wang Y. Biological properties of modified bioactive glass on dental pulp cells. J Dent. 2019;83:18-26.
22. da Costa TRF, Serrano AM, Atman APF, Loguercio AD, Reis A. Durability of composite repair using different surface treatments. J Dent. 2012;40(6):513-21.