Original Article

Influence of facial type on attractiveness of vertical canine position from the perspective of orthodontists and laypeople

Yasemin Bahar Acar[a]; Ece Abuhan[a]; Rudi Boyacıyan[b]; Fulya Özdemir[c]

ABSTRACT

Objectives: To evaluate the attractiveness of changes in vertical position of maxillary canines in frontal smiles of different facial types, and to evaluate the esthetic perceptions of orthodontists and laypeople, and the influence of facial type on these perceptions.

Materials and Methods: Three adult female volunteers were selected as individuals with normal, vertical, and horizontal growth patterns. Frontal posed smile photographs were digitally altered by adjusting vertical positions of the maxillary canines above, below, or coincident with the incisal line in increments of 0.5 mm within a range of 1 mm of extrusion and intrusion. For assessment, a web-based survey was formed with 18 images (six images for each model). A scale was present underneath each image, graded from 0 to 10 (0: unattractive; 10: the most attractive). Images were rated by 233 participants (105 orthodontists; 128 laypeople).

Results: Orthodontists scored 0-mm images significantly as the highest in all groups. Laypeople scored significantly higher for −0.5 mm images regardless of facial type. The lowest scored images were −1 mm (except for horizontal pattern) and +1 mm images. Mean values of scores given by men were higher ($P < .05$).

Conclusions: Orthodontists favored ideal dental alignment and preferred the incisal edges of central and canine teeth to be at the same level. Laypeople preferred a smoother smile arc than orthodontists and found harmony with the soft tissue more attractive. Facial type affected perceptions of the vertical changes of maxillary canines. (*Angle Orthod.* 0000;00:000–000.)

KEY WORDS: Vertical canine position; Facial type; Growth pattern; Smile arc; Smile esthetics

INTRODUCTION

The smile is an important component of facial attractiveness and beauty, playing a major role in social interactions. The effect of smile attractiveness on life quality, job acceptance, self-esteem, peer perception, psychological state, and dating prospects has been evaluated previously, and esthetically pleasing smiles have been correlated with more positive traits and abilities than less esthetic smiles.[1]

An esthetic smile has many components such as positioning, size, color, and shape of teeth, buccal corridors, gingival display, and the lips. Recent studies have documented that different skeletal patterns exhibit different smile features[2] and that the smile can influence the perception of facial esthetics of different facial types.[3] Vertical pattern patients were found to have greater smile display zones because they have more space for upper lip elevation,[4] which is responsible for increased incisal exposure during smiling. Siddiqui et al. also concluded that a flat smile arc was more common in a horizontal skeletal pattern whereas a parallel smile arc was more common in a vertical skeletal pattern.[2]

In a frontal smile, incisors attract more attention and play a vital role in forming the smile arc. Therefore, their influence on the smile has been inspected from many aspects. On the other hand, the literature is limited on the effect of the canines. Canine teeth are the cornerstones of the dentition, having esthetic and functional roles. Esthetically, they contribute to the formation of the smile arc and support the upper lip.

[a] Assistant Professor, Department of Orthodontics, Faculty of Dentistry, Marmara University, Istanbul, Turkey.

[b] Specialist in Orthodontics, Private Practice, Istanbul, Turkey.

[c] Professor, Department of Orthodontics, Faculty of Dentistry, Marmara University, Istanbul, Turkey.

Corresponding author: Dr Ece Abuhan, Department of Orthodontics, Faculty of Dentistry, Marmara University, Basibuyuk Street 9/3, Basibuyuk 34854, Maltepe, Istanbul, Turkey (e-mail: eceabuhan@hotmail.com)

Accepted: August 2021. Submitted: February 2021.
Published Online: October 15, 2021

© 0000 by The EH Angle Education and Research Foundation, Inc.

Downloaded from http://meridian.allenpress.com/angle-orthodontist/article-pdf/doi/10.2319/020121-95.1/2929971/10.2319_020121-95.1.pdf by Marmara Univ user on 25 October 2021

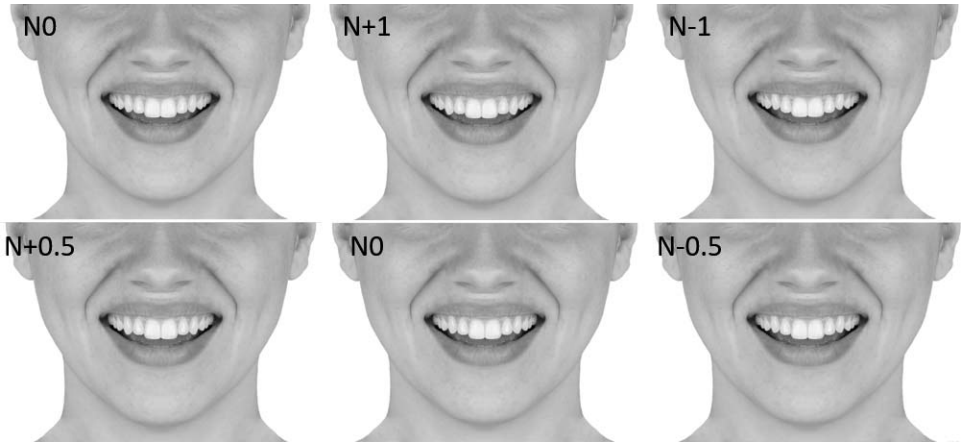

Figure 1. Images of normal growth pattern (NGP).

From the functional standpoint, canine guidance provides posterior disocclusion during lateral movements for a balanced masticatory system. De Paiva et al. evaluated the effect of vertical position of maxillary canines in a close-up frontal smile with and without gingival display from the perspectives of orthodontists and laypeople.[5] Nevertheless, no research evaluated the influence of vertical canine position considering the facial type of the patients.

The aim of the present study was to evaluate the attractiveness of differences in the vertical position of maxillary canines in the frontal smiles of three different models with different facial types and to evaluate whether there was a significant difference between the esthetic perceptions of orthodontists and laypeople and the influence of facial type on these perceptions.

MATERIALS AND METHODS

This study was approved by the Ethical Committee of Marmara University, Faculty of Dentistry (Protocol no. 2018/243). Three adult white female volunteers were selected according to their cephalometric analysis as three individuals with normal, vertical, and horizontal growth pattern characteristics. Subjects had no previous restorative procedures in the anterior region, no previous orthodontic treatment, and their periodontal structures were healthy. The models were instructed to wear no makeup. The frontal posed smile photographs were taken as close-up views, while the head positions were standardized so that the Frankfort horizontal plane and the bipupillary line were parallel to the true horizontal. Photographs were taken with a Canon EOS 800D DSLR Camera, with Canon Ultrasonic EF 100 mm 1:2.8 USM lens (Tokyo, Japan) and dual Elinchrom (Renens, Switzerland) BRX500 flashes equipped with Elinchrom (Renens, Switzerland) Portalite 66cm Softboxes, and reflectors were used for lighting. Subjects had their mouth slightly open to provide a background with darker colors of the oral cavity and to minimize the exposure of lower teeth during visual evaluation. The three volunteers signed release forms authorizing the use of their images in the current study.

Photographs were edited with Adobe Photoshop v.7.0 (Adobe Systems, California, USA). Skin irregularities of the models were eliminated. Asymmetries were eliminated by taking a mirror image of one-half of the photograph. A straight incisal line was created, passing through the incisal edges of the maxillary central incisors. Modified versions for each model were created by adjusting the vertical positions of the maxillary canine teeth symmetrically above, below, or coincident with this line in increments of 0.5 mm within a range of 1 mm of extrusion and 1 mm of intrusion. For calibration, the maxillary central incisors were measured directly with a digital caliper and the measurements were used as a reference for the calibration of a ruler in the software. The length or the proportion between width and height was not changed and this image was mirrored to ensure perfectly symmetrical changes. The images were cropped under soft tissue orbitale (the soft tissue point located at the most inferior level of each infraorbital rim) to eliminate the possible attraction of the eyes while displaying as much of the face to preserve the overall facial characteristics of the facial type. Final images were named in two designators: the first representing the growth pattern as N (normal), V (vertical), or H (horizontal) and the second representing the vertical canine displacement as −1, −0.5, 0, 0.5, or 1. The direction of the movement was defined by (−) indicating intrusion and (+) indicating extrusion.

For assessment, a web-based survey was designed with 18 images (six images for each model). The 0-mm images were used twice for each model to evaluate intrarater agreement. (Figures 1 through 3) A scale

Downloaded from http://meridian.allenpress.com/angle-orthodontist/article-pdf/doi/10.2319/020121-95.1/2929971/10.2319_020121-95.1.pdf by Marmara Univ user on 25 October 2021

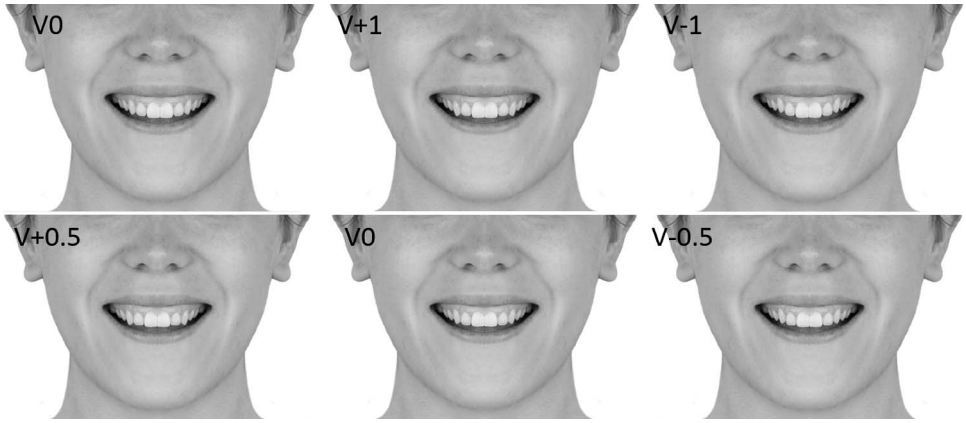

Figure 2. Images of vertical growth pattern (VGP).

was present underneath each image, graded from 0 to 10 (0: unattractive; 10: the most attractive). De Paiva et al. stated that evaluators tended to give average scores when they did not know the next stage of a questionnaire.[5] Therefore, at the beginning of the questionnaire, an informative notification appeared: "You will be shown 3 different models. There will be six photos for each model on separate pages. You are expected to score photos of each model amongst themselves." To eliminate bias, the participants were instructed to rate the images of each model within themselves, and the images of each model in the questionnaire were shown in separate steps.

The images were rated by 233 participants, including orthodontists (n = 105) and laypeople (n = 128). Inclusion criteria were: ages between 18 and 60 years; male and female; laypeople with no training in dentistry and no previous orthodontic treatment; and orthodontists should be specialists in orthodontics and work with the fixed orthodontic technique. Evaluations were made consecutively, regardless of sex or age distribution.

The smile line consonance of each model was evaluated by one operator. A line that followed the lower lip curvature was drawn in Adobe Photoshop software (Version 21.0.3, 2020). The same line was reproduced and was placed on the incisal edges of the anterior teeth to compare the harmony with the smile arc for all images. N0, V–1, and H–0.5 images were defined as the smile arcs that had a continuous vertical level of incisal edges and were free of occlusal steps. The model with a vertical growth pattern (VGP) had a smile arc that was consonant with the lower lip curve. The normal growth pattern (NGP) model displayed mild flattening of the smile arc compared to the lower lip curve, while the horizontal growth pattern (HGP) model had a flatter smile arc (Figure 4).

Statistical Analysis

Using a significance level of alpha = 0.05 and the standard deviation described by Machado et al.[6], the sample size was calculated to achieve 95% power using the formula described by Pandis.[7] The sample size calculation indicated that 95 subjects were needed in each group.

All statistical calculations were conducted with SPSS 25.0 (Statistical Packages of Social Sciences, IBM Corp., NY, USA) software. The reliability of the



Figure 3. Images of horizontal growth pattern (HGP).

Downloaded from http://meridian.allenpress.com/angle-orthodontist/article-pdf/doi/10.2319/020121-95.1/2929971/10.2319_020121-95.1.pdf by Marmara Univ user on 25 October 2021

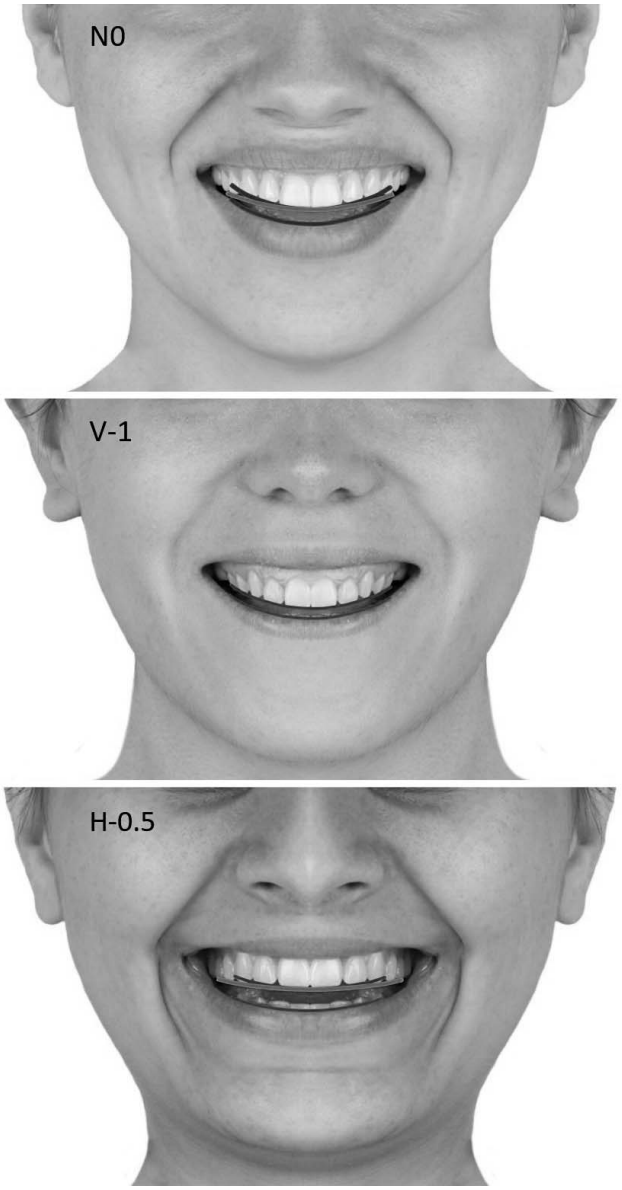

Figure 4. Smile arcs with continuous incisal edges in different facial types.

answers was evaluated with the Cronbach alpha value. The scores were assessed with Kruskal-Wallis test supplemented by Bonferroni test to evaluate differences among groups.

RESULTS

Cronbach alpha values ranged between 0.672 and 0.856, revealing overall good intrarater reliability (Table 1).

Kruskal-Wallis test revealed statistically significant differences in all image evaluations. To determine which images have differences, pairwise comparisons were made using the Mann-Whitney *U*-test and a Bonferroni adjustment was made to the *P* values.

Table 1 Reliability of the Answers[a]

	Cronbach Alpha	95% Confidence Interval		
		Lower Limit	Upper Limit	*P*
Laypeople				
NGP	0.67	0.37	0.63	0*
HGP	0.70	0.58	0.79	0*
VGP	0.83	0.61	0.78	0*
Orthodontists				
NGP	0.73	0.61	0.82	0*
HGP	0.77	0.67	0.84	0*
VGP	0.8	0.71	0.86	0*

* $P < .05$; $\geq .7$: reliable; 0.7-0.6: doubtful; 0.6-0.5: bad; $< .5$: unreliable.

[a] HGP indicates horizontal growth pattern; NGP, normal growth pattern; VGP, vertical growth pattern.

Orthodontists scored N0, H0, and V0 the highest, whereas laypeople scored N–0.5, H–0.5, and V–0.5 the highest, with statistically significant differences from almost all other alterations of each group. The lowest scored images by orthodontists were N–1, N+1, V–1, V+1, and H+1; while the N+1, H+1, and V+1 images were scored the lowest by laypeople with statistically significant differences from almost all other alterations of each group (Table 2).

There was a statistically significant difference in mean values of N–1 and N+1 between genders in laypeople ($P = .029$ and .007, respectively; $P < .05$). Mean values of V–1 and H+1 scores had a significant intergender difference in orthodontists ($P = .019$ and

Table 2 Comparison of Scores for Different Facial Types

	Orthodontists (n = 105)			Laypeople (n = 128)		
Designation[a]	Mean[b]	SD	*P*	Mean[c]	SD	*P*
N–1	4.06a	2.24	0*	6.22 A	2.28	0*
N–0.5	5.8c	2.19		7.52 B	1.93	
N0	7.79b	1.42		7.21 B	1.75	
N+0.5	6.35b,c	2.1		6.32 A	2.01	
N+1	4.38a	2.45		5.48 C	2.01	
H–1	5.07d	2.1	0*	6.03D	2.29	0*
H–0.5	6.18f	2.05		6.41F	2.4	
H0	6.25f	1.97		5.65E,F	2.13	
H+0.5	4.99d	2.09		4.89D,E	2.04	
H+1	3.57e	2.05		4.35D	2.02	
V–1	3.74g,j	2.05	0*	4.88G	2.31	0*
V–0.5	5.41h,i	2.23		5.96G	2.34	
V0	5.81h	2.18		5.86G,H	2.26	
V+0.5	4.57i,j	2.05		5.06H,I	2.19	
V+1	3.37g	1.98		4.33I	2.12	

* $P < .05$.

[a] N, indicates normal growth pattern; H, horizontal growth pattern; V, vertical growth pattern. For upper canines, –1 indicates 1 mm above the incisal line; –0.5, 0.5 mm above the incisal line; 0, coincident with the incisal line; +0.5, 0.5 mm below the incisal line; +1, 1 mm below the incisal line.

[b] Lowercase letters after values are pairwise comparisons of orthodontists. Different letters mean statistically significant differences.

[c] Uppercase letters after values are pairwise comparisons of laypeople. Different letters mean statistically significant differences.

Downloaded from http://meridian.allenpress.com/angle-orthodontist/article-pdf/doi/10.2319/020121-95.1/2929971/10.2319_020121-95.1.pdf by Marmara Univ user on 25 October 2021

.047 respectively; $P < .05$). The mean values of scores were higher for male evaluators.

DISCUSSION

An ideal smile arc has a parallel curvature between the maxillary incisal edges and the upper border of the lower lip.[8] The smile arc can be affected by the arch form, sagittal cant of the maxillary occlusal plane, and vertical positions of the anterior teeth.[9,10] On the other hand, a reverse smile line occurs when the cusp tips of maxillary canines or premolars are longer than those of the central incisor teeth. A non-consonant smile line is directly related to vertical changes in canine position and is inharmonious with other facial structures.[11]

The direction of the growth pattern defines the facial type and affects the smile through the occlusal plane inclination. A vertical growth pattern usually has excessive vertical growth of the posterior maxilla and lower lip curvature, while the horizontal growth pattern may lead to a flattened smile arc.[12] Misch evaluated the relationship between the vertical position of the maxillary central incisal edge and canine relative to the maxillary lip line and emphasized the importance of the vertical position of the canine as the key aspect during establishing the vertical position of maxillary incisors.[13] Changes in the vertical positions of canine teeth are directly related to the pattern of the smile arc. De Paiva et al. evaluated the perceptions of altered canine positions with or without gingival display and stated that extreme changes in vertical position of maxillary canines were considered unpleasant, especially extrusive alterations.[5] However, the effects of growth pattern and altered canine positions on smile esthetics have not been previously investigated. The present study aimed to evaluate the influence of facial type on the attractiveness of different vertical canine positions from the esthetic perceptions of orthodontists and laypeople on frontal smiles.

The literature indicated that orthodontists and laypeople had different perceptions when evaluating various smile esthetic characteristics. It is important to investigate the difference between the two groups since laypeople are the subjects of treatment while orthodontists are the practitioners. The chief concern of a patient arises from his/her esthetic perception and is one of the most important aspects of treatment planning. On the other hand, orthodontists are more sensitive regarding deviations, owing to their educational background.[9,14–16] In this study, even if there was no statistically significant difference, it was observed that orthodontists were stricter in their ratings, giving lower scores in general.

Some studies on smile esthetics stated that other structures on the face did not affect perceptions.[17,18] while others suggested that close-up images were more relevant for detailed evaluation.[19,20] In the present study, close-up photos were used to avoid irrelevant facial areas. Skin irregularities were eliminated and images were mirrored to reduce the margin of error in perceptions. Smile line orientation had been traditionally accepted to be parallel with the interpupillary line.[21] However, this assessment was not valid in patients with eye asymmetry. The incisal plane, which is perpendicular to the facial midline, has reliability and repeatability and eliminates the drawbacks of the interpupillary line.

Siddiqui et al. stated that different skeletal patterns have unique dentoskeletal features and patterns of the smile.[2] In agreement, the models in the present study displayed different smile characteristics as a result of the difference in facial types. The HGP model displayed insufficient gingival display and a flat smile arc, while the VGP model had excessive gingival display and a consonant smile arc. The NGP model had normal gingival display and a mildly flattened smile arc.

N0 was the image that displayed the continuous smile arc among the NGP images, without any step at the incisal edges. N0 was rated the highest by orthodontists, showing a significant difference with other images except for N+0.5. Laypeople rated N–0.5 the highest, significantly different than the other ratings except for the N0 image. The smile arc was almost continuous in N–0.5 due to 0.5 mm intrusion of the canines. The intrusion of the canines did not disturb the smile arc harmony due to the normal inclination of the occlusal plane in NGP. In N–0.5, the smile arc was slightly deeper, becoming more parallel to the lower lip curvature. This change may have caused the difference between the two groups. While orthodontists searched for ideal dental alignment, the harmony with the soft tissue was more attractive for the laypeople.

Among the HGP images, H–0.5 had the most continuous smile arc. Orthodontists gave the highest scores to the H0 image, whereas laypeople rated the H–0.5 image as the most attractive. The H0 image displayed a flatter smile arc than the H–0.5. The result from the orthodontists was consistent with that of Kaya et al., which stated that flat smile arcs were more preferable when gingival display was insufficient.[22]

Among the VGP images, V–1 had the most continuous smile arc. However, the V0 image was rated highest by the orthodontists, while laypeople rated V–0.5 as the most attractive. These findings supported the previous inference that harmony with the soft tissues (that is, the lower lip curvature) was more

Downloaded from http://meridian.allenpress.com/angle-orthodontist/article-pdf/doi/10.2319/020121-95.1/2929971/10.2319_020121-95.1.pdf by Marmara Univ user on 25 October 2021

attractive for laypeople, whereas orthodontists focused on incisal edge alignment. The smile arc, as a criterion of esthetic evaluation, is an aspect that recently captured the appreciation of clinicians. Sarver focused on the importance of obtaining an ideal smile arc during treatment planning.[12] Nevertheless, the literature indicated that orthodontically treated smiles can be flatter[23,24] and some smiles even less esthetic.[18] This might be a result of the fact that the trained eyes of orthodontists concentrated more on the dentition. However, soft tissue harmony should not be overlooked.

It can be concluded orthodontists preferred smile arcs in which the incisal edges of the central and canine teeth were on the same level, regardless of the growth pattern. This perception of orthodontists may be related to the knowledge of positioning of the central incisor and canine brackets at the same distance from the incisal edge as advocated by McLaughlin and Bennett.[25] Laypeople, on the other hand, showed that they preferred a smoother smile arc than orthodontists by scoring −0.5 images as the highest for each growth pattern. Regarding gender, the scores of male raters were higher than females. Geron and Atalia also reported that oral and smile esthetic perceptions may be affected by the sex of the rater.[26]

The lowest scored images by orthodontists for all growth patterns were the limit values (−1 and +1 mm images) except for the HGP group. In the H−1 image, which belonged to a model with a flat smile arc, scores were not low because there was a deepening in the curve of the smile arc. The lowest scored images by laypeople in all patterns were +1 mm images, similar to the orthodontists. A previous study regarding vertical canine positions also reported that extreme changes, especially for extrusion alterations, were considered more unattractive. It stated that the position of the lower canine teeth, which have less esthetic importance, could be changed to provide canine guidance for better function.[5] Since the extrusion of canine teeth also means flattening of the smile arc, their low scores were supported by previous studies.[9,12,24]

CONCLUSIONS

- Canines on the same incisal level with central incisors were perceived as the most attractive by orthodontists for all facial types, even if the canine extrusion interrupts the smile arc continuity and consonance.
- Laypeople scored the 0.5-mm intrusion images the highest for all facial types, revealing their preference for more continuous smile arcs.
- The least attractive images were −1 and especially +1 images, in general, except in the HGP group.
- In the HGP group, 1 mm-intrusion image scores were not low, since the change in the vertical position led to an improvement in the smile arc curvature.
- While evaluating smile esthetics, male raters tend to give higher scores than females.
- The facial type affects the esthetic perception of the vertical changes of the maxillary canine.

REFERENCES

1. Van der Geld P, Oosterveld P, Van Heck G, Kuijpers-Jagtman AM. Smile attractiveness: self-perception and influence on personality. *Angle Orthod*. 2007;77(5):759–765.
2. Siddiqui N, Tandon P, Singh A, Haryani J. Dynamic smile evaluation in different skeletal patterns. *Angle Orthod*. 2016; 86(6):1019–1025.
3. Batwa W. The influence of the smile on the perceived facial type esthetics. *Biomed Res Int*. 2018;2018:3562916.
4. Wu H, Lin J, Zhou L, Bai D. Classification and craniofacial features of gummy smile in adolescents. *J Craniofac Surg*. 2010;21(5):1474–1479.
5. de Paiva TT, Machado RM, Motta AT, Mattos CT. Influence of canine vertical position on smile esthetic perceptions by orthodontists and laypersons. *Am J Orthod Dentofacial Orthop*. 2018;153(3):371–376.
6. Machado AW, Moon W, Gandini Jr LG. Influence of maxillary incisor edge asymmetries on the perception of smile esthetics among orthodontists and laypersons. *Am J Orthod Dentofacial Orthop*. 2013;143(5):658–664.
7. Pandis N. Sample calculations for comparison of 2 means. *Am J Orthod Dentofacial Orthop*. 2012;141(4):519–521.
8. Frush JP, Fisher RD. The dynesthetic interpretation of the dentogenic concept. *J Prosthet Dent*. 1958;8(4):558–581.
9. Parekh SM, Fields HW, Beck M, Rosenstiel S. Attractiveness of variations in the smile arc and buccal corridor space as judged by orthodontists and laymen. *Angle Orthod*. 2006; 76(4):557–563.
10. Ackerman MB, Ackerman JL. Smile analysis and design in the digital era. *J Clin Orthod*. 2002;36(4):221–236.
11. Morley J, Eubank J. Macroesthetic elements of smile design. *J Am Dent Assoc*. 2001;132(1):39–45.
12. Sarver DM. The importance of incisor positioning in the esthetic smile: the smile arc. *Am J Orthod Dentofacial Orthop*. 2001;120(2):98–111.
13. Misch CE. Guidelines for maxillary incisal edge position—a pilot study: the key is the canine. *J Prosthodont*.2008;17(2): 130–134.
14. Krishnan V, Daniel ST, Lazar D, Asok A. Characterization of posed smile by using visual analog scale, smile arc, buccal corridor measures, and modified smile index. *Am J Orthod Dentofacial Orthop*. 2008;133(4):515–523.
15. Suzuki L, Machado AW, Bittencourt MAV. An evaluation of the influence of gingival display level in the smile esthetics. *Dental Press J Orthod*. 2011;16(5):37–39.
16. Pinho S, Ciriaco C, Faber J, Lenza MA. Impact of dental asymmetries on the perception of smile esthetics. *Am J Orthod Dentofacial Orthop*. 2007;132(6):748–753.
17. Nascimento DC, Santos ÊRd, Machado AWL, Bittencourt MAV. Influence of buccal corridor dimension on smile esthetics. *Dental Press J Orthod*. 2012;17(5):145–150.

Downloaded from http://meridian.allenpress.com/angle-orthodontist/article-pdf/doi/10.2319/020121-95.1/2929971/10.2319_020121-95.1.pdf by Marmara Univ user on 25 October 2021

18. Zachrisson BU. Esthetic factors involved in anterior tooth display and the smile: vertical dimension. *J Clin Orthod*. 1998;32:432–445.
19. Arnett GW, Bergman RT. Facial keys to orthodontic diagnosis and treatment planning—part II. *Am J Orthod Dentofacial Orthop*. 1993;103(5):395–411.
20. Flores-Mir C, Silva E, Barriga M, Lagravere M, Major P. Lay person's perception of smile aesthetics in dental and facial views. *J Orthod*. 2004;31(3):204–209.
21. Singer BA. Principles of esthetics. *Curr Opin Cosmet Dent*. 1994:6–12.
22. Kaya B, Uyar R. Influence on smile attractiveness of the smile arc in conjunction with gingival display. *Am J Orthod Dentofacial Orthop*. 2013;144(4):541–547.
23. Ackerman J, Ackerman M, Brensinger C, Landis J. A morphometric analysis of the posed smile. *Clin Orthod Res*. 1998;1(1):2–11.
24. Hulsey CM. An esthetic evaluation of lip-teeth relationships present in the smile. *Am J Orthod*. 1970;57(2):132–144.
25. McLaughlin R. Bracket placement with the preadjusted appliance. *J Clin Orthod*. 1995;29:302–311.
26. Geron S, Atalia W. Influence of sex on the perception of oral and smile esthetics with different gingival display and incisal plane inclination. *Angle Orthod*. 2005;75(5):778–784.

Downloaded from http://meridian.allenpress.com/angle-orthodontist/article-pdf/doi/10.2319/020121-95.1/2929971/10.2319_020121-95.1.pdf by Marmara Univ user on 25 October 2021