MARMARA
MEDICAL JOURNAL

Original Article

https://dergipark.org.tr/tr/pub/marumj

Myrtus communis reduces radiation-induced genitourinary histopathological damage and apoptosis in rats: TROD-GROG-004 Study

Selnur OZKURT[1,2], Bedriye DOGAN[3], Nagehan OZYILMAZ[4], Aslı AYKAC[5], Busra ERTAS[6], Ali SEN[7], Cemile CEYLAN[8,9], Feriha ERCAN[10], Beste M. ATASOY[11]

[1] Department of Radiation Oncology, University Hospital Leuven, Leuven, Belgium, and
[2] Department of Radiation Oncology, Istanbul University Institute of Oncology, Istanbul, Türkiye
[3] Department of Radiation Oncology, Faculty of Medicine, İnönü University, Malatya, Türkiye
[4] Department of Histology and Embryology, Faculty of Medicine, Samsun University, Samsun, Türkiye
[5] Department of Biophysics, School of Medicine, Near East University, Mersin, Türkiye
[6] Department of Pharmacology, Faculty of Pharmacy, Marmara University, Istanbul, Türkiye
[7] Department of Pharmacognosy, Faculty of Pharmacy, Marmara University, Istanbul, Türkiye
[8] Department of Medical Physics, Faculty of Health Sciences, Yeditepe University, Istanbul, Türkiye, and
[9] Department of Radiation Oncology, Istanbul Oncology Hospital, Istanbul, Türkiye
[10] Department of Histology and Embryology, School of Medicine, Marmara University, Istanbul, Türkiye
[11] Department of Radiation Oncology, School of Medicine, Marmara University, Istanbul, Türkiye

Corresponding Author: Beste M. ATASOY
E-mail: bmatasoy@yahoo.com

Submitted: 01.06.2025 **Accepted:** 13.08.2025

ABSTRACT

Objective: To investigate the radioprotective and prophylactic effects of *Myrtus communis* (MC) in kidney, bladder, and ovary samples in an animal model.

Materials and Methods: Female rats (n=30) were divided into four groups. The control group (C) (n=6) received only oral saline (SF) for four days. Ionizing radiation (IR) groups were organized as follows: "IR group (IR)" (n=8) received oral SF for four days starting on the day of administration; "MC treatment group (MC-tx)" (n=8) received oral MC for four days beginning on the day of irradiation; and "MC pretreatment group (MC-Ptx)" (n=8) received oral MC for a total of eight days, starting four days before irradiation. MC was administered via oral gavage. Irradiation was performed at 10 Gray (Gy) in a single dose. On the fourth day of irradiation, all rats were sacrificed, the tissues were examined histopathologically, and caspase-9 and caspase-3 levels were examined using western blotting to assess mitochondrial apoptosis.

Results: Radiation-induced damage decreased across all treatment groups. Caspase-9 and caspase-3 levels were significantly lower in the MC-Ptx and MC-tx groups compared to the IR group in all tissues ($p<0.01$).

Conclusion: *Myrtus communis* significantly ameliorated IR-induced damage to genitourinary tissues by both prophylactic and therapeutic applications. Therefore, the findings of this study may contribute to the development of new strategies in radioprotection.

Keywords: Bladder, Kidney, *Myrtus communis*, Radioprotection, Rats, Ovary

1. INTRODUCTION

Cancer is a significant health problem worldwide and is the second most common cause of death after cardiovascular diseases [1]. Radiotherapy is one of the major clinical modalities in treating malignant diseases [2,3]. Ionizing radiation (IR) has a dose-dependent effect by directly and indirectly by reactive oxygen species (ROS) damaging deoxyribonucleic acid (DNA) in cancer cells [2,4,5]. Direct effects lead to a greater number of double-strand breaks in DNA compared to those caused by ROS [2,5]. Despite the technological advances that improve precise and targeted planning in radiotherapy, IR causes side effects in surrounding healthy tissues during or after cancer treatment. Therefore, new strategies to reduce the side effects of irradiation are always a crucial part of radiotherapy.

Radiation effects on tumor and normal tissues result from the formation of ROS and free radicals, especially hydroxyl radicals [4,5]. Hydroxyl radicals induce membrane lipid peroxidation in

How to cite this article: Ozkurt S, Dogan B, Ozyilmaz N, et al. *Myrtus communis* reduces radiation-induced genitourinary histopathological damage and apoptosis in rats: TROD-GROG-004 Study. Marmara Med J 2025;38 (3): 190-197. doi: 10.5472/marumj.1798589

© 2025 Marmara University Press, All Rights Reserved
ISSN: 1309-9469

http://doi.org/10.5472/marumj.1798589
Marmara Med J 2025;38(3): 190-197

Content of this journal is licensed under a Creative Commons Attribution-NonCommercial 4.0 International License.

cells and oxidation of cellular proteins, leading to DNA damage, cell death, and a pro-inflammatory response cascade in both tumor cells and healthy tissues [2,4,5]. Because of the dose – and time-dependent effects of IR, the probability of a pro-inflammatory response and irreversible tissue damage increases, due to both direct ROS and ROS released from dead cells.

Apoptosis acts as a cellular security guard, eliminating unwanted cells during development to maintain a proper cell population [6,7]. When this guard malfunctions, the balance between cell growth and death gets thrown off track, potentially leading to health problems and causing most or even all types of cancers. At least two major apoptotic cell death pathways can be distinguished: the extrinsic pathway that signals through so-called death receptors and the intrinsic pathway involving mitochondria. The first is triggered through the death receptors, including CD95 (Fas, APO-1), tumor necrosis factor (TNF) receptor-1, TNF-Related Apoptosis-Inducing Ligand (TRAIL) receptor-1 and – 2, ultimately leading to the recruitment of the adaptor protein Fas-associated death domain (FADD) and subsequent activation of caspase-8, which in turn activates caspase-3. The intrinsic pathway is characterized by a loss of mitochondrial membrane potential (DWm) and cytochrome c release from mitochondria that interacts with the apoptotic protease activating factor 1 (APAF-1), recruiting caspase-9 and activating caspase-3. Many anti-cancer agents in clinical therapy intervene with apoptotic signaling, either with the intrinsic or the extrinsic pathways [6,7].

When abdominal and pelvic radiotherapy is applied for gastrointestinal system cancers, genitourinary system cancers, and lymphoma patients, various damages occur in organs such as the ovary, bladder, and kidney due to DNA damage and ROS [8,9]. Irradiation causes apoptosis and necrosis in renal glomerular, vascular, and interstitial cells. While this may be asymptomatic in the acute phase, it may lead to renal failure in the subacute and chronic phases [8,10]. Cystitis and urethral inflammation are frequently seen in the bladder and urethra due to radiotherapy in the acute period, and this may later develop into hemorrhagic cystitis, fistula, and urethral stenosis [8]. Radiotherapy mainly damages granulosa cells in ovarian tissues in the pelvic region [9,11]. Studies have shown that ovaries are highly radiosensitive, and the lethal dose 50 (LD50), the dose at which half of the follicles die, for ovarian follicle cells is less than 2 Gray (Gy) [11,12]. Oocyte death, vascular damage in the stroma, tissue atrophy, and fibrosis occur due to radiotherapy in direct proportion to increasing patient age, ovarian reserve, tissue volume exposed to radiation, and total radiation dose. This may be seen as amenorrhea, premature ovarian failure, and infertility in the clinic [9,13].

Side effects in cancer treatment occur depending on the total dose and fractionation. Improvement of treatment-related side effects in the acute period is essential to reduce the occurrence of severe toxicities in the chronic period. Side effects in the urinary system (kidneys and bladder) complicate the treatment process in the acute period and affect the quality of life in the long term. Ovarian damage is generally asymptomatic at the beginning, but it may cause infertility. So, prevention and treatment of these side effects are essential. For this reason, many studies examine the effects of different components/natural products with antioxidant and anti-inflammatory effects on radiotherapy damage [14-17]. One natural antioxidant product is *Myrtus communis* subsp. *communis* (MC) [16].

Myrtus communis is an evergreen shrub with white or pink flowers, fruits, and essential myrtle oil in the leaves [17]. MC is the only variety of myrtle that grows up to an average of 5 m in height and is native to Southern Europe, North Africa, Western Asia, and the Indian subcontinent, and to the Mediterranean and Anatolian regions in Türkiye [18,19]. Phytochemical studies conducted on the leaves of this species have reported that it contains phenolic acids, flavonoids, terpenoids, tannins, coumarins, and oligomeric nonprenylated acyl phloroglucinol compounds [16,20–23]. It has also been reported that this species has pharmacological activities such as antifibrotic, antidiarrheal, vasodilator, antispasmodic, anti-colitis, antiulcer, anticancer, antidiabetic, anxiolytic, antimicrobial, sedative-hypnotic, and antioxidant effects [21,23-25].

In this experimental study, we aimed to investigate the protective effect of MC against IR in the genitourinary system organs and to reduce the acute toxicity of radiation. Additionally, evaluating three different genitourinary organs — the kidney, bladder, and ovary — at both histological and molecular levels, rather than focusing on only one organ, represents a novel aspect of our study.

2. MATERIALS and METHODS

Animals

All experimental protocols were approved by Marmara University School of Medicine Animal Care and Use Committee (date: 17 May 2022; number: 34.2022mar), and the Directive 2010/63/E.U. was followed for the research. Thirty female rats of the Rattus species Norvegicus (250-300 g, three months old) were used in the study. The animals were purchased from Istanbul Health Sciences University Experimental Animals Application and Research Center and maintained at Marmara University Experimental Animals Application and Research Center (MU, DEHAMER). The rats were housed in a room with a temperature of 22-24°C and a 12-hour light/dark cycle, and four animals were separated in each cage. During the experiments, rats were kept *ad libitum* without any restriction on water and food intake.

Experimental protocol

The animals were divided into four groups based on IR and MC treatment. The control group (n=6) received only oral saline (SF) for four days without IR. The remaining rats were split into three groups according to whole-body IR and MC administration. These groups included the "IR group" (n=8), which received oral SF for four days, starting on the day of IR; the "MC treatment group (MC+tx)" (n=8), which received oral MC for four days beginning on the day of IR; and the "MC

http://doi.org/10.5472/marumj.1798589
Marmara Med J 2025;38(3): 190-197

pretreatment group (MC-Ptx)" (n=8), which received oral MC for a total of eight days, starting four days before IR. No restrictions were applied during the experiment. The schematic diagram of the experiment is shown in Figure 1.

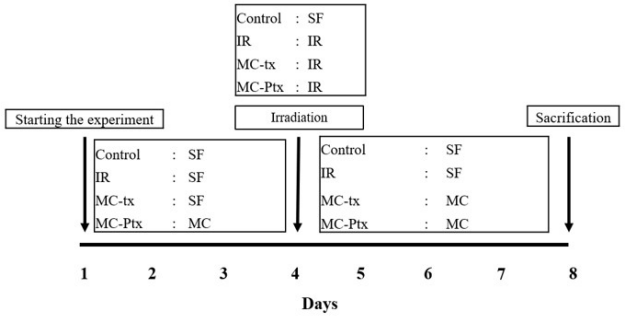

Figure 1. *The schematic diagram of the study design.*

Preparation and dosage of MC extract

Myrtus communis extract was prepared at Marmara University, Faculty of Pharmacy, Department of Pharmacognosy, and was obtained under the same conditions. Our previous studies have shown its efficacy [23,24]. MC leaves were collected from West Anatolia (Turgutlu Region of Manisa), Türkiye, and identified by a botanist (Dr. Gizem Bulut). Voucher specimens were kept in the Herbarium of the School of Pharmacy, Marmara University (MARE No: 13006). MC leaves (100 g) were dried in the shade at room temperature. The dried powdered samples were extracted with 96% ethanol using the Soxhlet device. After filtration, the extract was concentrated using a rotary evaporator. The MC powder was obtained with a yield of 28.56% and kept in a dark glass bottle at 4°C until treatment [24]. Within the scope of the protocol, MC extract dissolved in oral SF was administered to the experimental groups by oral gavage method as 1 ml, at a dose of 100 mg/kg once daily in the morning [25].

Irradiation procedure

Except for the control group, irradiation was performed under intraperitoneal anesthesia with 60 mg/kg ketamine and 10 mg/kg xylazine. The rats were placed face down, and their tails and legs were taped. First, simulation computed tomography (CT) images with 1 mm slices were obtained, and 3D planning was performed. After completing the 3D planning, 10 Gy irradiation was delivered in a single fraction from two anteroposterior fields at a dose rate of 500 MU/min with a 6 MV photon beam on a linear accelerator (Electra, Versa HD, Crawley, UK) [14,26,27]. The reason for choosing this dose schedule is as follows: The linear-quadratic model was used to normalize the total body irradiation regimens and to calculate biologically effective doses (BEDs). BED values above 16 Gy are generally associated with a higher risk of renal dysfunction [27].

Substance administration following irradiation

After irradiation, oral SF was administered to the IR group, while a 100 mg/kg MC extract dissolved in saline was given orally to the IR+MC group. In the pretreatment group, unlike the IR+MC group, MC was administered four days before IR and continued for four days after IR. The dose of MC used in the study was chosen based on previous studies demonstrating that it has antioxidative and anti-inflammatory effects [23,24].

Sacrification and tissue obtaining

On the fourth day of the experiment, all animals were decapitated by a commercial guillotine to the level of the cervical vertebrae [14]. The decapitation procedure was performed very quickly by an experienced researcher without causing any pain or suffering. After the rats were sacrificed, the bladder, bilateral ovaries, and kidney tissues were removed for histopathological and molecular evaluation. Cadavers were kept in the deep freezer and disposed of as medical waste.

Histopathological evaluation

Half of the bladder, left ovary, and kidney samples were fixed in 10% formaldehyde solution, dehydrated in an ascending alcohol series, cleared in toluene, and embedded in paraffin. For histopathological evaluation, paraffin sections (5 µm) were stained with hematoxylin and eosin (H&E), and were examined under an Olympus BX51 photomicroscope (Tokyo, Japan). Histopathological evaluation was performed by histologists blindly (FE, NO). Semiquantitative histopathological criteria were summarized in Table I. Histopathological scores were given as 0 for none, 1 for mild, 2 for moderate, and 3 for severe for each criterion. The score for each criterion was calculated as the sum of the individual scores, and in each specimen, at least five microscopic areas were examined. The maximum score calculated was 12 for the kidney samples and 9 for the bladder and ovary samples [28–30].

Table I. *Histopathological scoring criteria of tissue damage*

Tissue	Histopathological appearance
Kidney	• Degeneration of glomerular structure and dilatation of Bowman's space • Degeneration of tubule structures • Vascular congestion and interstitial edema • Inflammatory cell infiltration
Urinary bladder	• Urothelial desquamation • Vascular congestion • Inflammatory cell infiltration
Ovary	• Degenerative follicles • Vascular congestion and hemorrhage • Inflammatory cell infiltration

The densitometric analysis of protein immunoblots

After dissection, caspase-3 and caspase-9 expression levels were evaluated using western blotting in the bladder, ovary, and kidney

http://doi.org/10.5472/marumj.1798589
Marmara Med J 2025;38(3): 190-197

samples stored at – 80°C. For the molecular analysis of tissues, frozen samples were weighed and homogenized in ice-cold 20 mM Tris-HCl buffer containing 1 mM EDTA, protease inhibitors, 10% glycerol, 50 mM NaCl, and 2 mM DTT. Afterward, the homogenates were centrifuged at 2000 × g for 10 minutes. Pellets were incubated with 50 mM Tris-HCl, 5% glycerol, 1 mM EDTA, 5 mM DTT, protease inhibitors, and 0.05% Triton X-100 for 90 minutes with vortexing. All these operations were performed at +4 °C. The protein content of the samples was determined by the Lowry method [31]. All extracts were used to measure caspase-3 (sc-56053) and caspase-9 (sc-56076) expression levels. Bladder, ovary, and kidney tissue samples, containing 100 µg of protein, were loaded onto 12% sodium dodecyl sulfate-polyacrylamide gels and transferred onto nitrocellulose membranes for 75 minutes at 80 V. The membranes were blocked with Tris buffers containing 1% BSA and 0.05% Tween-20 (TBS-T). After blocking, the membranes were incubated overnight at +4 °C with polyclonal primary antibodies [caspase-3 (1:200) or caspase-9 (1:200)]. Immunoblots were normalized using β-actin (1:200) as a loading control. The membranes were then incubated with anti-goat IgG secondary antibodies (1:1000) for 1 hour at 20 °C, followed by washing with TBS-T [32]. The antibody–antigen complexes were detected using nitro blue tetrazolium/5-bromo-4-chloro-3-indolyl-phosphate. Densitometric analysis was performed with Bio-Rad Molecular Analyst software (free edition, www.totallab.com). The molecular weights for caspase-3, caspase-9, and β-actin are 20 kDa, 46 kDa, and 43 kDa, respectively.

Statistical Analysis

The statistical analyses were conducted using GraphPad Prism 6.0 (GraphPad Software, San Diego, CA). Normal distribution was assessed with the Shapiro-Wilk test. Then, Tukey's multiple comparison post hoc test was applied to determine statistical significance after a one-way analysis of variance (One-way ANOVA). Variances were considered statistically significant at a $p<0.05$ level and are expressed as mean ± S.E.M.

3. RESULTS

Histopathological results

Histological examination of the kidney tissues revealed regular kidney morphology with renal corpuscles and tubules in the control group. However, Bowman space dilatation, glomerular and interstitial congestion, and moderate damage to the proximal tubule structure were detected in the IR group. In contrast, moderate glomerular and interstitial congestion and decreased damaged proximal tubule structures were observed in the MC-Ptx and MC-tx groups (Figure 2).

Light microscopy evaluation of the bladder showed regular urinary bladder morphology with mucosa and muscular layer in the control group, moderate urothelium damage and localized shedding and vascular congestion in the lamina propria in the IR group, the presence of urothelium with a reasonably regular morphology in the MC-Ptx group, and mild urothelium damage and shedding of apical urothelial cells in some areas in the MC-tx group (Figure 3).

Regular ovarium morphology with follicle structures was observed in the control group. Degenerated primordial, primary, secondary, and tertiary follicle structures, severe vascular congestion, and mild inflammatory cell infiltration were observed in the IR group, whereas, quite regular follicle morphologies in all periods, mild to moderate vascular congestion, and decreased inflammatory cell infiltration were observed in the MC-Ptx and MC-tx groups. (Figure 4).

Histological scores obtained in the bladder, kidney, and ovarian tissues were significantly higher in the IR arm compared to all other groups. Meanwhile, scores significantly decreased in MC groups, either pretreatment or treatment groups, compared to the IR group (Table II). However, no statistically significant difference was detected between the MC-PTx and MC-tx arms.

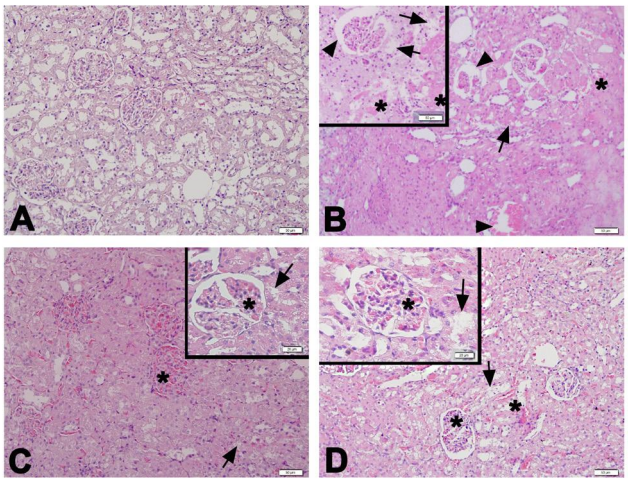

Figure 2. *Representative photomicrographs of kidney samples from the experimental groups. Regular renal corpuscles and proximal and distal tubules are seen in the control group (A). Dilatation of Bowman space (arrowhead), glomerular and interstitial vascular congestion (*), and degenerated proximal tubule structures (arrow) are seen in the IR group (B). Decrease of glomerular and interstitial vascular congestion (*) and degenerated proximal tubule structures (arrow) are seen in the MC-Ptx (C) and MC-tx (D) groups. H&E staining. Scale bars: 50 µm, insets C and D: 20 µm.*

Table II. *Histological scores among tissues of the experimental groups.*

	Control	IR	MC-Ptx	MC-tx
Kidney	0	6.83±0.75*	3.66±1.21□,**	3.00±0.63¶β
*p<0.001, □p=0.01 and ¶p=0.002 compared to control; **p=0.006 and β p<0.001 compared to IR				
Bladder	0	4.40±0.54*	1.40±0.54□**	2.20±0.83¶β
*p<0.001,□p=0.014 and ¶p=0.03 compared to control; **p<0.001 and β p=0.002 compared to IR				
Ovary	0	6.33±1.21*	4.00±0.63□**	3.66±0.81¶β
*p=0.004, □p=0.001 and ¶p=0.004 compared to control; **p=0.005 and β p=0.001 compared to IR				

SF: Oral saline; IR: Irradiation; MC: Myrtus communis

http://doi.org/10.5472/marumj.1798589
Marmara Med J 2025;38(3): 190-197

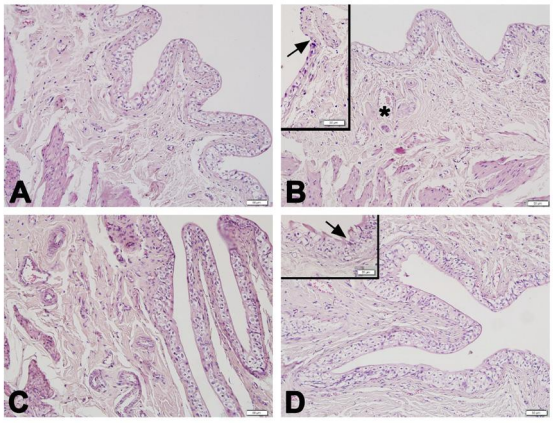

Figure 3. *Representative photomicrographs of urinary bladder samples from the experimental groups. Regular urinary bladder mucosa and muscular layers are seen in the control group (A). Urothelium damage and shedding (arrow) in some areas and vascular congestion in the lamina propria (*) are seen in the IR group (B). Quite regular urothelium morphology is seen in the MC-Ptx (C) group. A pretty regular urothelium morphology in most areas and apical urothelial shedding (arrow) in some areas are seen in the MC-tx (D) group. H&E staining. Scale bars: 50μm, inset D: 20 μm.*

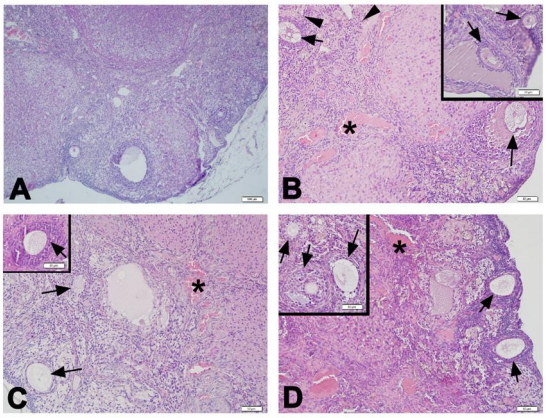

Figure 4. *Representative photomicrographs of the ovarium samples from the experimental groups. Regular ovarium morphology with follicle structures is seen in the control group (A). Degenerated secondary and tertiary follicle structures (arrow), severe vascular congestion (*), and mild inflammatory cells (arrowhead) are seen in the IR group (B). Quite regular secondary and tertiary follicle structures (arrow) and a decrease in vascular congestion (*) are seen in the MC-Ptx (C) and MC-tx (D) groups. H&E staining. Scale bars: 50μm.*

The densitometric analysis of protein immunoblots

The representative immunoblotting membranes of the different tissues are illustrated in Figure 5. While caspase-9 and caspase-3 levels increased in kidney tissues with IR when compared to the control group (t = 7.823, P = 0.0003, dF = 8; t = 8.276, P = 0.0002, dF = 8, respectively), MC decreased them significantly in the MC-treated (t = 7.363, P=0.0004, dF= 8; t = 5.803, P = 0.0020, dF = 8) and MC-pretreated groups (t = 8.897, P = 0.0001, dF = 8; t = 8.371, P = 0.0002, dF = 8 respectively) compared to the IR group (Figure 6). Caspase-9 and caspase-3 levels increased with IR in bladder tissue when compared to the control group (t = 4.798, P = 0.0068, dF = 8; t = 3.711, P = 0.0297, dF = 8; respectively). Both caspase-9 and caspase-3 levels were significantly decreased in the MC-treated group (t = 4.074, P = 0.0178, dF = 8; t = 4.935, P = 0.0057, dF = 8; respectively) and the MC-pretreated group (t = 5.161, P = 0.0043, dF = 8; t = 4.896, P = 0.0060, dF = 8) compared to the saline-treated IR group (Figure 6c and 6d). While caspase-9 and caspase-3 levels in ovarian tissue increased in the IR group compared to the control (t = 5.759, P = 0.0021, dF = 8; t = 4.435, P = 0.0109, dF =8), caspase-9 levels decreased in the MC-treated group (t = 5.294, P = 0.0037, dF = 8), but no difference was observed in caspase-3 levels. Both caspase-9 (t = 5.236, P = 0.0039, df = 8) and caspase-3 levels (t = 4.134, P = 0.0164, df = 8) were found to be significantly lower in the MC-pretreated group (Figure 6).



Figure 5. *The representative photographs of membranes collected from immunoblotting experiments for the IR rat model treated or pretreated with MC. For each group, n = 4, and the analyses were performed in duplicate. β-actin was used to normalize the amount of protein loaded in each lane. The molecular weights for caspase-3, caspase-9, and β-actin are 20kDa, 46kDa, and 43kDa, respectively. C: control group, IR: Ionizing radiation group, MC-tx: Myrtus communis treatment group, MC-Ptx: Myrtus communis pretreatment group*

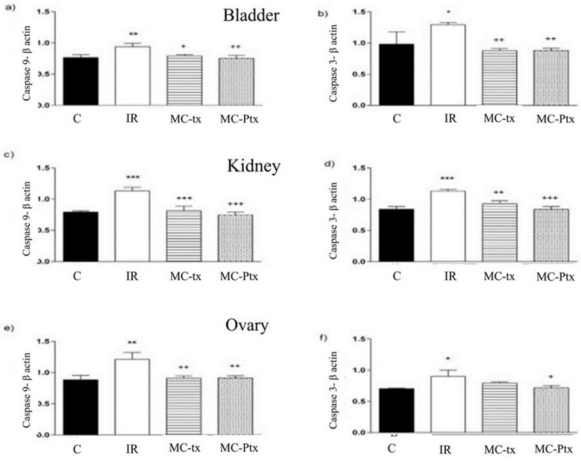

Figure 6. *Caspase-3 and caspase-9 levels for tissues according to study groups. C: control group, IR: Ionizing radiation group, MC-tx: Myrtus communis treatment group, MC-Ptx: Myrtus communis pretreatment group +: Comparisons according to the control group, *: Comparisons according to saline-treated IR group*
Caspase-3 and caspase-9 were normalized to β-actin. +/: p<0.05, ++/**: p<0.01, +++/***: p<0.001*

http://doi.org/10.5472/marumj.1798589
Marmara Med J 2025;38(3): 190-197

4. DISCUSSION

Ionizing radiation produces highly reactive free radicals such as superoxide anions (O_2^-), hydroxyl radicals (-OH), and hydrogen peroxide (H_2O_2). These ROS can damage cells by reacting with lipids, proteins, and DNA, resulting in lipid peroxidation, mutations, and cell death [2,4,5]. Flavonoids and phenolic acids may act as radical scavengers by donating electrons or hydrogen atoms to neutralize these reactive molecules. The hydroxyl groups in the structure of flavonoids and phenolic acids can interact with ROS, converting them into more stable molecules. This scavenging activity helps prevent oxidative damage to cellular components and may affect inflammatory pathways associated with radiation exposure [33-35].

Myrtus communis is a plant frequently used in traditional medicine for its therapeutic effects [1,16]. Its flavonoids, essential fatty acids, and bioactive components protect against both natural and chemical toxins. Previous studies have reported that the leaves of MC contain phenolic acids and flavonoids [20,25]. MC extract also has a very high amount of total phenol and flavonoid compounds [24]. Different studies have demonstrated MC's antioxidant, anti-inflammatory, antibacterial, and analgesic effects on tissue damage. Some research has highlighted MC's impact on tissue and organ damage caused by IR [35-38]. Seif et al., examined oxidative stress parameters in the blood of mice irradiated with 6 Gy in a single dose [36]. They showed that administering MC extract before irradiation may help prevent tissue damage by neutralizing free oxygen radicals. The cell culture study also indicated the radioprotective effect of MC extract on human peripheral lymphocytes [39]. In our study, one of the experimental groups involved prophylactic use of MC. We believe our findings are significant, as both therapeutic and preventive uses of MC help reduce radiation damage.

In radiation nephropathy, especially late effects are thought to develop secondary to oxidative stress and inflammation, and studies have been conducted with agents that are expected to reduce inflammation and cell death in animal models [10]. Our hypothesis was that these compounds would play a significant role in the radioprotective effect of MC against IR. We observed that radiation-induced damage in the kidney tissue, which decreased with MC extract during the acute period, and urothelial damage in the bladder was mild. Therefore, MC in the acute phase may be a potential option to prevent radiation-induced fibrosis and permanent damage that could develop later [40,41].

Flavonoids and phenolic acids also modulate radiation-induced apoptosis [42]. While apoptosis serves as a protective mechanism to eliminate damaged cells, excessive or inappropriate apoptosis can lead to tissue atrophy and functional impairment. These compounds can regulate apoptotic signaling by interacting with pro-apoptotic proteins such as caspases and anti-apoptotic proteins like Bcl-2. Additionally, flavonoids and phenolic acids have been shown to reduce fibrosis by inhibiting transforming growth factor-beta (TGF-β), a cytokine involved in the development of fibrosis [42]. Although there is no data on the anti-apoptotic effects of MC in the IR rat model, beneficial effects have been demonstrated in animal models using plants with antioxidant and anti-inflammatory properties, based on content analysis [32]. According to our immunoblotting results in the IR group, the increase in the levels of proapoptotic proteins caspase-3 and caspase-9 emphasizes the importance of apoptosis in radiation. Furthermore, the suppression of apoptosis with MC treatment and pretreatment suggests that MC may have a protective effect against radiation.

Radiation exposure often triggers an inflammatory response, further worsening cellular damage and fibrosis [37,41]. Inflammatory cytokines like tumor necrosis factor-alpha (TNF-α), interleukin (IL)-1 β, and IL-6 are released in response to oxidative stress and DNA damage, promoting chronic inflammation and tissue injury. Flavonoids and phenolic acids have been shown to modulate inflammatory pathways by inhibiting the activation of key pro-inflammatory signaling molecules such as nuclear factor kappa B and mitogen-activated protein kinases. By reducing the production of these inflammatory cytokines, these compounds may help lessen the inflammatory response and prevent further tissue damage after radiation exposure. In a previous study, the authors found that myrtle seed extract lowered plasma levels of TNF-α, IL-8, IL-6, and IL-1β, while also increasing the activity of antioxidant enzymes in an in vivo model of ethanol toxicity [42]. It would be valuable to explore whether MC works through a similar mechanism to reduce IR-induced damage.

Numerous studies have examined the use of drugs such as apoptosis inhibitors, tamoxifen, and growth hormone as protective agents against radiation-induced damage in ovarian tissue [9,41,43]. In our study, we observed for the first time a statistically significant reduction in the expression levels of caspase-9 and caspase-3 in ovarian tissue after treatment with MC. Due to the antiapoptotic and antioxidant properties of MC extract, it may be effective in shielding the ovaries from radiation damage.

Limitations

The radioprotective and anti-apoptotic effects of MC were only studied at the tissue level. We did not assess study parameters using blood values, which could be a limitation of our research. Additionally, we lacked direct measurements of the oxidative and inflammatory effects of IR. Another possible limitation is that we chose the entire body as the irradiation area. In clinical practice, radiotherapy is usually applied to specific local regions, such as tumors and their nearby lymph nodes. The effects of total-body irradiation may differ from those of localized irradiation in terms of strength and frequency. Our study is the first experimental investigation into the radiation damage-reducing effects of MC on pelvic organs. Future research should focus on exploring and evaluating the effects of MC in typical daily radiotherapy settings.

Conclusion

In conclusion, this study found that MC significantly decreases damage from IR in the ovaries, bladder, and kidneys of rats,

http://doi.org/10.5472/marumj.1798589
Marmara Med J 2025;38(3): 190-197

as observed both histopathologically and molecularly in *an in vivo* model. Our research is a pioneering effort to analyze the effects of MC as a radioprotectant for genitourinary tissues. Future studies should explore the molecular pathways in more detail, especially focusing on the role of specific flavonoids and phenolic acids in modulating the radioprotective response.

Acknowledgments

The authors sincerely thank Professor Göksel Şener from Fenerbahçe University for her invaluable guidance and contributions.

The authors sincerely thank Gizem Bulut, PhD, for her invaluable assistance in identifying the plant material.

Compliance with Ethical Standards

Ethical approval: All experimental protocols received approval from the Marmara University School of Medicine Animal Care and Use Committee (date: 17 May 2022; number: 34.2022mar) and were carried out in accordance with national and international guidelines on animal experimentation.

Conflict of interest: All authors state that they have no conflicts of interest or personal relationships that could have influenced the work reported in this paper.

Financial support: This study was supported by a research grant from the Turkish Radiation Oncology Society (TROD) with grant number TROD-GROG-004/2022.

Author contributions: SO and BD: Conceptualization, investigation, methodology, formal analysis, writing, and editing the manuscript, NO and FE: Methodology, formal analysis, validation, visualization, and manuscript editing, AA and BE: Methodology, formal analysis, validation, visualization, manuscript editing, AS: Investigation, methodology, validation, visualization, supervision, reviewing, and editing of the manuscript, CC: Investigation, methodology, validation, visualization, writing, and editing of the manuscript, BMA: Conceptualization, investigation, methodology, formal analysis, supervision, resources, reviewing and editing of the manuscript. All authors approved the final manuscript.

REFERENCES

[1] Kooti W, Servatyari K, Behzadifar M, et al. Effective medicinal plant in cancer treatment, Part 2: review study. J Evid Based Complementary Altern Med 2017;22:982-95. doi: 10.1177/215.658.7217696927. doi: 10.1177/215.658.7217696927

[2] Held KD. Radiobiology for the Radiologist. Hall EJ and Giaccia A J, editors. 6th edition. Radiat Res 2006;166:816-7.

[3] Trifiletti DM, Zaorsky NG, eds. Absolute Clinical Radiation Oncology Review. 1st edition. Cham: Springer International Publishing, 2019.

[4] Azzam EI, Jay-Gerin J-P, Pain D. Ionizing radiation-induced metabolic oxidative stress and prolonged cell injury. Cancer Lett 2012;327:48-60. doi: 10.1016/j.canlet.2011.12.012.

[5] Reisz JA, Bansal N, Qian J, Zhao W, Furdui CM. Effects of ionizing radiation on biological molecules—mechanisms of damage and emerging methods of detection. Antioxid Redox Signal 2014;21:260-92. doi: 10.1089/ars.2013.5489.

[6] Tretiakova I, Blaesius D, Maxia L, et al. Myrtucommulone from *Myrtus communis* induces apoptosis in cancer cells via the mitochondrial pathway involving caspase-9. Apoptosis 2008;13:119-31. doi: 10.1007/s10495.007.0150-0.

[7] Kim S, Kim S-W, Han S-J, et al. Molecular mechanism and prevention strategy of chemotherapy – and radiotherapy-induced ovarian damage. Int J Mol Sci 2021;22:7484. doi: 10.3390/ijms22147484.

[8] Chorbińska J, Krajewski W, Zdrojowy R. Urological complications after radiation therapy-nothing ventured, nothing gained: a narrative review. Transl Cancer Res 2021;10:1096-118. doi: 10.21037/tcr-20-2589.

[9] Stroud JS, Mutch D, Rader J, Powell M, Thaker PH, Grigsby PW.Effects of cancer treatment on ovarian function. Fertil Steril 2009;92:417-27. 7. doi: 10.1016/j.fertnstert.2008.07.1714.

[10] Klaus R, Niyazi M, Lange-Sperandio B. Radiation-induced kidney toxicity: molecular and cellular pathogenesis. Radiat Oncol 2021;16:43. . doi: 10.1186/s13014.021.01764-y.

[11] Wallace WHB, Thomson AB, Kelsey TW. The radiosensitivity of the human oocyte. Hum Reprod 2003;18:117-21. doi: 10.1093/humrep/deg016.

[12] Lushbaugh CC, Casarett GW. The effects of gonadal irradiation in clinical radiation therapy: a review. Cancer 1976;37:1111-25. doi: 10.1002/1097-0142(197602)37:2+<1111::aid-cncr282.037.0821>3.0.co;2-e.

[13] Wo JY, Viswanathan AN. Impact of radiotherapy on fertility, pregnancy, and neonatal outcomes in female cancer patients. Int J Radiat Oncol Biol Phys 2009;73:1304-12. doi: 10.1016/j.ijrobp.2008.12.016.

[14] Atasoy BM, Deniz M, Dane F, et al. Prophylactic feeding with immune-enhanced diet ameliorates chemoradiation-induced gastrointestinal injury in rats. Int J Radiat Biol 2010;86:867-79. doi: 10.3109/09553.002.2010.487026.

[15] Dong X-Z, Wang Y-N, Tan X, et al. Protective effect of JXT ethanol extract on radiation-induced hematopoietic alteration and oxidative stress in the liver. Oxid Med Cell Longev 2018;2018:9017835. doi: 10.1155/2018/9017835

[16] Hennia A, Miguel MG, Nemmiche S. Antioxidant activity of *Myrtus communis* L. and *Myrtus nivellei* Batt. & Trab. extracts: A brief review. Med (Basel, Switzerland) 2018;5:89, doi: 10.3390/medicines5030089.

[17] Mansour H, Ismael N, Hafez H. Ameliorative effect of septilin, an ayurvedic preparation against γ-irradiationinduced oxidative stress and tissue injury in rats. Indian J Biochem Biophys 2014;51:135-41.

[18] Vasconcelos TNC, Proença CEB, Ahmad B, et al. Myrteae phylogeny, calibration, biogeography and diversification patterns: Increased understanding in the most species rich tribe of Myrtaceae. Mol Phylogenet Evol 2017;109:113-37. doi: 10.1016/j.ympev.2017.01.002.

[19] Baharvand-Ahmadi B, Bahmani M, Naghdi, N et al. Review on phytochemistry, therapeutic and pharmacological effects of myrtus (*Myrtus communis*). Der Pharm Lett 2015;7:160-5.

[20] Romani A, Pinelli P, Mulinacci N, et al. Identification and quantitation of polyphenols in leaves of *Myrtus communis* L. Chromatographia 1999;49:17-20. doi: 10.1007/BF02467181.

[21] Sisay M, Gashaw T. Ethnobotanical, ethnopharmacological, and phytochemical studies of *Myrtus communis* linn: a popular herb in unani system of medicine. J Evid Based Complementary Altern Med 2017;22:1035–43. . doi: 10.1177/215.658.7217718958.

[22] Sen A, Kurkcuoglu M, Yıldırım A, et al. Chemical and biological profiles of essential oil from different parts of *Myrtus communis* L. subsp. *communis* from Turkey. Agric Conspec Sci 2020;85:71-8.

[23] Sen A, Ozkan S, Recebova K, et al. Effects of *myrtus communis* extract treatment in bile duct ligated rats. J Surg Res 2016;205:359-67. doi: 10.1016/j.jss.2016.06.094.

[24] Sen A, Yuksel M, Bulut G, et al. Therapeutic potential of *myrtus communis* subsp. *communis* extract against acetic acid-induced colonic inflammation in rats. J Food Biochem 2017;41:e12297. doi: 10.1111/jfbc.12297

[25] Arslan S, Ozcan O, Gokmen B, et al. Myrtle improves renovascular hypertension-induced oxidative damage in heart, kidney, and aortic tissue. Biologia (Bratisl) 2022;7:1877-88. doi: 10.1007/s11756.022.01039-1.

[26] Lenarczyk M, Lam V, Jensen E, et al. Cardiac injury after 10 gy total body irradiation: indirect role of effects on abdominal organs. Radiat Res 2013;180:247-58. doi: 10.1667/RR3292.1.

[27] Kal HB, van Kempen-Harteveld ML. Renal dysfunction after total body irradiation: dose-effect relationship. Int J Radiat Oncol Biol Phys 2006;65:1228-32. doi: 10.1016/j.ijrobp.2006.02.021.

[28] Cetiner M, Sener G, Sehirli AO, et al. Taurine protects against methotrexate-induced toxicity and inhibits leukocyte death. Toxicol Appl Pharmacol 2005;209:39-50. doi: 10.1016/j.taap.2005.03.009.

[29] Erkanli Senturk G, Erkanli K, Aydin U, et al. The protective effect of oxytocin on ischemia/reperfusion injury in rat urinary bladder. Peptides 2013;40:82-8. doi: 10.1016/j.peptides.2012.12.006.

[30] Tekin YB, Tumkaya L, Mercantepe T, et al. Evaluation of the protective effect of coenzyme Q10 against x-ray irradiation-induced ovarian injury. J Obstet Gynaecol Res 2024;50:1242-9. doi: 10.1111/jog.15966.

[31] Lowry OH, Rosebrough NJ, Farr AL, Randall RJ. Protein measurement with the Folin phenol reagent. J Biol Chem 1951;193:265-75.

[32] Aykac A, Ozbeyli D, Uncu M, et al. Evaluation of the protective effect of *Myrtus communis* in scopolamine-induced Alzheimer model through cholinergic receptors. Gene 2019;689:194-201. doi: 10.1016/j.gene.2018.12.007.

[33] Hosseinimehr SJ. Flavonoids and genomic instability induced by ionizing radiation. Drug Discov Today 2010;15:907-18. doi: 10.1016/j.drudis.2010.09.005.

[34] Vasin M V. Bioflavonoids as important component of biological protection from ionizing radiation. Food Nutr Sci 2014;5:472-9. doi: 10.4236/fns.2014.55056

[35] Wang Q, Xie C, Xi S, et al. Radioprotective effect of flavonoids on ionizing radiation-induced brain damage. Molecules 2020;25:5719. doi: 10.3390/molecules25235719.

[36] Seif F, Bayatiani MR, Ansarihadipour H, Habibi G, Sadelaji S. Radiation protection properties of *Myrtus communis* against oxidation caused by whole-body exposure of mice. Iran J Med Phys 2018;15:70.

[37] Zhao D, Qu H, Guo J, et al. Protective effects of myrtol standardized against radiation-induced lung injury. Cell Physiol Biochem 2016;38:619-34. doi: 10.1159/000438655

[38] Duncan FE, Kimler BF, Briley SM. Combating radiation therapy-induced damage to the ovarian environment. Future Oncol 2016;12:1687-90. doi: 10.2217/fon-2016-0121

[39] Jouhmany O, Ebrahim N, Ikhtiar A. Assessment of radio protective effects of *Myrtus communis* l. on human lymphocytes irradiated in vitro by gamma-rays using micronucleus assay on binucleated human lymphocytes. Int J Sci Res Biol Sci 2020;7:53-8.

[40] Zhao W, Robbins MEC. Inflammation and chronic oxidative stress in radiation-induced late normal tissue injury: therapeutic implications. Curr Med Chem 2009;16:130-43. doi: 10.217.409.2986709.787.002790

[41] Sharma A, Wairkar S. Flavonoids for treating pulmonary fibrosis: Present status and future prospects. Phytother Res 2024;38:4406-23.

[42] Jabri MA, Marzouki L, Sebai H. Myrtle berries seeds aqueous extract abrogates chronic alcohol consumption-induced erythrocytes osmotic stability disturbance, haematological and biochemical toxicity. Lipids Health Dis 2018;17:94. doi: 10.1186/s12944.018.0746-0.

[43] Abotaleb M, Samuel SM, Varghese E, et al. Flavonoids in cancer and apoptosis. Cancers (Basel) 2018;11. doi: 10.3390/cancers11010028.

SUPPLEMENT

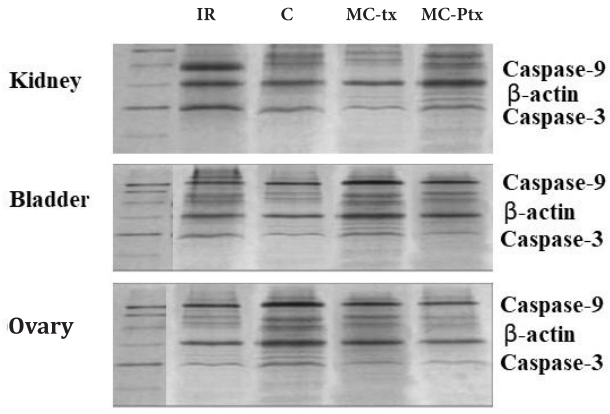

Supplement Figure: *The original image of western blotting (immunoblotting)*