DOI: 10.4274/MMJ.galenos.2026.36236
Medeni Med J

Original Article

Differentiating Pure and Mixed Mucinous Breast Carcinoma Using Multimodality Imaging: A Retrospective Single-Center Study

Multimodal Görüntüleme ile Saf ve Mikst Müsinöz Meme Karsinomlarının Ayırt Edilmesi: Retrospektif Tek Merkezli Bir Çalışma

Gülnur ERDEM[1], Mahmut Bilal DOGAN[2], Mizgin YAMER[1], Fatma YILMAZER[3], Gözde KIR[3], Hakan BAYSAL[4], Nesrin GUNDUZ[1]

[1]İstanbul Medeniyet University Faculty of Medicine, Department of Radiology, İstanbul, Türkiye
[2]Marmara University Faculty of Medicine, Department of Radiology, İstanbul, Türkiye
[3]İstanbul Medeniyet University Faculty of Medicine, Department of Pathology, İstanbul, Türkiye
[4]İstanbul Medeniyet University Faculty of Medicine, Department of General Surgery, İstanbul, Türkiye

ABSTRACT

Objective: This study aimed to evaluate the efficacy of mammography, ultrasound, and magnetic resonance imaging (MRI) features in differentiating pure from mixed mucinous breast carcinoma and in identifying imaging characteristics specific to each subtype.

Methods: This retrospective single-center study included 68 patients diagnosed with mucinous breast carcinoma between 2017 and 2024. The tumors were classified as pure or mixed mucinous breast carcinomas based on histopathological findings. All available mammography, ultrasound, and MRI examinations were evaluated by a radiologist blinded to the histopathological subtypes. The features, such as tumor shape, margin, signal intensity, mammographic density, echogenicity, and calcifications, were assessed to identify distinctive patterns associated with pure and mixed mucinous breast tumors.

Results: Among the 68 patients, 31 (45.6%) had pure mucinous tumors, while 37 (54.4%) had mixed tumors. On ultrasound, pure mucinous carcinomas more frequently demonstrated an oval shape and a homogeneous internal echo pattern, whereas mixed tumors more frequently exhibited an irregular shape ($p<0.05$). Mammography showed that non-circumscribed margins were significantly more common in mixed tumors than in pure tumors ($p=0.02$). On MRI, pure mucinous carcinomas predominantly exhibited oval or lobulated shapes, whereas mixed tumors more frequently exhibited irregular shapes ($p=0.02$). Pure tumors also showed higher T2 signal intensity ($p=0.02$) and significantly higher median apparent diffusion coefficient (ADC) values than mixed tumors (1815 [interquartile range (IQR), 1596-2062.5] vs. 1336.5 [IQR, 904.25-1602.5]$\times 10^{-6}$ mm²/s, $p=0.01$).

Conclusions: A multimodal imaging approach facilitates differentiation between pure and mixed mucinous breast carcinomas. Among the evaluated modalities, MRI provided the greatest discriminatory value, particularly through T2 signal intensity and ADC measurements, and may complement core needle biopsy when tissue sampling is limited.

Keywords: Pure mucinous breast carcinoma, mixed mucinous breast carcinoma, ultrasound, mammography, MRI

ÖZ

Amaç: Bu çalışma, mamografi, ultrasonografi ve manyetik rezonans görüntüleme (MRG) bulgularının saf ve mikst müsinöz meme karsinomunu ayırt etmedeki etkinliğini değerlendirmeyi ve her iki alt tipe özgü görüntüleme özelliklerini belirlemeyi amaçlamaktadır.

Yöntemler: Çalışma retrospektif, tek merkezli olarak yürütüldü. 2017-2024 yılları arasında müsinöz meme karsinomu tanısı alan 68 hastanın verileri incelendi. Olgular saf ve mikst müsinöz meme karsinomu olarak sınıflandırıldı. Mevcut tüm mamografi, ultrasonografi ve MRG görüntüleri histopatolojik alt tiplerden bağımsız olarak radyolog tarafından değerlendirildi. Tümör şekli, sınır özellikleri, sinyal intensitesi, mamografik dansite, ultrasonografik ekojenite ve kalsifikasyon gibi özellikler, saf ve mikst müsinöz tümörlere özgü ayırt edici paternleri belirlemek amacıyla analiz edildi.

Bulgular: Çalışmaya dahil edilen 68 hastanın 31'inde (%45,6) saf, 37'sinde (%54,4) mikst müsinöz tümör mevcuttu. Ultrasonografide saf müsinöz karsinomlar daha sık oval şekil ve homojen iç eko patern gösterirken, mikst tümörlerde düzensiz şekil daha sık izlendi ($p<0,05$). Mamografide mikst tümörlerde düzensiz kenar özellikleri, saf tümörlere kıyasla anlamlı olarak daha sık saptandı ($p=0,02$). MRG'de saf müsinöz karsinomlar ağırlıklı olarak oval veya lobüle şekil gösterirken, mikst tümörler daha sık düzensiz şekilli idi ($p=0,02$). Ayrıca saf tümörlerde T2 sinyal intensitesi daha yüksek ($p=0,02$) ve ortanca görünür difüzyon katsayısı (ADC) değeri mikst tümörlere göre anlamlı olarak daha fazlaydı (1815 [çeyrekler arası aralık (IQR): 1596-2062,5] vs. 1336,5 [IQR: 904,25-1602,5]$\times 10^{-6}$ mm²/s, $p=0,01$).

Sonuçlar: Multimodal görüntüleme yaklaşımı, saf ve mikst müsinöz meme karsinomlarının ayırt edilmesine katkı sağlamaktadır. Değerlendirilen yöntemler arasında MRG, özellikle T2 sinyal intensitesi ve ADC ölçümleri ile en yüksek ayırt edici değeri göstermiş olup, doku örneklemesinin yetersiz olabileceği durumlarda histopatolojik değerlendirmeyi destekleyici ek bilgiler sağlayabilir.

Anahtar kelimeler: Saf müsinöz meme karsinomu, mikst müsinöz meme karsinomu, ultrasonografi, mamografi, MRG

Address for Correspondence: M. B. Doğan, Marmara University Faculty of Medicine, Department of Radiology, İstanbul, Türkiye
E-mail: mahmutbilaldogan@gmail.com **ORCID ID:** orcid.org/0000-0001-7063-7371
Received: 29.04.2026 **Accepted:** 23.08.2026 **Epub:** 02.09.2026

Cite as: Erdem G, Doğan MB, Yamer M, et al. Differentiating pure and mixed mucinous breast carcinoma using multimodality imaging: a retrospective single-center study. Medeni Med J. [Epub Ahead of Print]

Copyright© 2026 The Author(s). Published by Galenos Publishing House on behalf of Istanbul Medeniyet University Faculty of Medicine.
This is an open access article under the Creative Commons AttributionNonCommercial 4.0 International (CC BY-NC 4.0) License.

INTRODUCTION

Mucinous carcinoma accounts for approximately 2% of all invasive breast cancers, and is a type of breast cancer mostly observed in older women (>55 years)[1,2]. Histologically, mucinous breast carcinoma is classified into pure and mixed subtypes, and these subtypes show significant differences especially in terms of prognosis and tumor characterization[3,4]. The differentiation between pure and mixed mucinous breast cancer is important for determining the appropriate treatment approach, predicting the likelihood of recurrence, and informing the overall management of the disease. Accurate diagnosis and classification of mucinous breast cancer are essential to ensure patients receive the most appropriate and effective care.

Although core needle biopsy is the standard diagnostic method for breast cancer, it may not always accurately distinguish pure from mixed mucinous carcinoma because only a limited portion of the tumor is sampled. Mixed tumors may contain focal non-mucinous invasive components that are not represented in biopsy specimens, potentially leading to underestimation of tumor aggressiveness and inappropriate treatment planning. Consequently, reliable imaging biomarkers capable of predicting the histological subtype before surgery would be of considerable clinical value. Radiologic imaging plays a central role in the diagnosis and management of mucinous breast cancer. Previous studies have suggested that radiologic imaging techniques such as mammography, ultrasound, and magnetic resonance imaging (MRI) can be used to identify differences between pure and mixed mucinous breast cancer[5,6]. Key differences in the appearance of these cancers on radiologic images can be used to differentiate between them. The appearance of these cancers can vary widely and may not always be easy to distinguish from one another. A combination of radiologic imaging techniques and other diagnostic tools, such as biopsy, is often used to accurately diagnose and classify mucinous breast cancer.

The aim of this study was to assess the ability of multimodal imaging features, particularly MRI characteristics, to differentiate between pure and mixed mucinous breast carcinomas, as well as to identify imaging findings that may complement histopathological diagnosis when tissue sampling is limited.

MATERIALS and METHODS

Study Design and Population

The study was conducted retrospectively at a single center following approval by the İstanbul Medeniyet University Göztepe Training and Research Hospital Clinical Research Ethics Committee (decision number 2023/0050) on January 25, 2023. Data from 68 patients at our hospital diagnosed with mucinous breast carcinoma between 2017 and 2024 were examined. The cases were classified as pure or mixed mucinous breast carcinomas according to the final histopathological diagnosis. The study used de-identified medical records and imaging reports from patients diagnosed with mucinous breast carcinoma.

Data Collection

Clinical and demographic data, including age, sex, tumor location, molecular subtype, axillary lymph node status, and histopathological findings, were extracted from the electronic medical records of the eligible patients. Multimodality imaging data, including mammography, ultrasound, and MRI reports, were also collected for each patient.

MRI examinations were performed on 1.5-T GE scanners (Optima MR450w and MR360) using a dedicated breast coil. A gadolinium-based contrast agent was administered for dynamic contrast-enhanced imaging. Diffusion-weighted imaging was acquired using b-values of 0, 800, and 1000 s/mm^2. Apparent diffusion coefficient (ADC) values were measured by placing a single, standardized region of interest (ROI) on the corresponding ADC map. Dynamic contrast-enhanced MRI time-intensity curves were analyzed to calculate the signal enhancement ratio (SER), positive enhancement integral (PEI), time to peak (TTP), and maximum slope of increase (MSI). Quantitative kinetic analysis was performed on a GE AW VolumeShare 7 workstation.

Imaging Analysis

All imaging examinations were reviewed by a single radiologist with 9 years of experience in breast imaging, who was blinded to the histopathological diagnosis.

- **Mammography:** Specific mammographic features, such as tumor shape, margins, mammographic density, and calcifications, were assessed to identify distinctive patterns associated with pure and mixed mucinous breast tumors.

- **Ultrasound:** Breast ultrasound images were reviewed by the same radiologist who evaluated the mammography images. The focus was on analyzing sonographic characteristics, including lesion shape, margins, echogenicity, and internal echo pattern (homogeneous or heterogeneous).

- **Magnetic Resonance Imaging**: MRI images were reviewed, blinded to the clinical data. Subsequently, morphological characteristics (size, shape, margin), signal

intensity features (T1A, T2A), and contrast enhancement patterns (homogeneous, heterogeneous, peripheral, rim) of the tumor focus identified on MRI were recorded. The quantitative parameters (SER, PEI, TTP, and MSI) were then compared between the two groups.

Histopathological Correlation

Histopathological data, including tumor subtype (pure or mixed mucinous carcinoma), were obtained from biopsy and surgical pathology reports. The final pathological diagnosis was established using postoperative surgical specimens, which served as the reference standard for all analyses. Pure mucinous carcinoma was defined as a tumor with a mucinous component comprising more than 90% of the lesion, whereas tumors with a mucinous component of 90% or less that were associated with conventional invasive carcinoma were classified as mixed mucinous carcinoma. Radiological findings were subsequently correlated with the histopathological diagnosis.

Statistical Analysis

Descriptive statistics were used to summarize the demographic, clinical, and imaging characteristics of the study population. The collected data were analyzed using SPSS v26.0 (IBM Corp., Armonk, NY, USA). The distribution of continuous variables was assessed using the Shapiro-Wilk test. Continuous variables were summarized as mean ± standard deviation for normally distributed data and median [interquartile range (IQR)] for non-normally distributed data. Categorical variables were presented as numbers and percentages [n (%)]. Statistical relationships between imaging features and histopathology were examined using the independent-samples t-test for normally distributed continuous variables and the Mann-Whitney U test for non-normally distributed variables. For categorical variables, the Pearson χ^2 or Fisher's exact test was employed. Receiver operating characteristic (ROC) curve analysis was used to evaluate the diagnostic accuracy of specific imaging features to discriminate between pure and mixed mucinous breast tumors. ROC analysis included area under the curve (AUC) with 95% confidence interval (CI), sensitivity, and specificity; the optimal cut-off was determined using the Youden index. A p-value of <0.05 was considered statistically significant.

RESULTS

Of the 68 patients with mucinous breast carcinoma included in the study, 31 (45.6%) had pure mucinous tumors and 37 (54.4%) had mixed tumors (Table 1). Luminal A was the predominant molecular subtype in both groups, accounting for 28 patients (90.3%) in the pure group and 30 patients (81.1%) in the mixed group. Luminal B tumors were observed in 3 (9.7%) and 6 (16.2%) patients, respectively, while one HER2-positive tumor (2.7%) was present in the mixed group (p=0.46).

Among the 37 mixed mucinous carcinomas, five tumors were initially diagnosed as pure mucinous carcinoma on core needle biopsy but were reclassified as mixed mucinous carcinoma following surgical excision.

In the mixed group, the most frequent concomitant tumor was invasive ductal carcinoma, which was observed in 20 patients (54.1%). Evaluation of tumor multicentricity identified multicentricity in 6 patients (19.4%) with pure tumors and in 10 patients (27%) with mixed tumors (p=0.50). Axillary lymph node metastasis was identified in 2 patients (6.5%) in the pure group, including 1 case of micrometastasis and 1 case of isolated tumor cells. In contrast, 18 patients (48.6%) with mixed mucinous carcinoma had axillary metastasis (p=0.01).

Among the patients included in the study, ultrasound examinations were available for 60, mammography for 42, and MRI for 47.

Among the 60 patients who underwent ultrasound, in the pure mucinous group 3 (11.5%) lesions were isoechoic and 23 (88.5%) were hypoechoic, whereas all lesions in the mixed mucinous group were hypoechoic (Figure 1). Lesion margins were generally non-circumscribed in both groups, and only two patients had circumscribed margins in the mixed mucinous group. In terms of shape, lesions in the pure group were oval/round in 15 patients (57.7%) and irregular in 11 patients (42.3%).

Table 1. Demographic characteristics of the cases

Patients	**Pure (n=31)**	**Mixed (n=37)**	**p-value**
Age (mean)	61.5±15.9	64.4±13.3	0.54
Molecular subtype			0.46
Luminal A	28 (90.3%)	30 (81.1%)	
Luminal B	3 (9.7%)	6 (16.2%)	
HER2	0 (0.0%)	1 (2.7%)	

Among the 42 patients who underwent mammography, the majority of pure mucinous carcinomas presented as masses (14/17). In the mixed group, 23 of 25 lesions presented as a mass, whereas two lesions manifested as focal asymmetry (Table 2).

Among the 47 patients who underwent MRI, several morphological and quantitative imaging features differed significantly between pure and mixed mucinous carcinomas. Pure mucinous carcinomas were predominantly oval or lobulated (Figure 2), whereas mixed tumors were more frequently irregular in shape (p=0.02). Similarly, irregular margins predominated in pure tumors, whereas spiculated margins were significantly more common in mixed tumors (p=0.01). In both groups, the T1 signal was hypointense in the majority of patients (Figure 3). On T2-weighted images, pure tumors were often distinguished by their high signal intensity (p=0.02). Mucin lakes were observed in 45.5% of pure tumors and in 32% of mixed tumors on the T2W sequence (p=0.29). No statistically significant differences were observed in contrast enhancement patterns and contrast curves between the two groups. The Type 2 curve pattern was more common in both groups. No statistically significant differences were observed in the quantitative parameters of the time-intensity curve between the two groups (Figure 4). The median ADC value was significantly higher in pure mucinous tumors than in mixed tumors [1815 (IQR, 1596-2062.5) vs. 1336.5 (IQR, 904.25-1602.5)$\times 10^{-6}$ mm^2/s, p=0.01] (Table 3 and Figure 5).

The ROC analysis demonstrated good diagnostic performance of ADC in differentiating pure from mixed mucinous breast carcinoma, with an AUC of 0.832 (CI: 0.712-0.953). The optimal ADC cut-off value determined by the Youden index was 1702×10^{-6} mm^2/s, yielding a sensitivity of 65.0% and a specificity of 91.7%. ROC analysis demonstrated that the quantitative dynamic contrast-enhanced MRI parameters had no significant discriminatory performance. The AUC values were 0.574 (95% CI, 0.393-0.755) for SER, 0.572 (95% CI, 0.390-0.754) for PEI, 0.557 (95% CI, 0.376-0.739) for TTP, and 0.526 (95% CI, 0.347-0.705) for MSI (all p>0.05).

DISCUSSION

In this study, pure and mixed mucinous breast carcinomas demonstrated distinct imaging characteristics across multiple modalities. The most important findings were that pure mucinous carcinomas exhibited significantly higher ADC values, more frequent high T2 signal intensity, and a predominance of oval or lobulated morphology. In contrast, mixed tumors more commonly exhibited irregular shapes, spiculated margins, and markedly higher rates of axillary lymph node metastasis. Notably, five tumors initially diagnosed as pure mucinous carcinoma on core needle biopsy were reclassified as mixed mucinous carcinoma after surgical excision, underscoring the potential complementary role of MRI when biopsy underestimates tumor heterogeneity.

The majority of pure mucinous tumors were hypoechoic, and over half had oval or round shapes. Mixed mucinous tumors more frequently exhibited an irregular shape on ultrasound, whereas the lesion margins were predominantly non-circumscribed in both groups. These findings align with previous studies that emphasize

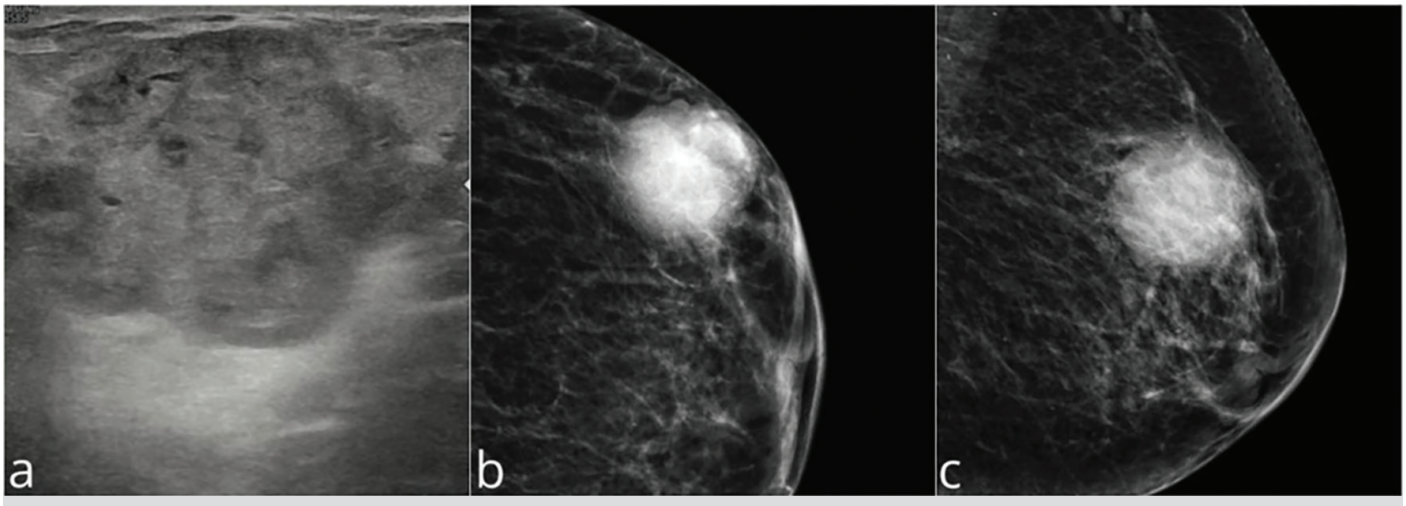

Figure 1. An 80-year-old woman with pure mucinous breast carcinoma. Ultrasound image (a) demonstrates a heterogeneous hypoechoic mass. Craniocaudal (b) and mediolateral oblique (c) mammograms show a circumscribed high-density mass without suspicious calcifications

Table 2. Ultrasound and mammography findings of the pure and mixed tumors			
Features	**Pure (n=26)**	**Mixed (n=34)**	**p-value**
Ultrasound (n=60)			
Echogenicity			0.08
Hypoechoic	23 (88.5%)	34 (100%)	
Isoechoic	3 (11.5%)	0 (0.0%)	
Hyperechoic	0 (0.0%)	0 (0.0%)	
Shape			**0.01**
Oval	13 (50.0%)	5 (14.7%)	
Round	2 (7.7%)	8 (23.5%)	
Irregular	11 (42.3%)	21 (61.8%)	
Margin			0.64
Circumscribed	3 (11.5%)	2 (5.9%)	
Non-circumscribed	23 (88.5%)	32 (94.1%)	
Internal echo pattern			**0.01**
Homogeneous	10 (38.5%)	2 (5.9%)	
Heterogeneous	16 (61.5%)	32 (94.1%)	
Mammography (n=42)	**Pure (n=17)**	**Mixed (n=25)**	
Mass/asymmetry			0.18
Mass	14 (82.4%)	23 (92.0%)	
Asymmetry	3 (17.6%)	2 (8.0%)	
Shape			0.41
Oval	6 (35.3%)	5 (20.0%)	
Round	2 (11.8%)	1 (4.0%)	
Lobulated/irregular	9 (52.9%)	19 (76.0%)	
Margin			**0.02**
Circumscribed	7 (41.2%)	5 (20.0%)	
Non-circumscribed	10 (58.8%)	20 (80.0%)	
BI-RADS			**0.04**
0	1 (5.9%)	4 (16.0%)	
1	0 (0.0%)	0 (0.0%)	
2	0 (0.0%)	0 (0.0%)	
3	5 (29.4%)	1 (4.0%)	
4	7 (41.2%)	2 (8.0%)	
5	4 (23.5%)	18 (72.0%)	
BI-RADS: Breast Imaging Reporting and Data System			

the more benign appearance of pure mucinous tumors compared to the more aggressive features of mixed subtypes[7,8]. Although ultrasound findings alone may not reliably distinguish between the two subtypes, they may complement MRI findings and contribute to the overall radiologic assessment.

Mammography revealed that pure mucinous tumors typically present as masses, and calcifications are relatively

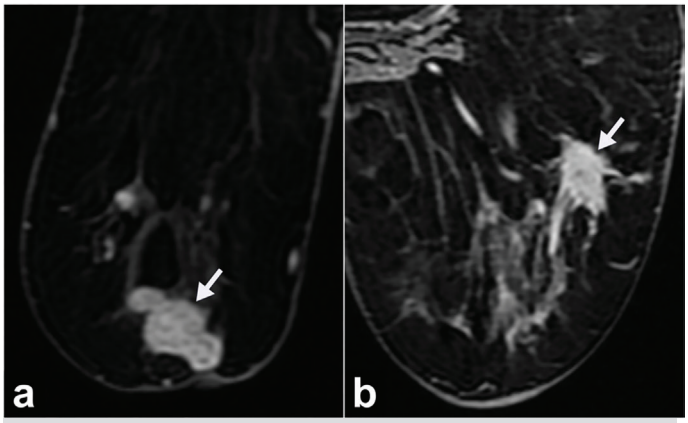

Figure 2. In the post-contrast T1-weighted image of a pure mucinous tumor, a lobulated shape and irregular margin are observed (a). In the mixed mucinous tumor, an irregular shape and spiculated margin are notable (b)

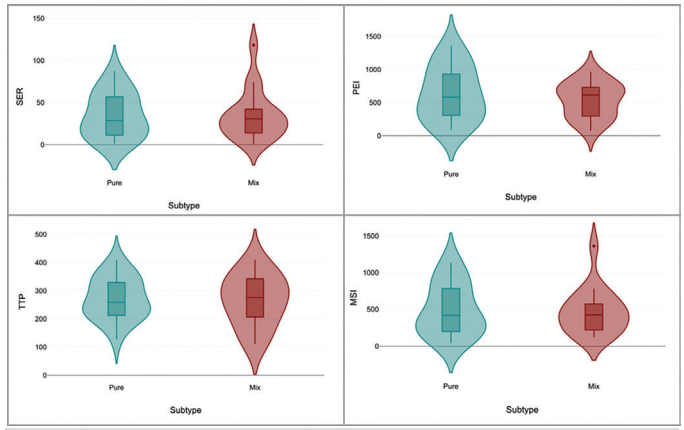

Figure 4. Comparison of dynamic MRI data of pure and mixed tumors in violin plots

MRI: Magnetic resonance imaging, SER: Signal enhancement ratio, PEI: Positive enhancement integral, TTP: Time to peak, MSI: Maximum slope of increase

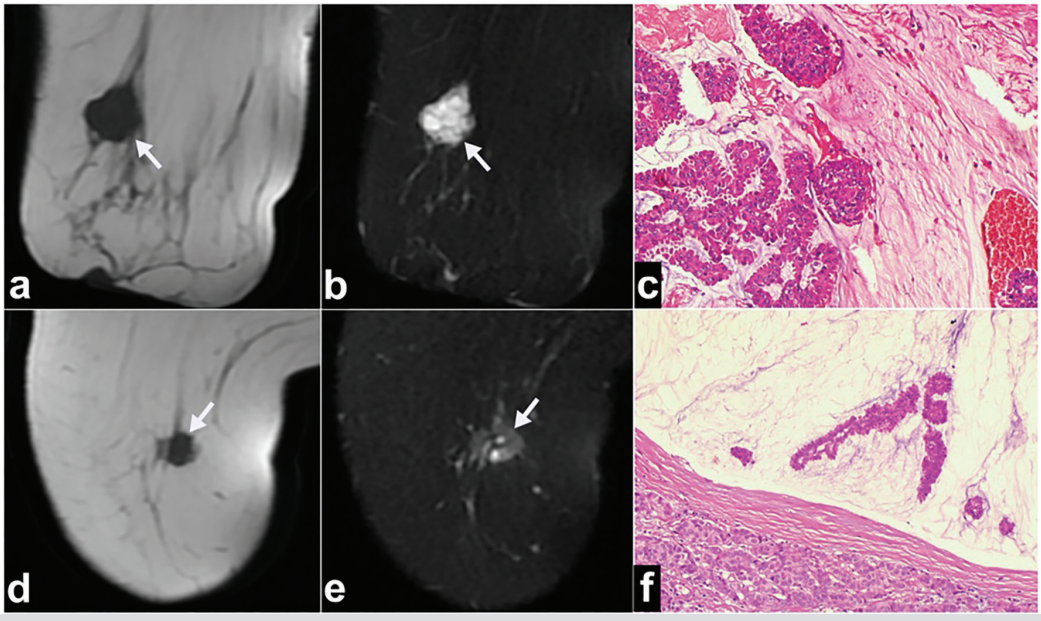

Figure 3. The pure mucinous tumor appears hypointense on the T1-weighted image (a) and hyperintense on the T2-weighted image (b). Low-to intermediate grade tumor cell clusters immersed in extracellular mucin deposits. Cell nests are divided by fibrous septa containing blood vessels (Hematoxylin and eosin staining, original magnification x200) (c). The mixed mucinous tumor, on the other hand, is hypointense on the T1W image (d) and shows low signal on the T2W image (e). Tumor containing both mucinous and non-mucinous invasive components (hematoxylin and eosin staining, original magnification x200) (f)

uncommon. Mixed mucinous tumors, on the other hand, showed a higher incidence of calcifications and, in some cases, asymmetry[9-11]. The presence of calcifications in mixed tumors underscores their more aggressive biological behavior and suggests that mammography may provide complementary information, but is of limited value for reliably distinguishing the two subtypes.

MRI provided the greatest discriminatory value among the evaluated imaging modalities. While T1-weighted signal intensity showed limited diagnostic utility, pure mucinous carcinomas demonstrated significantly higher T2 signal intensity, reflecting their abundant extracellular mucin content. Mixed tumors exhibited lower T2 signal intensity, presumably because of their greater proportion

Table 3. MRI findings of the 47 cases			
MRI features	**Pure (n=22)**	**Mixed (n=25)**	**p-value**
Size (mm)	27.2±19.3	24.6±8.6	0.69
Shape			**0.02**
Round	0 (0.0%)	0 (0.0%)	
Oval	3 (13.6%)	3 (12.0%)	
Lobulated	14 (63.6%)	8 (32.0%)	
Irregular	5 (22.7%)	14 (56.0%)	
Margin			**0.01**
Smooth	3 (13.6%)	3 (12.0%)	
Irregular	17 (77.3%)	10 (40.0%)	
Spiculated	2 (9.1%)	12 (48.0%)	
T1 signal			0.51
Hypointense	20 (90.9%)	20 (80.0%)	
Isointense	2 (9.1%)	5 (20.0%)	
Hyperintense	0 (0.0%)	0 (0.0%)	
T2 signal			**0.02**
Hypointense	0 (0.0%)	7 (28.0%)	
Isointense	6 (27.3%)	9 (36.0%)	
Hyperintense	16 (72.7%)	9 (36.0%)	
Enhancement pattern			0.23
Rim	4 (18.2%)	1 (4.0%)	
Heterogeneous	18 (81.8%)	21 (84.0%)	
Homogeneous	0 (0.0%)	3 (12.0%)	
[a]CE-MRI quantitative parameters			
[b]SER	30.16 [11.56-58.19]	28.91 [15.60-42.03]	0.42
[c]PEI	816.00 [488.75-1097.00]	614.60 [286.55-752.80]	0.32
[d]TTP	268.45 [212.90-329.68]	259.45 [198.30-312.23]	0.44
[e]MSI	417.95 [199.13-784.63]	379.10 [171.10-570.08]	0.99
ADC value, median [IQR]	1815 [1596-2062.5]	1336.5 [904.25-1602.5]	**0.01**

[a]: CE-MRI: Contrast-enhanced magnetic resonance imaging, [b]: SER: Signal enhancement ratio, [c]: PEI: Positive enhancement integral, [d]: TTP: Time to peak, [e]: MSI: Maximum slope of increase, ADC: Apparent diffusion coefficient, IQR: Interquartile range

of non-mucinous invasive components. These findings are consistent with the known pathological composition of mucinous breast carcinoma and with previous MRI studies[12,13]. Diffusion-weighted imaging proved particularly valuable for subtype differentiation. Pure mucinous carcinomas demonstrated substantially higher ADC values than mixed tumors, consistent with the lower cellularity and abundant extracellular mucin characteristic of pure lesions. In contrast, the lower ADC values observed in mixed tumors likely reflect increased cellularity associated with invasive non-mucinous components. These findings support the role of ADC as a quantitative imaging biomarker for predicting histological subtype before surgery.

Previous studies have suggested that ADC values exceeding approximately 1500×10^{-6} mm^2/s are more commonly associated with pure mucinous carcinoma[14,15]. In our cohort, ROC analysis identified an optimal ADC cut-off value of 1702×10^{-6} mm^2/s (AUC=0.832), with sensitivity 65.0% and specificity 91.7%. The slightly higher threshold

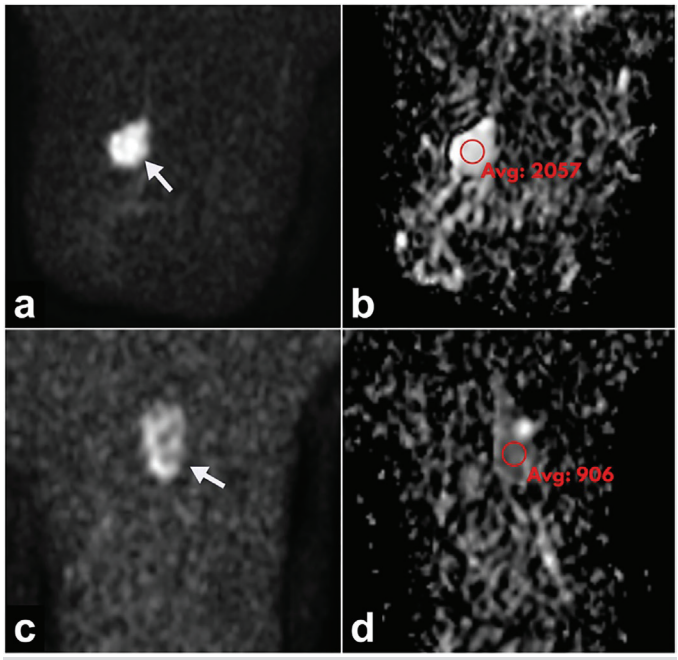

Figure 5. The pure mucinous tumor shows high signal on both the diffusion-weighted imaging (DWI) and the apparent diffusion coefficient (ADC) maps (a,b). In the mixed mucinous tumor, high signal is observed on the DWI, while a low signal is seen on the ADC map (c,d)

observed in our study may reflect differences in patient population, imaging protocols, and ROI measurement techniques. Nevertheless, our findings further support the clinical utility of ADC for differentiating pure from mixed mucinous breast carcinoma.

Contrast enhancement patterns and kinetic curves showed no significant differences between the subtypes, with both groups predominantly showing Type 2 kinetic curves. This finding suggests that dynamic contrast-enhanced MRI alone may not reliably differentiate between pure and mixed mucinous tumors. However, the combination of morphological features, signal intensities, and ADC values provides a robust framework for subtype differentiation[16].

From a clinical perspective, these findings suggest that MRI may be particularly useful when histopathological evaluation based on core needle biopsy is inconclusive or potentially affected by sampling error. In our cohort, five tumors initially classified as pure mucinous carcinoma on biopsy were ultimately diagnosed as mixed mucinous carcinoma after surgical excision. Recognition of imaging features suggestive of mixed histology may, therefore, alert clinicians to possible under-sampling and facilitate more appropriate surgical planning and patient counseling.

The findings of this study underscore the importance of a multimodal imaging approach in the evaluation of mucinous breast carcinomas. Ultrasound and mammography serve as essential initial diagnostic tools, offering valuable information on lesion morphology and calcifications. MRI, with its superior soft-tissue contrast and quantitative capabilities such as ADC mapping, plays a pivotal role in refining the differential diagnosis and providing a comprehensive assessment of tumor characteristics.

Although previous studies have reported the characteristic high T2 signal intensity and elevated ADC values in pure mucinous carcinoma, our findings extend the existing literature by providing a comprehensive multimodal imaging comparison of pure and mixed mucinous carcinomas. In addition to confirming the diagnostic value of conventional MRI morphology and diffusion-weighted imaging, our study demonstrates that quantitative dynamic contrast-enhanced MRI parameters, including SER, PEI, TTP, and MSI, do not provide additional discriminatory value in distinguishing the two subtypes. These findings suggest that routine MRI assessment should primarily focus on morphological features and diffusion characteristics rather than quantitative kinetic parameters.

Integrating imaging findings with histopathological data enhances diagnostic accuracy and informs treatment planning. The significant differences in ADC values and T2 signal intensities between pure and mixed mucinous tumors highlight the potential of MRI as a non-invasive method for predicting tumor subtype. This capability is particularly relevant in cases where biopsy results are inconclusive or when non-invasive assessment is preferred.

Study Limitations

This study has certain limitations. The retrospective design and single-center setting may limit the generalizability of the findings. Additionally, the relatively small sample size restricts the statistical power of subgroup analyses. Future studies with larger, multicenter cohorts are warranted to validate these findings and explore the role of advanced imaging techniques, such as radiomics and machine learning, in the differentiation of mucinous breast carcinoma subtypes.

CONCLUSION

Multimodality imaging— particularly MRI with diffusion-weighted imaging and ADC measurements— provides valuable information for differentiating pure from mixed mucinous breast carcinoma. Although dynamic contrast-enhanced MRI parameters were not

discriminatory, morphological features, T2 signal intensity, and ADC values may complement histopathological evaluation, particularly in cases where biopsy findings may not fully represent tumor heterogeneity.

Ethics

Ethics Committee Approval: The study was conducted retrospectively at a single center following approval by the İstanbul Medeniyet University Göztepe Training and Research Hospital Clinical Research Ethics Committee (decision number 2023/0050) on January 25, 2023.

Informed Consent: Retrospective study.

Footnotes

Author Contributions

Surgical and Medical Practices: G.E., M.Y., F.Y., H.B., Concept: G.E., M.B.D., G.K., H.B., N.G., Design: G.E., M.Y., F.Y., G.K., N.G., Data Collection and/or Processing: G.E., M.B.D., M.Y., F.Y., H.B., Analysis or Interpretation: G.E., M.B.D., G.K., Literature Search: G.E., M.B.D., M.Y., G.K., N.G., Writing: G.E., M.B.D., M.Y., F.Y., G.K., H.B., N.G.

Conflict of interest: The authors declare that they have no conflict of interest.

Financial Disclosure: The authors declared that this study has received no financial support.

REFERENCES

1. Barkley CR, Ligibel JA, Wong JS, Lipsitz S, Smith BL, Golshan M. Mucinous breast carcinoma: a large contemporary series. Am J Surg. 2008;196:549-51.
2. Di Saverio S, Gutierrez J, Avisar E. A retrospective review with long term follow up of 11,400 cases of pure mucinous breast carcinoma. Breast Cancer Res Treat. 2008;111:541-7.
3. Kashiwagi S, Onoda N, Asano Y, et al. Clinical significance of the sub-classification of 71 cases mucinous breast carcinoma. Springerplus. 2013;2:481.
4. Fentiman IS, Millis RR, Smith P, Ellul JP, Lampejo O. Mucoid breast carcinomas: histology and prognosis. Br J Cancer. 1997;75:1061-5.
5. Chaudhry AR, El Khoury M, Gotra A, et al. Imaging features of pure and mixed forms of mucinous breast carcinoma with histopathological correlation. Br J Radiol. 2019;92:20180810.
6. Bitencourt AG, Graziano L, Osório CA, et al. MRI features of mucinous cancer of the breast: correlation with pathologic findings and other imaging methods. AJR Am J Roentgenol. 2016;206:238-46.
7. Zhou W, Li YZ, Gao LM, Cai DM. Sonographic features of pure mucinous breast carcinoma with micropapillary pattern. Front Oncol. 2021;11:644180. Erratum in: Front Oncol. 2021;11:822462.
8. Lam WW, Chu WC, Tse GM, Ma TK. Sonographic appearance of mucinous carcinoma of the breast. AJR Am J Roentgenol. 2004;182:1069-74.
9. Han HJ, Kim SH, Cha ES, et al. Imaging features of mucinous breast carcinoma. J Korean Soc Magn Reson Med. 2010;14:21-30.
10. Thai JN, Lerwill MF, Chou SS. Spectrum of mucin-containing lesions of the breast: multimodality imaging review with pathologic correlation. Radiographics. 2023;43:e230015.
11. Kuzmiak CM, Calhoun BC. Pure mucinous carcinoma of the breast: radiologic-pathologic correlation. J Breast Imaging. 2023;5:180-7.
12. Monzawa S, Yokokawa M, Sakuma T, et al. Mucinous carcinoma of the breast: MRI features of pure and mixed forms with histopathologic correlation. AJR Am J Roentgenol. 2009;192:W125-31.
13. Lee ACW, Wai JWC, Cheung OY, et al. Mucinous carcinoma of the breast: imaging features and pathological correlation. Hong Kong J Radiol. 2018;21:25-33.
14. Woodhams R, Kakita S, Hata H, et al. Diffusion-weighted imaging of mucinous carcinoma of the breast: evaluation of apparent diffusion coefficient and signal intensity in correlation with histologic findings. AJR Am J Roentgenol. 2009;193:260-6.
15. Zhang L, Jia N, Han L, Yang L, Xu W, Chen W. Comparative analysis of imaging and pathology features of mucinous carcinoma of the breast. Clin Breast Cancer. 2015;15:e147-54.
16. Bayoumi D, Sakrana A, Abdelhalim E, Alnaghy E. Role of multi-parametric MRI in the differentiation between mucinous breast carcinoma and fibroadenoma. Egypt J Radiol Nucl Med. 2021;52:260.