HISTOLOGICAL AND BIOCHEMICAL EFFECTS OF ENDOSULFAN AND MALATHION ON RAT TESTIS

Nazan Deniz Koç[1*], Figen Esin Kayhan[1], Nüzhet Cenk Sesal[1] and Gazi Contuk[2]

[1] Department of Biology, Faculty of Science and Art, University of Marmara, 34730 Göztepe-İstanbul, Turkey

[2] School of Medicine, University of Marmara, 34668 Haydarpaşa- İstanbul, Turkey

ABSTRACT

This study was conducted to assess the invivo effects of the endosulfan and malathion on the testis tissues of rats. Endosulfan and malathion are two of the most widely used insecticides throughout the world. During the study, combinations of low and high doses of endosulfan and malathion were administrated intraperitoneally to the male rats for 15 days. It is suggested that endosulfan and malathion have some histological and biochemical damages and toxic effects in testis tissues of rats.

KEYWORDS:
Endosulfan; malathion; rat; testis.

INTRODUCTION

In recent years, there have been growing concerns about the toxicity of a number of chemicals, including pesticides, on the male reproductive system. Such two pesticides are endosulfan and malathion, which are widely used in Turkey to maintain crop and food production, to fight against infesting pests and to safeguard humans from vector borne diseases and related epidemics. Endosulfan is an organochlorine insecticide. There are some major health concerns regarding this type of inscticides due to their prolonged persistence in the body. Endosulfan, however, has low residual persistence and hence had been preferred over other insecticides in this group [1, 2]. Endosulfan has been shown to reduce plasma FSH, LH and testosterone in rats and causes testicular damage [3,4]. The dose and duration of exposure to endosulfan are important determinants in its cellular and biochemical toxicity [3]. Malathion is an organophosphate compound and one of the most widely used organophosphate insecticides throughout the world. It is used to control pests affecting agricultural crops, ornamentals, greenhouses, livestock, stored garin, forests, buildings, households and gardens. Contributing to its popularity is its relatively low acute mammalian toxicity. In this study, combination of low and high doses of endosulfan and malathion were administrated intraperitoneally to the male rats for 15 days to investigate the histological and biochemical effects of endosulfan and malathion on testes of rats.

MATERIALS AND METHODS

Animals: Adult (n=25) wistar albino rats (150-200 g) were obtained from Marmara University, Center for Animal Breeding, Istanbul, Turkey. The rats were divided at random into four groups of 5 animals each. They were maintained under a well regulated light and dark (12h:12h) schedule at 24ºC±3ºC, and were allowed free access to laboratory chow and tap water. The experimental groups in present study were as follows: Control group (10 ml/day-rat physiological saline for Group I), low dose of endosulfan (30 ml/day-rat for Group II), high dose of endosulfan (50 ml/day-rat for Group III), low dose of malathion (30 ml/day-rat for Group IV) and high dose of malathion (50 ml/day-rat for Group V). The test groups were given intaperitoneally of endosulfan and malathion solutions and the control animals received physiological saline similar volume of the vehicle. Twenty-four hours after the last treatment, the rats were weighed and sacrified using ether anesthesia. Their testes were removed and cleaned immediately.

Testicular histopathology: The testes were fixed in Bouin's solution for 8 hours. Fixed tissues were dehydrated and embedded in parafin wax and sectioned transversely at 6-7 µm thickness and stained with hematoxylin eosin. The Periodic Acid Schiff Reaction (PAS) was applied. Samples were evaluated by examining under light microscope.

Malondialdehyde (MDA) assays: After decapitation, the testis tissue samples were immediately taken using appropriate techniques for biochemical examinations and stored in deep-freeze at -20ºC. Afterwards, MDA levels, an end product of lipid peroxidation, were measured in

these tissue samples. Tissue samples were homogenized ice-cold 150 mM KCl in a tissue homogenizer for determination of malondialdehyde levels. Results were expressed as nmol/g MDA tissue [5, 6]. These protocols were approved by the Animal Ethical Committee University of Marmara, Faculty of Medicine.

RESULTS

Histological effects: Testes from control groups (Group I) have shown normal histological structures (Figure a). Testes from low dose endosulfan treated group (Group-II) showed intercellular vacuolation, ondulation of seminiferous tubules wall and atrophy of seminiferous tubules (Figure b). The testes of rats from high dose endosulfan treated groups (Group-III) showed similar damage to those of group-II. Additionally, high dose endosulfan treated groups have showed desquamation of germinal cells (Figure c). Low dose malathion treated groups (Group-IV) showed accumulation of germinal cells in the seminiferous tubule lumen and degradation of the spermatogenic cells (Figure d). High dose dose malathion treated groups (Group-V) accumulated germinal cells in the seminiferous tubule lumen, intercellular vacuolation between sertoli cells and ondulation of the seminiferous tubule wall was observed (Figure e).

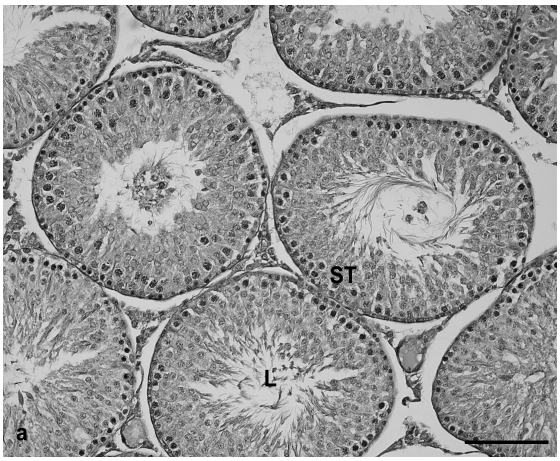

FIGURE a - Photomicrographs of sections of testes from control group (Group-I) of rats. (L) Lumen, (ST) Seminiferous Tubule. HE Stain Bar: 0,5µ

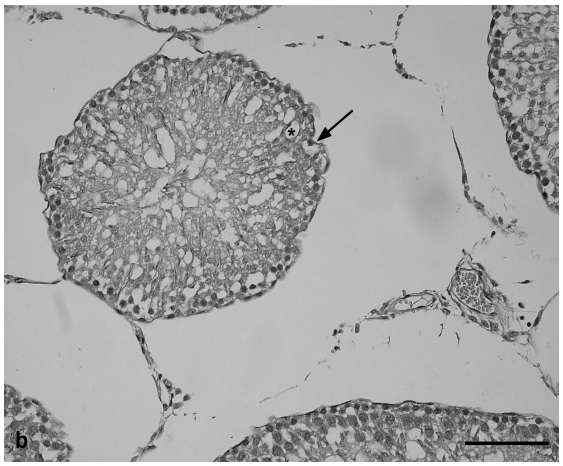

FIGURE b - Photomicrographs of sections of testes from Group-II. Ondulation of seminiferus tubule wall (→) and intercellular vacuolation (*) has showed. HE Stain Bar: 0,5µ

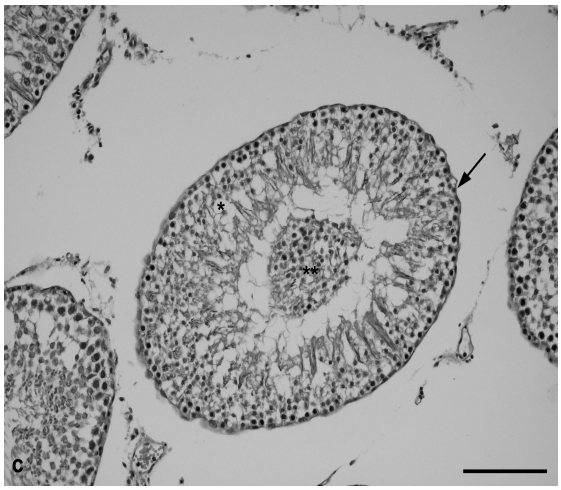

FIGURE c - Photomicrographs of sections of testes from group III. Ondulation of seminiferus tubule wall (→) and intercellular vacuolation and accumulation of germinal cells in the seminiferus tubule luman (**) due to esqumation of germinal cells has showed. HE Stain Bar: 0,5 µ

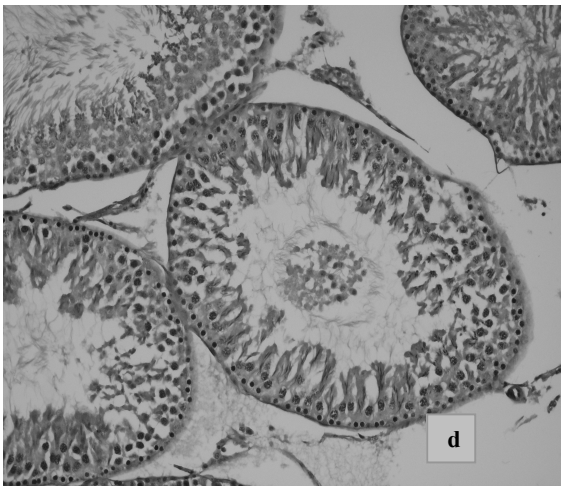

FIGURE d - Photomicrographs of sections of testes from Group IV. Accumulation of germinal cells in the seminiferous tubule lumen (*) and degeneration of the spermatogenic cells (→). HE Stain Bar: 0,5 µ

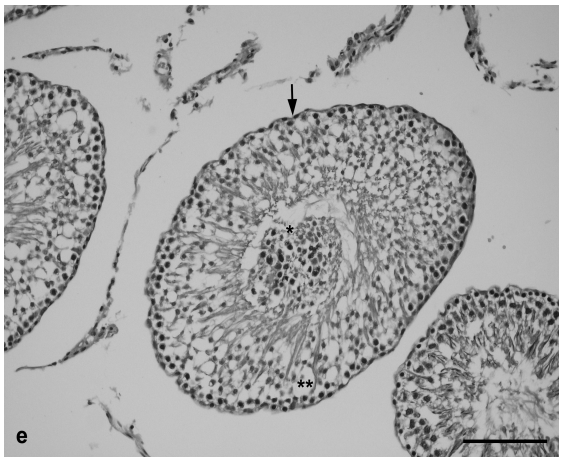

FIGURE e - Photomicrographs of sections of testes from Group-V. Accumulation of germinal cells in the seminiferous tubule lumen (*), intercellular vacuolation between sertoli cells (**) and ondulation of the seminiferous tubule wall (→) has showed. HE Stain Bar: 0,5 µ

Biochemical effects: The MDA levels of the testis tissues were found to be significantly higher for all groups in this study. The mean levels of MDA were found to be 60.23±1.5 nmol/g for endosulfan groups and 54.98±2.7 nmol/g for malathion groups in tissue analysis.

DISCUSSION AND CONCLUSIONS

There is experimental evidence of adverse effects of endosulfan on the male reproductive system which include a delay in sexual maturity and interference with the sex hormone synthesis. Long term health effects are not properly studied, experimented or documented world wide [2, 3]. Endosulfan was classified by the WHO in the category of technical products that are moderately hazardous [7]. In this study, it has been shown that endosulfan has estrogenic property and male rats are more sensitive to the chronic effect of endosulfan than female rats [1]. The microscopical changes were compared with the testes of normal rats. Light microscopy study demonstrates that the changes occurred mostly in seminiferous epithelium, intertubular space, spermatogonia, spermatocytes and spermatozoa. The major changes observed in the testis after endosulfan and malathion treatment of rats were fusion, invagination, distortion and disintegration of seminiferous tubules, autolysis of cells, arrest of spermatid formation and of spermatogenesis and decrease in the number of interstitial cells. Damage to the seminiferous tubules was found in almost all the testes of malathion and endosulfan treated rats.

Interstitial oedema, congestion and also desquamation of the lining cells of the seminiferous tubules was noted. Leydig cells were conspicuously absent. At day 15, detachment of spermatocytes and spermatids became evident, with apparent radial cracks being formed between the germ cells. When spermatocytes and spermatids were detached from the seminiferous epithelium in proportions, it was observed that key spermatogenic lesions also included impairment in meiosis (development of spermatids from spermatocytes) and spermiogenesis (transformation of elongated spermatids from round spermatids), as indicated by significantly smaller numerical ratios between round spermatids and spermatocytes and between elongating spermatids and round spermatids. Degeneration (pyknotic nuclei) or apoptosis of spermatocytes and spermatids were observed in the current study and previous studies [8, 9].

There were also indications of impairment in meiosis and spermiogenesis. According to Pant and Srivastava [10], carbaryl effected sperm morphology. The sperm tail, but not the head morphology, was affected by malathion and endosulfan, which was inconsistant with the results of Giri et al. [11]. The sperm tail morphology could be affected by a number of mutagenic agents [12]. Malathion and endosulfan interfere with rat testicular function, being toxic both to the somatic (Leydig and Sertoli) and spermatogenic cells (mainly spermatogonia and maturing spermatids). Malathion caused testicular histology and ultrastructural alterations in the germinal epithelium and had a teratogenic effect on mice spermatid differentiation. Endosulfan caused autolysis of cells, arrest of spermatid formation and of spermatogenesis loss of spermatozoan tail and a decrease in number of interstitial cells in testes of mice [13].

According to Pant and Srivastava [10], testicular and spermatotoxic effects were seen when quinalpho was applied. Quinalphos caused a decrease in sperm mortality and damage to germ cells and Sertoli cells. It is concluded that this pesticides, caused irreversible or partly reversible damage, affecting adversely the testicular functions of wistar albino rats. Doses of pesticides elicit a toxic effect on germinal and somatic cells of the testis [14]. There is a depletion of the population of renewing spermatogonia, followed by spermatogonial proliferation. The damage of Sertoli and Leydig cells adds an additional compromise of spermatogenesis, in view of the close interrelationship of somatic and germ cells in the testis.

In summary, although the available reproductive studies indicate that endosulfan has no adverse effects on male reproductive organs, there have been effects in young rats and mice. The lack of effects seen in the studies that examined the reproductive performance in treated males and

females seems difficult to explain, given the findings of altered spermatogenesis in the more recent studies. This study suggests that endosulfan and malathion have some toxic effects in testis tissues of rats. The increase in MDA levels in rat liver and kidney tissues due to endosulfan may be an indicator of the occurrence of free radicals in the metabolism and their lipid peroxidatives inducing damage.

ACKNOWLEDGEMENTS

This research was supported by University of Marmara, Scientific Research Found (BAPKO), Project no: FEN-BGS-290906-0211.

REFERENCES

[1] Chitra, K.C., Latchoumycandane, C. and Mathur, P.P. (1999) Chronic effects of endosulfan on the testicular functions of rat. Asian J Androl, 1(4),203-206.

[2] Sinha, P., Verma, P., Kumar, A. and Nath A. (2004) Testicular atrophy in mice (*Mus musculus*) under sublethal doses of endosulfan. Journal of Ecophysiology and Occupational Health, 4(3-4),191-196.

[3] Singh, S.K. and Pandey, R.S. (1989) Gonadal toxicity of short term chronic endosulfan exposure to male rats. Indian J Exp Biol, 27(4),341-346.

[4] Srivastava, S.C. and Gupta, P.K. (1980) Effects of endosulfan on male reproductive organs in rats. Indian J Biochem Biophys, 17,102-103.

[5] Beuge, J.A. and Aust, S.D. (1978) Microsomal lipid peroxidation. Methods Enzymol, 52,302-311.

[6] Draper, H.H. and Hadley, M. (1990) Malondialdehyde determination as index of lipid peroxidation. Methods Enzymol, 186,421-430.

[7] FAO/WHO (1993) International Programme on Chemical Safety (IPSC). Summary of Toxicological Evaluations Performed by the Joint FAO/WHO Meeting on Pesticide Residues (JPMR). JHO, Geneva, Switzerland.

[8] Valenzuela, A. (1990) The biological significance of MDA determination in the assesment of tissue oxidative stres. Life Sci, 48,301-309.

[9] Sharpe, R.M. (1994) Regulation of spermatogenesis. In: Knobil E, Neill JD, editors. The Physiology of Reproduction, vol.1. Raven Press, New York, 1363-1364.

[10] Pant, N. and Srivastava, S.P. (2003) Testicular and spermatotoxic effects of quinalphos in rats. J Appl Toxicol, 23(49), 271-274.

[11] Wyrobek, A.J. and Bruce, W.R. (1975) Chemical induction of sperm abnormalities in mice. Proc Natl Acad Sci USA. 72, 4425-4429.

[12] Kerr, J.B., Millar, M., Maddocks, S. and Sharpe R.M. (1993) Stage-dependent changes in spermatogenesis and sertoli cells in relation to the onset of spermatogenic failure following withdrawal of testosterone. Anat Rec, 235, 547-59.

[13] Contreras, H.R. and Bustos-Obregon, E. (1999) Morphological alterations in mouse testis by a single dose of malathion. J Exp Zool, 284(3), 355-359.

[14] Giri, S., Prasad, S.B., Giri, A. and Sharma, G.D. (2002) Genotoxic effects of malathion: an OPs using three mammalian bioassays in vivo. Mutat Res, 514,223-31.

Received: September 21, 2007
Revised: February 19, 2008
Accepted: April 01, 2008

CORRESPONDING AUTHOR

Nazan Deniz Koç
University of Marmara
Department of Biology
Faculty of Science and Art
34730 Göztepe-İstanbul
TURKEY

Phone: ++902163487759
Fax: ++902163478783
E-mail: ndy31@hotmail.com

FEB/ Vol 17/ No 12b/ 2008 – pages 2262 - 2265

SUBJECT INDEX

A

accumulation 2207
adsorbability 2175
Anise essential oil 2170
antigenotoxic 2180
antigenotoxic 2187
antioxidant activity 2146
AVHRR 2152

B

Black Sea 2159
bloom-forming cyanobacterium 2146
brown-tail moth 2170

C

Calabrian pine 2226
case-2 waters 2152
chlorophyll a 2180
chlorophyll b 2180
Chlorophyllin 2187
coastal zone 2152
controlled release 2250
crown fire 2226
crown fuel biomass 2226
crown fuel characteristics 2226

D

disturbance 2175
Drosophila melanogaster 2180
Drosophila melanogaster 2187

E

earthworms 2200
endosulfan 2262
Engraulis encrasicolus 2159
enrichment factors 2232
estuary 2207
Euproctis chrysorrhoea 2170
eutrophication 2193

F

filamentous bacteria 2255
fluorescence in situ hybridization (FISH) 2255

G

geographical information system 2217
geographical information system 2240

I

ICP-MS 2232
integrated coastal zone management 2217
integrated coastal zone management 2240
interoperability 2240

L

larvicidal activity 2170

M

malathion 2262
marine aquaculture 2217
marine optical properties 2152
marine spatial data infrastructure 2240
Mediterranean Sea 2207
membrane bioreactor (MBR) 2255
metals 2207
metals 2232
montmorillonite 2250
mortality 2159
multi-cell device 2146
multicriteria evaluation 2217

N

nitrification 2255
nitrogen removal 2255
norflurazon 2250
nutrients 2193

O

overwintering 2146

P

pesticide contaminated soil 2200
phenyltrimethylamonium 2250
physiological response 2146
phytoplankton 2193
pillared clay 2250
Pimpinella anisum 2170
population 2159

R

rainwater 2232
rat 2262
regression models 2226
remote sensing 2152

S

salinity 2207
Sarda sarda 2159
seaweed 2207
sediment environments 2146
sedimentation 2175
site selection 2217
SMART 2180
SMART 2187
submerged macrophyte 2175
suspended solids 2175

T

Tâmega River 2193
testis 2262
toxicity tests 2200
trans-anethole 2170
Turkey 2226